

Original Article

Minimally invasive bunionette treatment: clinical and radiographic results

Alexander Felipe de Vete Lima¹ , Tiago Soares Baumfeld² , Bruno Maciel Braga³ , Daniel Soares Baumfeld² , Guillaume Cordier^{4,5} , Gustavo Araújo Nunes^{4,6} 

1. Hospital Universitário Ciências Médicas (FCMMG), Belo Horizonte, MG, Brazil.

2. Universidade Federal de Minas Gerais (UFMG), Belo Horizonte, MG, Brazil.

3. Hospital São José, Conselheiro Lafaiete, MG, Brazil.

4. Gremp MIFAS (Group of Research and Study in Minimally Invasive Surgery of the Foot – Minimally Invasive Foot and Ankle Society), Belo Horizonte, MG, Brazil.

5. Clinique du Sport Bordeaux, Merignac, France.

6. Instituto Orizonti, Belo Horizonte, MG, Brazil.

Abstract

Objective: To report the clinical and radiographic results of surgical treatment of bunionette deformity with a minimally invasive technique without the use of hardware.

Methods: This is a case series of 13 patients (14 feet) with a diagnosis of bunionette surgically treated with a minimally invasive osteotomy of the fifth metatarsal. All patients completed the American Orthopedic Foot and Ankle Society (AOFAS) score and a visual analog scale (VAS) for pain preoperatively and in the last follow-up visit. Radiographic measurements included the fourth-fifth intermetatarsal angle (4-5 IMA) and the fifth metatarsophalangeal (MTP-5) angle. Complications and level of patient satisfaction were also documented.

Results: Mean follow-up was 12.3 months. The mean AOFAS score increased from 51.3 to 94.0, and the VAS score decrease from 7.5 to 1.1. The MTP-5 angle decreased from 11.5° to 2.3°, and the 4-5 IMA decreased from 9.8° to 3.6°. These outcomes showed a statistically significant difference ($p < 0.001$). The only complication was hypertrophic callus formation observed in 3 feet (21.4%). There were no cases of infection, neuropaxia, wound dehiscence, nonunion, or deformity recurrence. Ten patients rated their outcome as excellent and 3 as good.

Conclusion: Treatment of bunionette with percutaneous osteotomy of the fifth metatarsal without the use of hardware showed good clinical and radiographic results, with a low complication rate and a high level of patient satisfaction.

Level of Evidence IV; Therapeutic Studies; Case Series.

Keywords: Bunion, Tailor's; Minimally invasive surgical procedures/methods; Metatarsal bones/surgery; Forefoot, Human/surgery; Treatment outcome.

Introduction

Tailor's bunion or bunionette is a deformity of the fifth metatarsal head characterized by a bony prominence on the lateral, dorsolateral, or plantar aspect of this bone. The etiology is multifactorial and includes anatomic and biomechanical factors⁽¹⁾. Du Vries and Coughlin classified the anatomic variations of this deformity into 3 types. In type 1 (16-33%) there is an increase in size of the lateral fifth metatarsal head condyle, in type 2 (10%) there is a lateral deviation at

the metadiaphyseal junction, and in type 3 (57-74%) there is an increased intermetatarsal angle between the fourth and fifth metatarsals^(2,3).

Bunionette deformity typically presents with pain in the lateral and/or plantar region associated with callus formation and difficulty wearing closed toe shoes. Clinical examination clearly shows an increased intermetatarsal angle with abduction of the fifth metatarsal and a varus fifth toe. Initial treatment is generally conservative and consists of orthopedic

Study performed at the Hospital Belo Horizonte, Belo Horizonte, MG, Brazil.

Correspondence: Gustavo Araújo Nunes. 111 Prof. Otavio Coelho de Magalhães St., Mangabeiras, Belo Horizonte, MG, Brazil, Zip Code: 30210-300

E-mail: gustavoanunes@hotmail.com

Conflicts of interest: Daniel Soares Baumfeld is a consultant and speaker for Arthrex (USA) and Geistlich Pharma (Switzerland). The others authors disclaimed that there is no conflicts of interest. **Source of funding:** own. **Date received:** April 04, 2020. **Date accepted:** June 17, 2020. **Online:** August 30, 2020.

How to cite this article: Lima AFV, Baumfeld TS, Braga BM, Baumfeld DS, Cordier G, Nunes GA. Minimally invasive bunionette treatment: clinical and radiographic results. *J Foot Ankle.* 2020;14(2):148-52.



shoes, insoles, and symptomatic medication⁽⁴⁾. If this approach fails, surgical intervention is indicated^(1,5).

Surgical options to treat bunionette include chevron osteotomy, Sponkel's osteotomy, and lateral condylar resection, among others^(3,6,7). Some complications associated with these procedures are soft-tissue irritation, infection, and hardware-related problems^(8,9). The description by De Prado of a low invasive technique without the use of hardware boosted the minimally invasive approaches for the treatment of fifth metatarsal deformity^(10,11).

The objective of this study was to report the clinical and radiographic results of surgical treatment of bunionette deformity with a minimally invasive technique initially described by De Prado without the use of hardware.

Methods

This study was approved by the Institutional Review Board and registered on the Plataforma Brazil database under CAAE (Ethics Evaluation Submission Certificate) number: 12744119.0.0000.5122 and written informed consent was obtained from each study participant.

We retrospectively assessed patients with a diagnosis of bunionette who were surgically treated with a minimally invasive osteotomy of the fifth metatarsal from March 2018 to August 2019. Eligible participants were all patients with a diagnosis of bunionette who did not improve with conservative treatment consisting of shoe modification and symptomatic medication use. Patients undergoing other concomitant surgical procedures were not included. Exclusion criteria were a previous history of surgery/deformity of the hindfoot and midfoot and rheumatological, neurological, or vascular diseases.

Preoperative evaluation included the application of the American Orthopedic Foot and Ankle Society (AOFAS) score⁽¹²⁾ and a visual analog scale (VAS) for pain in all patients. Complementary preoperative studies included anteroposterior

(AP) and lateral non-weight-bearing radiographs. The fifth metatarsophalangeal (MTP-5) angle and fourth-fifth intermetatarsal angle (4-5 IMA) were measured⁽¹³⁾.

In the last follow-up visit, patients again completed the AOFAS and VAS and a second radiographic examination was performed. Presence of radiographic union (determined by bridging bone spanning 3 or more cortices on orthogonal radiographs), complications, and level of patient satisfaction based on Coughlin's classification (excellent, good, fair, poor, very poor) were also documented⁽¹⁴⁾.

Statistical analysis was performed using GRETL software (2017c). Student's *t* test was used to compare pre-intervention and post-intervention measurements. A p-value <0.05 was considered significant.

Surgical technique

The procedure was performed with the patient lying supine with the legs hanging off the table and feet resting on the image intensifier tube. No tourniquet was used. A 3-mm incision was made on the dorsal aspect of the fifth metatarsal and lateral to the extensor tendon of the fifth toe. The soft tissues were dissected by carefully scraping them off, thus creating a safe working space for osteotomy.

In most cases, osteotomy was performed in the distal third of the metatarsal. Only in type 2 bunionette, osteotomy was performed at the apex of the curvature of the deformity. A 2×12mm Shannon burr was positioned approximately 45° to the fifth metatarsal sagittal axis to obtain an oblique osteotomy from dorsal distal to plantar proximal.

The osteotomy was performed by moving the burr from lateral to medial. During osteotomy, with the non-dominant hand, the surgeon applied external manual pressure to the distal fragment in a medial direction. After completion of osteotomy, the distal part of the fifth metatarsal migrated medially with correction of the deformity (Figure 1).

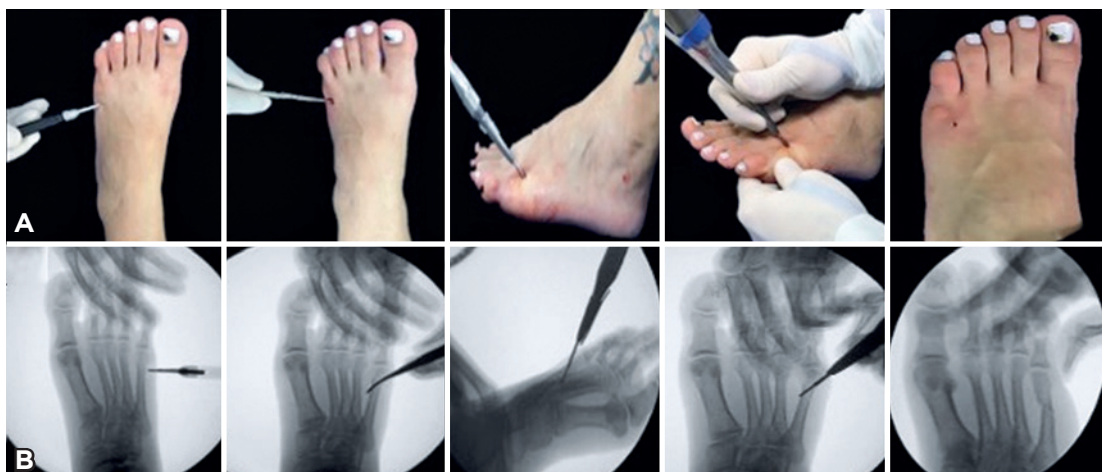

Figure 1. Intraoperative sequence of the surgical technique; A) Clinical image; B) Radiographic image.

Finally, a gauze-and-tape dressing and compression bandage were applied to maintain the correction achieved.

Postoperative period

In the first postoperative week, patients were instructed to keep the lower limb elevated during rest to alleviate postoperative edema. Immediate full weight-bearing wearing a rigid flat-bottom orthopedic shoe was allowed.

The dressing was changed on a weekly basis for 4 weeks, when there is fibrous union and a certain degree of stability at the osteotomy site. After 4 weeks, the dressings were replaced with silicone strips and patients were allowed to ambulate in a rigid-soled shoe with a wide toe box.

Radiographs were obtained at 2 and 6 weeks postoperatively, and at 3, 6, and 12 months postoperatively (Figure 2).

Results

A total of 13 patients (14 feet) with a diagnosis of bunionette were evaluated in this study. All were women, with a mean age of 42.7 years (range, 26 to 60 years). One patient underwent bilateral treatment in the same surgical procedure. Mean follow-up was 12.3 months (range, 8 to 14 months).

The mean AOFAS score increased from 51.3 to 94.0, and the VAS score decreased from 7.5 to 1.1. The MTP-5 angle decreased from 11.5° to 2.3°, with a mean improvement of 9.2°. The 4-5 IMA decreased from 9.8° to 3.6°, with a mean improvement of 6.2°. All parameters showed improvements of statistical significance ($p < 0.001$). The data of the study participants and their individual results are shown in table 1.

The only complication was hypertrophic callus formation observed in 3 feet (21.4%). In the last follow-up visit, these patients reported complication resolution, and radiographs showed bone remodeling of the hypertrophic callus. There

were no cases of infection, neurapraxia, wound dehiscence, or deformity recurrence. No delayed unions, nonunions, or malunions were observed. All patients returned to their usual activities with no shoe restrictions. Ten patients rated their overall subjective satisfaction as excellent and 3 as good.

Discussion

This study presented the clinical and radiographic outcomes of a series of patients with bunionette surgically treated with a minimally invasive osteotomy without the use of hardware. An important radiographic correction was demonstrated with improvement of the MTP-5 angle and 4-5 IMA and a favorable clinical outcome with significant improvement in pain, as assessed by VAS, AOFAS, and satisfaction rate. The main complication was hypertrophic callus formation, which improved during follow-up. No serious complications occurred, and there was no need to reopen the osteotomy.

Some authors have already demonstrated the efficacy of the surgical treatment of this deformity using the same minimally invasive technique described in the present study. Michels et al.⁽¹⁵⁾ published a case series in which the 20 operated patients had an improvement in mean AOFAS score from 54.4 to 96.5, and a mean correction of 14.2° for MTP-5 angle and 5.7° for 4-5 IMA. Laffenêtre et al.⁽¹⁶⁾ retrospectively evaluated 49 operated feet and reported an improvement in mean AOFAS score from 58 to 97, and a mean correction of 12° for MTP-5 angle and 4.4° for 4-5 IMA. The present study showed similar clinical and radiographic results, with a final AOFAS score of 94 and a mean improvement of 9.2° for MTP-5 angle and 6.2° for 4-5 IMA.

The minimally invasive technique used in the present study stands out as an effective approach because, via percutaneous access without the use of hardware, it produces radiographic results comparable to those of open techniques⁽¹⁷⁾. Surgical wound infection and local hardware irritation are the most commonly described complications in open techniques and in techniques that use hardware for fixation of the osteotomy^(4,11). The results of the present study reinforce this advantage, since there were no cases of infection, wound dehiscence, or need for surgical reintervention. Heckman et al.⁽¹⁸⁾ evaluated 63 patients treated with distal osteotomy of the fifth metatarsal using an open technique and reported an infection rate of 9.5%, of which 50% required surgical reintervention with resection of the metatarsal head. Recently, Necas et al.⁽¹⁹⁾ retrospectively evaluated 34 feet with bunionette treated with a scarf osteotomy using an open technique and fixation with screws and reported complications in 5 cases (14.7%). Although within acceptable limits, surgical reintervention was required in 3 of these cases (8.8%) due to postoperative infection, transfer metatarsalgia, and hardware migration⁽¹⁹⁾.

A challenge posed by unfixed osteotomies used to treat fifth metatarsal deformity is the risk of developing transfer metatarsalgia. Although unfixed osteotomy offers the advantage of no hardware, dorsal migration of the distal fragment can occur, and the load can be transferred medially. Kea-

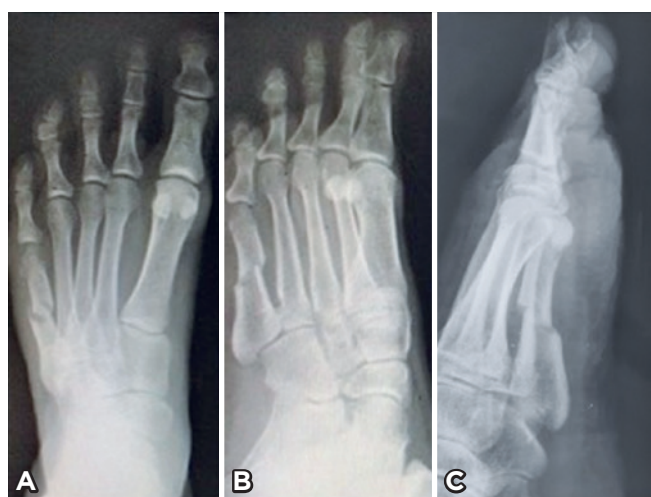

Figure 2. Radiograph obtained at postoperative week 6. A) Anteroposterior view. B) Oblique view. C) Lateral view, highlighting the obliquity of osteotomy and contact between fragments.

Table 1. Study patient data and individual results

Foot No.	Age	Sex	Side	Type*	MTP-5 angle		4-5 IMA		AOFAS		VAS	
					Preop	Postop	Preop	Postop	Preop	Postop	Preop	Postop
1	54	F	R	3	16	6	12	6	50	95	8	2
2	60	F	L	3	12	2.5	12	6.5	40	95	9	0
3	55	F	R	3	16	2	10.5	5	53	95	9	0
4	33	F	R	3	8	2.5	10	4	53	95	6	1
5	40	F	L	3	10	2	11.5	4	53	95	6	1
6	52	F	R	2	14	4	5	2	63	95	5	0
7	33	F	R	3	8	2	12	6	49	95	8	2
8	40	F	L	3	8	0	10	3.5	53	95	7	2
9	26	F	R	3	12.5	3	13	4.5	35	93	10	3
10	26	F	L	3	12	4	9	1	40	93	8	2
11	43	F	L	3	12.5	3.5	8	2.5	62	95	5	0
12	35	F	L	2	15	3	9	2	40	95	10	0
13	60	F	L	2	8	-1	9	1.5	58	95	9	0
14	42	F	L	1	9	0	7.5	2.5	70	85	5	3

*Deformity type as classified by Du Vries and Coughlin.

ting et al.⁽²⁰⁾, evaluating bunionette deformities treated with Sponse's osteotomy using an open technique, with a straight incision on the sagittal axis and an oblique incision on the axial axis, without internal fixation, showed a high rate of transfer metatarsalgia (76%). In the present series, although no internal fixation was used, there were no cases of transfer metatarsalgia. We believe that the absence of this complication resulted from a technical detail of the osteotomy described in this study, which is performed with an oblique incision on the sagittal plane at 45° from dorsal distal to plantar proximal. This configuration helps to maintain contact between the distal and proximal fragments on the sagittal axis, preventing the distal fragment from moving dorsally and, consequently, avoiding excess load transfer to the neighboring metatarsals (Figure 2C).

The osteotomy described in the present study is associated with some complications, but the main one is hypertrophic callus formation during the healing process. Several authors treating this deformity with a percutaneous technique without fixation have reported this complication^(15,16,21,22). In the series published by Laffenêtre et al.⁽¹⁶⁾, 7 patients had hypertrophic callus formation, and the authors related this type of complication to cases operated bilaterally. In the present case series, the only complication was hypertrophic callus formation, which occurred in 3 feet (21.4%), with 1 case occurring in a patient operated bilaterally. During follow-up,


there was callus remodeling and symptom improvement; however, this process is slow and may delay the return of patients to their usual activities and reduce their satisfaction with the treatment. This probably occurs due to residual instability of these unfixed osteotomies associated with early weight-bearing on the operated limb, which is more evident in patients treated bilaterally.

This study has a strength that deserves to be highlighted. Patients in this series underwent bunionette correction alone, without any additional procedure. This makes the assessment of bunionette treatment more reliable than that of most series reported in the literature, which evaluated the results of this technique in patients undergoing concomitant hallux valgus correction and other metatarsophalangeal osteotomies.

Limitations of this study include the small sample size, short follow-up, and lack of a control group. Comparative studies with higher scientific level and a larger number of participants are necessary to confirm the observed findings.

Conclusion

Treatment of bunionette with percutaneous osteotomy of the fifth metatarsal without the use of hardware showed good clinical and radiographic results, with a low complication rate and a high level of patient satisfaction.

Authors' contributions: Each author contributed individually and significantly to the development of this article: AFVL *(<https://orcid.org/0000-0001-8897-232x>) conceived and planned the activities that led to the study, interpreted the results of the study, wrote the article and participated in the review process; TSB *(<https://orcid.org/0000-0001-9244-5194>) conceived and planned the activities that led to the study, interpreted the results of the study, and approved the final version; BMB *(<https://orcid.org/0000-0003-3712-1247>) conceived and planned the activities that led to the study, interpreted the results of the study and approved the final version; DSB *(<https://orcid.org/0000-0001-5404-2132>) conceived and planned the activities that led to the study, interpreted the results of the study and approved the final version; GC *(<https://orcid.org/0000-0002-7035-3931>) conceived and planned the activities that led to the study, interpreted the results of the study and approved the final version; GAN *(<https://orcid.org/0000-0003-4431-5576>) conceived and planned the activities that led to the study, interpreted the results of the study and approved the final version. *ORCID (Open Researcher and Contributor ID) 

References

1. Morawe G, Schmieschek M. Minimally invasive bunionette correction. *Oper Orthop Traumatol*. 2018;30(3):184-94.
2. Glover J, Weil L, Weil L. Scarfette osteotomy for surgical treatment of bunionette deformity. *Foot Ankle Spec*. 2009;2(2):73-8.
3. Roukis T. The Tailor's bunionette deformity: a field guide to surgical correction. *Clin Podiatr Med Surg*. 2005;22(2):223-45.
4. Shi GG, Humayun A, Whalen JL, Kitaoka HB. Management of bunionette deformity. *J Am Acad Orthop Surg*. 2018;26(19):e396-e404.
5. Martinelli B, Valentini R. Correction of valgus of fifth metatarsal and varus of the fifth toes by percutaneous distal osteotomy. *Foot Ankle Surg*. 2007;13(3):136-9.
6. Weitzel S, Trnka H, Petroutsas J. Transverse medial slide osteotomy for bunionette deformity: long-term results. *Foot Ankle Int*. 2007;28(7):794-8.
7. Koti M, Maffulli N. Bunionette. *J Bone and Joint Surg Am*. 2001;83(7):1076-82.
8. Frankel JP, Turf RM, King BA. Tailor's bunion: clinical evaluation and correction by distal osteotomy with cortical screw fixation. *J Foot Surg*. 1989;28(2):237-43.
9. Martijn HA, Sierevelt IN, Wassink S, Nolte PA. Fifth metatarsal osteotomies for treatment of bunionette deformity: a meta-analysis of angle correction and clinical condition. *J Foot Ankle Surg*. 2018;57(1):140-8.
10. De Prado M, Ripoll PL, Golano P. Cirugía percutánea del pie. *Técnicas quirúrgicas, indicaciones, bases anatómicas*, 1st ed., Barcelona: Masson Elsevier; 2003. p. 129-48.
11. Ceccarini P, Rinonapoli G, Nardi A, Bisaccia M, Di Giacomo L, Caraffa A. Bunionette. *Foot Ankle Spec*. 2016;10(2):157-61.
12. Kitaoka H, Alexander I, Adelaar R, Nunley J, Myerson M, Sanders M. Clinical rating systems for the ankle-hindfoot, midfoot, hallux, and lesser toes. *Foot Ankle Int*. 1994;15(7):349-53.
13. Saltzman C, Brandser E, Berbaum K, DeGnore L, Holmes J, Katcherian D, et al. Reliability of standard foot radiographic measurements. *Foot Ankle Int*. 1994;15(12):661-5.
14. Coughlin M. Treatment of bunionette deformity with longitudinal diaphyseal osteotomy with distal soft tissue repair. *Foot Ankle*. 1991;11(4):195-203.
15. Michels F, Van Der Bauwhede J, Guillo S, Oosterlinck D, de Lavigne C. Percutaneous bunionette correction. *Foot Ankle Surg*. 2013;19(1):9-14.
16. Laffenêtre O, Millet-Barbé B, Darcel V, Lucas y Hernandez J, Chauveaux D. Percutaneous bunionette correction: Results of a 49-case retrospective study at a mean 34 months' follow-up. *Orthop Traumatol Surg Res*. 2015;101(2):179-84.
17. Lui T. Percutaneous osteotomy of the fifth metatarsal for symptomatic bunionette. *J Foot Ankle Surg*. 2014;53(6):747-52.
18. Heckman J, Harkless L, Wirth M, Higgins K. The Spones oblique fifth metatarsal osteotomy: evaluation with long-term follow-up. *Foot*. 1991;1(1):37-44.
19. Necas L, Hrubina M, Skotak M, Melisik M, Lisy P, Cibula Z. Bunionette deformity corrected with "shortening" scarf osteotomy of the fifth metatarsal: mid-term results of a 34-cases. *Foot Ankle Surg*. 2019 Jun 19;S1268-7731(18)30348-5.
20. Keating SE, DeVincentis A, Goller WL. Oblique fifth metatarsal osteotomy: a follow-up study. *J. Foot Surg*. 1982;21(2):104-7.
21. Del Vecchio J, Ghioldi M, Dalmau-Pastor M, Uzair A, Chemes L. Sliding distal metatarsal minimally invasive osteotomy (S-DMMO) for the treatment of Tailor's bunion. *Tech Foot Ankle Surg*. 2019;18(1):37-42.
22. Teoh K, Hariharan K. Minimally invasive distal metatarsal metaphyseal osteotomy (DMMO) of the fifth metatarsal for bunionette correction. *Foot Ankle Int*. 2018;39(4):450-7.