

Original Article

Clinical and radiological outcomes of the first metatarsophalangeal arthrodesis with Kirschner wires for the treatment of severe hallux valgus

Luiza Horta Barbosa¹, José Antônio Veiga Sanhudo^{1,2}

1. Hospital de Clínicas de Porto Alegre, Porto Alegre, RS, Brazil.

2. Hospital Moinhos de Vento, Porto Alegre, RS, Brazil.

Abstract

Objective: To present the clinical and radiographic outcomes of metatarsophalangeal arthrodesis of the hallux with crossed Kirschner wires and cerclage for the treatment of severe hallux valgus.

Methods: Twenty-nine feet of 21 consecutive patients who underwent metatarsophalangeal arthrodesis to correct severe hallux valgus between March 2011 and April 2018 were clinically and radiographically evaluated.

Results: After an average follow-up period of 42 months, 17 feet (58.6%) generated a response of total satisfaction with the procedure and 12 (41.4%) a response of satisfied with reservations; none of the patients were dissatisfied. Pain assessed using the visual analog scale improved from a mean of 8 before the procedure to 1.2 at follow-up. The American Orthopaedic Foot and Ankle Society score improved from a mean of 26.5 points before the procedure to 78 points at follow-up. The hallux valgus angle improved from a mean of 38.5° in the preoperative period to 13.1° at follow-up, i.e., an improvement of 25.4°. The intermetatarsal angle improved from a mean of 18.8° in the preoperative period to 15° at follow-up. Consolidation of arthrodesis occurred in all cases, but reintervention was required to remove the hardware in 17 operated feet (58.6%).

Conclusion: Metatarsophalangeal arthrodesis with crossed Kirschner wires and cerclage for the treatment of severe hallux valgus produced high rates of satisfaction, with substantial improvement in pain and functional parameters, consolidation in all cases and excellent radiological correction, but had the drawback high rate of reintervention for hardware removal.

Level of Evidence IV; Therapeutic Study; Case Series.

Keywords: Metatarsophalangeal joint; Arthrodesis; Hallux valgus.

Introduction

Hallux valgus is the most common deformity of the adult foot, affecting up to 30% of the urban population. It is also a frequent cause of painful symptoms, difficulty wearing closed in shoes, and aesthetic dissatisfaction. Factors associated with development of the deformity include genetic predisposition (family history) and use of closed in shoes, especially high heels and shoes with pointed toes, which alter the biomechanics of gait and areas of pressure on the foot, contributing to the onset and progression of the deformity⁽¹⁻⁴⁾.

Although many people live with the disorder without complaints or the need for treatment, a high percentage develops painful symptoms, functional and/or aesthetic complaints, which motivates the search for an orthopedist with the intention of correcting the deformity.

The most appropriate treatment remains controversial, especially when dealing with severe deformities. More than 100 surgical techniques are described for the correction of hallux valgus, each with its specific indications, limitations, advantages and disadvantages. First ray realignment osteotomies

Study performed at the Hospital Moinhos de Vento, Porto Alegre, RS, Brazil.

Correspondence: Luiza Horta Barbosa. 2350 Ramiro Barcelos St., Porto Alegre, RS, Brazil, Zip Code: 90035-007. **E-mail:** luizahortabarbosa@gmail.com

Date received: March 25, 2020. **Date accepted:** March 27, 2020. **Online:** April 30, 2020.

How to cite this article: Barbosa LH, Sanhudo JAV. Clinical and radiological outcomes of the first metatarsophalangeal arthrodesis with Kirschner wires for the treatment of severe hallux valgus. *J Foot Ankle.* 2020;14(1):24-8.



are the most commonly used procedures at present, but the chances of recurrence or residual pain due to osteoarthritis secondary to deformity are disappointing and relatively frequent complications⁽⁵⁻⁷⁾.

Osteotomies for hallux valgus correction are performed mainly at the level of the first metatarsal, in the distal, diaphyseal or proximal region, depending on the degree of deformity. Distal osteotomies are traditionally reserved for minor deformities due to their lower angle correction capacity. In major deformities, surgeons opt for a diaphyseal or proximal osteotomy, which are relatively major procedures that require a more robust internal fixation, often increasing morbidity and the cost involved in the surgery.

Metatarsophalangeal arthrodesis is a treatment that has the ability to correct severe deformities and produces high percentages of good results, besides eliminating any residual pain due to osteoarthritis secondary to deformity, a complication that, as already mentioned, occurs quite often after osteotomies⁽⁷⁻¹³⁾. Hallux valgus represents, in the vast majority of cases, a metatarsophalangeal subluxation with varying degrees of joint incongruity. In the long term, this biomechanical alteration causes asymmetric wear and tear of the metatarsophalangeal joint surface, which can become or remain symptomatic after a first ray osteotomy for realignment⁽¹³⁾.

Successful arthrodesis eliminates the risk of secondary osteoarthritis in the MTPJ (metatarsophalangeal joint), but has the drawback of eliminating mobility in this joint and limiting the use of some shoes, especially high heels. This postoperative limitation, however, does not usually represent a problem for patients who had been experiencing pain and having difficulty wearing dress shoes due to the deformity. Another disadvantage of arthrodesis is the cost of the procedure, since most techniques involve fixation methods that use sophisticated implants, such as locked plate and screws, with the main objective of increasing the stability of the fixation and reducing the chances of nonunion⁽¹⁴⁻²⁰⁾. Pre-molded implants are being developed with the objective of reducing surgical time, since they eliminate the need for intraoperative molding, reduce the occurrence of nonunion and the need for reintervention to remove them, as they adapt to the regional anatomy with much more precision. These implants, however, are available in few treatment centers and cost much more than traditional implants⁽¹⁷⁻²⁰⁾.

This study presents the clinical and radiological outcomes of metatarsophalangeal arthrodesis for the treatment of severe hallux valgus, using fixation with Kirschner wires, a simple technique with very inexpensive implants, available in the vast majority of hospitals.

Methods

This study was approved by the Institutional Review Board and registered on the Plataforma Brazil database under CAAE (Ethics Evaluation Submission Certificate) number: 26187319.3.0000.5330.

The Informed Consent Form was waived as the data were collected through medical records, retrospectively and while maintaining the postoperative clinical routine.

Medical records of patients who had undergone correction of severe hallux valgus through metatarsophalangeal arthrodesis between March 2011 and April 2018 were evaluated. Preoperative clinical information and radiographs were evaluated and compared with postoperative radiographs and clinical data collected at least twelve months after surgery.

According to clinical routine, the AOFAS score is applied first. This system consists of a functional scale of the metatarsophalangeal joint that measures alignment, pain, functionality and mobility, graded from 0 to 100. The system is followed by the visual analog scale for pain, then the satisfaction questionnaire containing the following options: totally satisfied, satisfied with reservations, or not satisfied.

The radiographs evaluated were weight-bearing anteroposterior and lateral pre and postoperative views of the foot.

The review of medical records with AOFAS scores, visual analog scale of pain and satisfaction questionnaire allowed an objective analysis of the degrees of satisfaction, pain, and functionality of all patients. The degrees of deformity were also assessed using radiographic measurement of the intermetatarsal and metatarsophalangeal angles, comparing the results of the pre and postoperative radiographs. The evaluation of postoperative radiographs revealed consolidation of the arthrodesis and the degree of angular correction of the deformity.

Surgical technique

The procedure was performed under sedation and ankle block in all cases. Through a medial incision, made in the center of the metatarsophalangeal joint, measuring approximately 5 centimeters in length, the cartilage of the head of the first metatarsal and of the proximal phalanx was removed manually using an osteotome, rongeur and curette. The first ray was then realigned in the frontal and sagittal planes and fixed with 4 crossed Kirschner wires, 2 of which were from proximal to distal and 2 from distal to proximal, and with cerclage in a horizontal figure-of-eight format (Figures 1A and 1B). After radiological control of the positioning of the wires and of the correction achieved, the joint capsule and skin were closed with vicryl 3-0 and vicryl rapide 4-0 sutures, respectively.

Postoperative period

Weight-bearing with Barouk postoperative shoes was allowed the day after surgery and maintained until the eighth postoperative week. Radiographs are taken between 6 and 8 weeks and between 12 and 16 weeks from the date of surgery. The postoperative questionnaire with the AOFAS scale and visual analogue scale of pain is completed in the last review 12 months after surgery.

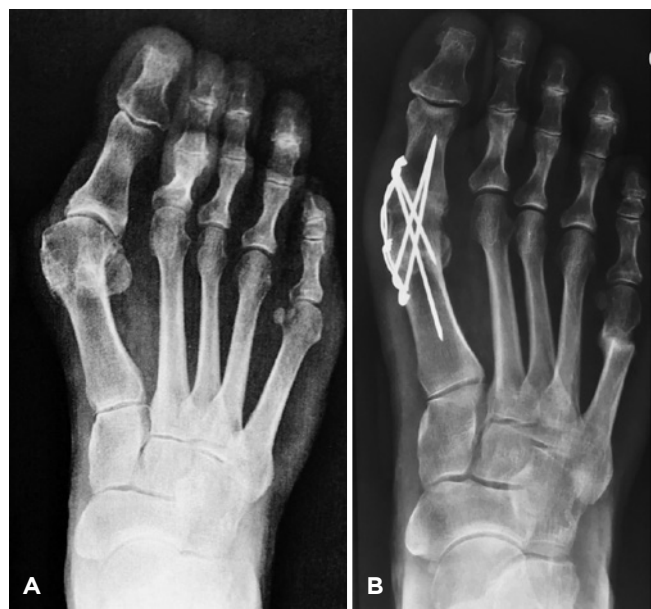

Figure 1. A. Pre and B. Postoperative radiographs.

Statistical analysis

Quantitative variables were described by mean and standard deviation or median and interquartile range. Categorical variables were described by absolute and relative frequencies.

To compare means before and after surgery, the paired sample t-test was applied.

The level of significance adopted was 5% ($p < 0.05$) and the analyses were carried out using SPSS version 21.0.

Results

We evaluated 21 patients with a mean age of 69 years (+10), where the most frequently observed comorbidity was rheumatoid arthritis occurring in 5 patients (23.8%). Fourteen patients had no associated pathology (66.7%) while 2 had other conditions (9.6%) (spastic hemiplegia and Parkinson's disease).

Of the 21 patients evaluated, eight (38.1%) were operated bilaterally, totaling 29 feet, six feet operated on the right side (20.7%) and seven on the left (24.1%). The mean follow-up time was 41 months (+22.5).

After this follow-up period we applied the satisfaction questionnaire and observed that 17 feet generated a totally satisfied response (58.6%), while 12 feet generated a satisfied with reservations response (41.3%) and no patient was dissatisfied with the surgery.

Application of the AOFAS score revealed a significant improvement, with a preoperative score of 26.5 (+14.6) and a postoperative score of 78 points (+8.8) (Table 1). There was a significant reduction in pain levels, as shown in Figure 2.

Table 1. Pre and postoperative values

Variables	Pre	Post	p
AOFAS (n=29)	26.5 ±14.6	78.1±8.8	<0.001
VAS (n=29)	8 (7-9)	0 (0-1)	<0.001
MTPJ (n=19)	38.5±9.9	13.1±4.9	<0.001
IMMA (n=19)	18.8±10.7	8.9±2.7	0.001

AOFAS: American Orthopaedic Foot and Ankle Society score; VAS: Visual Analog Scale; MTPJ: metatarsophalangeal joint; IMMA: intermetatarsal angle.

Implant removal was required in 17 of the 29 feet (58.6%) during follow-up.

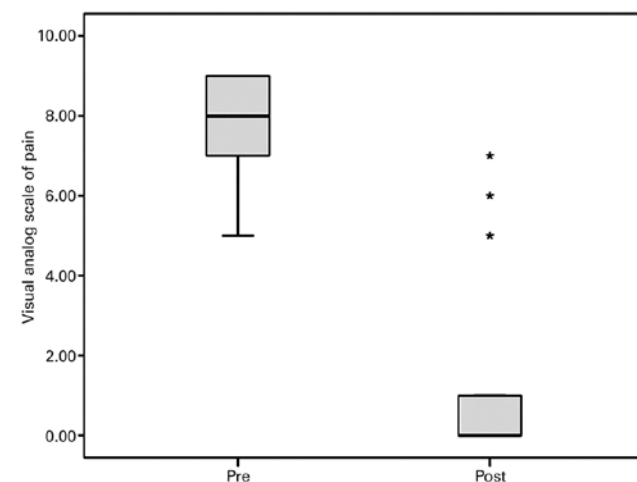


Figure 2. Comparison of the visual analog scale of pain before and after (Pre: median (P25-P75)=8 (7-9); Post: median (P25-P75)=0 (0-1); $p < 0.001$).

The radiographic angle measurements revealed a mean improvement in the metatarsophalangeal angle of 25°, from a preoperative mean of 38.5° to a postoperative mean of 13.1°. The intermetatarsal angle improved on average 3.8°, from a preoperative mean of 18.8° to a postoperative mean of 15° (Table 1).

Complications

A bilaterally operated female patient developed deep vein thrombosis, which progressed favorably and without sequelae with drug treatment. Hardware removal was required in 17 of the 29 feet, entailing the need for a secondary procedure in 58.6% of cases. There were no cases of recurrence.

Discussion

Arthrodesis of the metatarsophalangeal joint is a procedure widely used in the treatment of hallux valgus, especially in complicated, recurrent, and/or severe cases. The degree of postoperative satisfaction and the rate of return to previous activities and sports after the procedure are high^(2,3). Although

Ripstein recommended the combined use of a proximal procedure, osteotomy or Lapidus arthrodesis for angular correction of the deformity, several studies have shown that isolated MTPJ arthrodesis has the ability to bring the hallux valgus and intermetatarsal angles back to values considered normal⁽²¹⁾.


The most common complication is nonunion, with an estimated occurrence of around 7% in the presence of hallux valgus⁽²²⁾. Increasingly robust fixations with increasingly sophisticated implants aim to reduce the incidence of this complication that usually requires reintervention, which did not occur in any case from our series. Another reason for reoperation in patients undergoing metatarsophalangeal arthrodesis of the hallux is the removal of synthesis material, which was very common in our series. As it is a joint subject to high demand, osteosynthesis for MTPJ arthrodesis is usually robust, but soft tissue coverage in the region is scarce and irritation of the synthesis material often occurs as soon as the initial procedural edema decreases. In our group of patients, the consolidation rate was 100%, eliminating the need for reintervention due to nonunion, and surpassing other studies. We credit this success to longitudinal fixation involving an

extensive intramedullary area promoted by crossed Kirschner wires, combined with cerclage that promotes a tension band effect against the resilience of the deformity and produces compression at the arthrodesis focus.

On the other hand, our reintervention rate for the removal of hardware was 58.6%, much higher than other series, which we associated with the difficulty in adjusting the exact length of the Kirschner wires so that they are not protruded at the ends. The advantages of the procedure include technical simplicity, once no special instrumentation is needed, and the low cost, and availability of the hardware used.

Conclusion

MTPJ arthrodesis in the treatment of hallux valgus performed with crossed Kirchner wires and cerclage produced high levels of satisfaction, with substantial improvement in pain and functional parameters, and excellent correction of radiographic parameters with consolidation in all cases, but had the drawback of a high rate of reintervention to remove synthesis material.

Authors' contributions: Each author contributed individually and significantly to the development of this article: LHB *(<https://orcid.org/0000-0002-2299-8452>) interpreted the results of the study, participated in the review process, approved the final version; JAVS *(<https://orcid.org/0000-0002-6321-9566>) conceived and planned the activities that led to the study, wrote the article, participated in the review process, approved the final version. *ORCID (Open Researcher and Contributor ID) 

References

- Barnish MS, Barnish J. High-heeled shoes and musculoskeletal injuries: a narrative systematic review. *BMJ Open*. 2016;6(1):e010053.
- Coughlin MJ, Jones CP. Hallux valgus: demographics, etiology, and radiographic assessment. *Foot Ankle Int*. 2007;28(7):759-77.
- Nery C, Ballerini FJ, Kobata SI. Halux valgo em homens: demografia, etiologia e radiologia comparativas. *Rev ABTPé*. 2009;3(1):41-7.
- Nery C, Ballerini FJ, Kobata SI. Hálux valgo em homens – parte II: avaliação do tratamento cirúrgico. *Rev ABTPé*. 2009;3(2):81-8.
- McKean RM, Bergin PF, Watson G, Mehta SK, Tarquinio TA. Radiographic evaluation of intermetatarsal angle correction following first MTP joint arthrodesis for severe hallux valgus. *Foot Ankle Int*. 2016;37(11):1183-6.
- Coughlin MJ, Grebing BR, Jones CP. Arthrodesis of the first metatarsophalangeal joint for idiopathic hallux valgus: intermediate results. *Foot Ankle Int*. 2005;26(10):783-92.
- Cronin JJ, Limbers JP, Kutty S, Stephens MM. Intermetatarsal angle after first metatarsophalangeal joint arthrodesis for hallux valgus. *Foot Ankle Int*. 2006;27(2):104-9.
- Dalat F, Cottalorda F, Fessy MH, Besse JL. Does arthrodesis of the first metatarsophalangeal joint correct the intermetatarsal MIM2 angle? Analysis of a continuous series of 208 arthrodeses fixed with plates. *Orthop Traumatol Surg Res*. 2015;101(6):709-14.
- Drampalos E, Vun SH, Fayyaz I. Intramedullary and intra-osseous arthrodesis of the hallux metatarsophalangeal joint. *J Orthop Surg (Hong Kong)*. 2016;24(3):358-61.
- Pydah SK, Toh EM, Sirikonda SP, Walker CR. Intermetatarsal angular change following fusion of the first metatarsophalangeal joint. *Foot Ankle Int*. 2009;30(5):415-8.
- Dayton P, Feilmeier M, Hunziker B, Nielsen T, Reimer RA. Reduction of the intermetatarsal angle after first metatarsal phalangeal joint arthrodesis: a systematic review. *J Foot Ankle Surg*. 2014;53(5):620-3.
- Von Salis-Soglio G, Thomas W. Arthrodesis of the metatarsophalangeal joint of the great toe. *Arch Orthop Trauma Surg*. 1979;95(1-2):7-12.
- Humbert JL, Bourbonniere C, Laurin CA. Metatarsophalangeal fusion for hallux valgus: indications and effect on the first metatarsal ray. *Can Med Assoc J*. 1979;120(8):937-41, 56.
- Politi J, John H, Njus G, Bennett GL, Kay DB. First metatarsal-phalangeal joint arthrodesis: a biomechanical assessment of stability. *Foot Ankle Int*. 2003;24(4):332-7.
- Pinter Z, Hudson P, Cone B, Motwani G, Prasad K, Shah A. Radiographic evaluation of first MTP joint arthrodesis for severe hallux valgus: does the introduction of a lag screw improve union rates and correction of the intermetatarsal angle? *Foot (Edinb)*. 2017;33:20-4.

16. Hunt KJ, Barr CR, Lindsey DP, Chou LB. Locked versus nonlocked plate fixation for first metatarsophalangeal arthrodesis: a biomechanical investigation. *Foot Ankle Int.* 2012;33(11):984-90.
17. Hunt KJ, Ellington JK, Anderson RB, Cohen BE, Davis WH, Jones CP. Locked versus nonlocked plate fixation for hallux MTP arthrodesis. *Foot Ankle Int.* 2011;32(7):704-9.
18. Bottlang M, Doornink J, Lujan TJ, Fitzpatrick DC, Marsh JL, Augat P, et al. Effects of construct stiffness on healing of fractures stabilized with locking plates. *J Bone Joint Surg Am.* 2010;92 Suppl 2:12-22.
19. Gardner MJ, Nork SE, Huber P, Krieg JC. Stiffness modulation of locking plate constructs using near cortical slotted holes: a preliminary study. *J Orthop Trauma.* 2009;23(4):281-7.
20. Roukis TS, Meusnier T, Augoyard M. Incidence of nonunion of first metatarsophalangeal joint arthrodesis for severe hallux valgus using crossed, flexible titanium intramedullary nails and a dorsal static staple with immediate weightbearing in female patients. *J Foot Ankle Surg.* 2012;51(4):433-6.
21. McKean RM, Bergin PF, Watson G, Mehta SK, Tarquinio TA. Radiographic evaluation of intermetatarsal angle correction following first MTP joint arthrodesis for severe hallux valgus. *Foot Ankle Int.* 2016;37(11):1183-6.
22. Chien C, Alfred T, Freihaut R, Pit S. First metatarsophalangeal joint arthrodesis in hallux valgus versus hallux rigidus using cup and cone preparation compression screw and dorsal plate fixation. *Cureus.* 2017;9(10):e1786.