

Case Report

Surgical treatment of cleft foot in an adult patient: case report

Filipe Sá Malheiro¹ , José Martel Bastos¹ , Arminda Malheiro² 

1. Centro Hospitalar do Baixo Vouga, EPE, Aveiro, Portugal.

2. Hospital Dr. Francisco Zagalo, Ovar, Portugal.

Abstract

Cleft foot is a rare congenital malformation characterized by a central conical defect extending from the periphery of the foot towards the tarsus, affecting one or more central rays. Surgical intervention should be attempted at a very early age to prevent further pathological adaptations. The authors present the case of an adult woman admitted with painful callosities on the feet and difficulty selecting shoes. She was diagnosed with cleft foot and submitted to surgical treatment. The postoperative period was uneventful and the patient was very satisfied with the results of the surgery. This is only the second reported case of surgical management of cleft foot in an adult patient, and the first to describe the use of internal fixation.

Level of Evidence V; Therapeutic Studies; Expert Opinion.

Keywords: Foot deformities, congenital; Syndactyly/surgery; Female; Adult.

Introduction

Cleft foot or ectrodactyly is a rare congenital malformation with an incidence of approximately 1 in 90,000 live births. It is also known as a lobster claw or congenital split foot and is characterized by a spectrum of foot abnormalities^(1,2). Cleft foot is usually inherited as an autosomal dominant trait with reduced penetrance. It may be isolated or occur as part of a syndrome. It usually presents bilaterally and is often combined with cleft hands^(1,3). Other anomalies associated with cleft foot include cleft lip and palate, syndactyly, scoliosis, imperforate anus, cataract, and deafness⁽²⁾.

The main characteristic of the cleft foot is a central conical defect running from the periphery toward the tarsus, resulting in the absence of one or more central rays. The malformation may range from a mere deepening of the interdigital commissure to a lobster-claw or monodactyl foot^(4,5). Blauth and Borisch classified these defects into six major types:

1. Five normal metatarsal bones with partial or complete aplasia of toes 2-5.
2. Five metatarsals with partial hypoplasia or synostosis.
3. Only 4 metatarsals with the second or third always missing.
4. Only 3 metatarsals with the second and third, or third and fourth, always missing.

5. Lobster-claw foot with absence of the second, third, and fourth rays.
6. Monodactyl foot with only the fifth metatarsal and toe.

Surgical intervention should ideally be attempted at a very early age to reduce the likelihood of further pathological adaptations to compensate for the effects of the malformation. Delaying surgical intervention could result in the continued progression of the deformity. The objectives of cleft foot surgery: closing the cleft to the greatest possible extent, maintaining symmetrical feet, and preserving the position of the border rays to prevent collapse and valgus deformities of the toes. In this study, the authors describe the surgical correction of congenital cleft foot in an adult patient⁽⁶⁻⁸⁾.

Case report

This study was approved by an Institutional Review Board.

A 44-year old woman was admitted to the hospital with complaints of painful callosities on the feet and difficulty wearing shoes. Both issues had been progressively worsening over time. A clinical interview revealed that her sister and nephew had similar developmental anomalies of the hands and feet. No other members of the family reported a similar issue.

Study performed at the Hospital Dr. Francisco Zagalo, Ovar, Portugal.

Correspondence: Filipe Sá Malheiro. 3810-164 Artur Ravara Av, Aveiro, Portugal, Zip Code: 3810-164. **E-mail:** fmalheiru@gmail.com. **Conflicts of interest:** none. **Source of funding:** none. **Date received:** January 08, 2021. **Date accepted:** March 05, 2021. **Online:** April 30, 2021.

How to cite this article: Malheiro FS, Bastos JM, Malheiro A. Surgical treatment of cleft foot in an adult patient: case report. J Foot Ankle. 2021;15(1):70-2

The patient's feet were widely spread with only two rays present (deep cleft with an absence of central foot rays) (Figure 1). Calluses were present on the bunion and bunionette but not on the plantar aspect of the foot. Ankle range of motion was normal.

Her American Orthopedic Foot and Ankle Society (AOFAS) score was 72 out of a possible 100. Anteroposterior and lateral standing X-rays revealed the presence of only two rays in each foot (type V according to the Blauth W. and Borisch N.C. classification) (Figure 3). There was no axial deviation of the ankle.

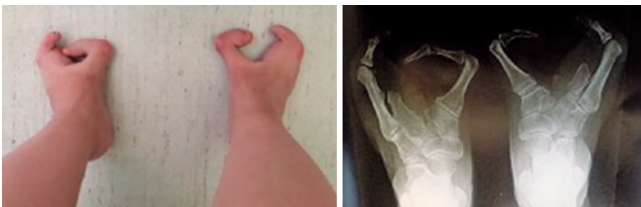

Figure 1. Photo and AP X-ray of the patient's feet.

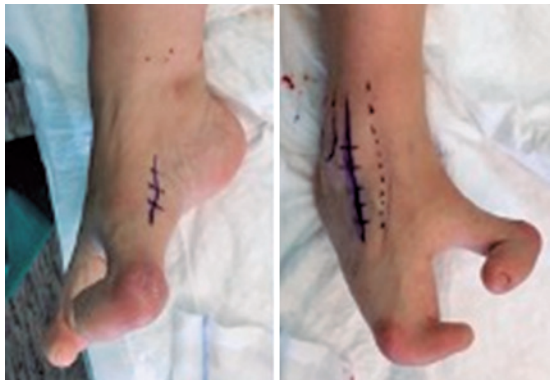

Figure 2. Medial and lateral approaches for the modified Lapidus procedure, basal fifth metatarsal osteotomy, and removal of the hypoplastic fourth metatarsal.

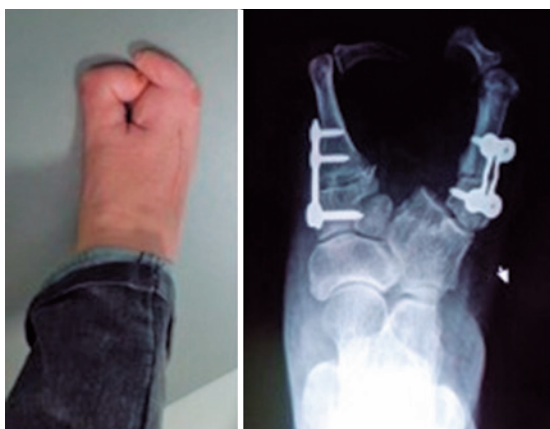

Figure 3. Photo and X-ray of patient's right foot at 6 postoperative months.

Surgical correction was first performed on the foot that caused the most inconvenience to the patient. In the first stage, two different procedures were performed on the right foot. A tourniquet was applied with the patient in a supine position, and a 5cm medial incision was made over the first tarsometatarsal joint. After careful dissection and protection of the extensor tendons, closing base lateral wedge osteotomy was performed on the first metatarsal, which was fixed to the first cuneiform bone using a plate and screws in a modification of the Lapidus procedure. A 10cm lateral incision was then made, and after protecting the extensor tendons, the authors performed an en bloc excision of the fourth metatarsal using a periosteotome, followed by a medial wedge osteotomy of the fifth metatarsal, and fixation with plate and screws. The access openings were closed with absorbable multifilament sutures for subcutaneous closure and nonabsorbable monofilament suture for skin closure. The patient was asked to wear Barouk shoes and allowed to bear weight as tolerated.

The postoperative period was uneventful with no skin-related complications. Alternate sutures were removed on the 15th postoperative day. After 6 postoperative months, the patient was very satisfied with the results of the surgery. She reported increased quality of life and was now able to wear a regular shoe on her right foot (Figure 3 and 4). The patient also expressed interest in undergoing surgery on the other foot.

Discussion

Cleft foot is a rare congenital anomaly characterized by foot splitting of varying severity^(1,2,4). The condition does not affect the rearfoot, which is why the intervention described in the present study was limited to the forefoot. The anomaly is usually bilateral and often co-occurs with the splitting of the hands^(1,3).

There is no consensus on the surgical management of cleft foot deformity. Due to the rarity of this pathology, few publications have discussed its surgical treatment; moreover, all but one of the articles published on the topic concern the treatment of children⁽⁶⁻¹⁰⁾.



Figure 4. Postoperative comparison of shoes on both feet of the patient.


Many authors recommend that children do not undergo surgery if their feet provide adequate support and they can wear normal shoes. Others support the applicability of surgical interventions for cleft foot deformity and suggest that they be carried out before the patient reaches 1 year of age^(6,7). The aim of treatment in patients with this congenital anomaly is to improve foot function and esthetics⁽⁸⁾.

Cleft closure is a standard operative procedure for the treatment of cleft foot. It is useful in patients with at most one central ray deficiency, who tend to have a narrow forefoot and overlapping toes. However, in patients with two or three central ray deficiencies, there is no tissue in the central region of the forefoot. In these cases, the simple closure of the cleft cannot correct the defects and maintain the width of the forefoot, and a valgus deformity of the residual toes is likely to occur⁽¹⁰⁾.

Leonchuk et al, are responsible for the only description of surgical treatment of cleft foot in an adult. The authors described the case of a 31-year-old patient treated with the Ilizarov technique with minimum fixation due to concerns regarding soft tissue defects of the central rays and central wound healing⁽¹⁰⁾. Despite the lack of previous reports on the use of this particular management strategy, the authors suggested the use of internal fixation and the patient agreed.

Conclusion

Cleft foot is a rare condition that is typically familial and co-occurs with cleft hand. The main aim of surgery in these cases is to improve the cosmetic appearance of the foot and allow for the use of normal shoes. While surgical interventions for cleft foot are usually performed in children, surgical treatment using internal fixation is an option for adults with this deformity.

Authors' contributions: Each author contributed individually and significantly to the development of this article: FSM *(<https://orcid.org/0000-0002-1555-7181>) bibliographic review, conceived and planned the activities that led to the study, clinical examination, performed the surgeries; JMB *(<https://orcid.org/0000-0003-2649-9762>) participated in the review process; AM *(<https://orcid.org/0000-0002-9657-2710>) performed the surgeries. All authors read and approved the final manuscript. *ORCID (Open Researcher and Contributor ID) 

References

1. Jenson B. Congenital deformities of the upper extremities. Ejnar Munksgaard: Copenhagen; 1949.
2. Phillips RS. Congenital split foot (lobster claw) and triphalangeal thumb. *J Bone Joint Surg Br.* 1971;53(2):247-57.
3. Durmaz MS, Demirtaş H, Hattapoğlu S, Kara T, Göya C, Adin ME. Bilateral cleft foot: Radiographic and prenatal ultrasound features of two siblings with a review of literature. *Medicina (Kaunas).* 2016;52(4):257-61.
4. Blauth W, Borisch NC. Cleft feet. Proposals for a new classification based on roentgenographic morphology. *Clin Orthop Relat Res.* 1990;(258):41-8.
5. Baba AN, Bhat YJ, Ahmed SM, Nazir A. Unilateral cleft hand with cleft foot. *Int J Health Sci (Qassim).* 2009;3(2):243-6.
6. Sumiya N, Onizuka T. Seven years' survey of our new cleft foot repair. *Plast Reconstr Surg.* 1980;65(4):447-59.
7. Wood VE, Peppers TA, Shook J. Cleft-foot closure: a simplified technique and review of the literature. *J Pediatr Orthop.* 1997;17(4):501-4.
8. Choudry Q, Kumar R, Turner PG. Congenital cleft foot deformity. *Foot Ankle Surg.* 2010;16(4):e85-7.
9. Tani Y, Ikuta Y, Ishida O. Surgical treatment of the cleft foot. *Plast Reconstr Surg.* 2000;105(6):1997-2002.
10. Leonchuk SS, Neretin AS, Blanchard AJ. Cleft foot: A case report and review of literature. *World J Orthop.* 2020;11(2):129-36.