

Special Article

New classification of osteochondral lesions of the talus in adults

Jorge Batista¹ , German Joannas² , Leandro Casola² , Lucas Logioco¹ , Guillermo Arrondo² 

1. Centro Artroscopico Jorge Batista, CABA, Buenos Aires, Argentina.

2. Instituto Dupuytren, CABA, Buenos Aires, Argentina.

Abstract

Osteochondral lesions (OCL) of the ankle in adults are frequent lesions that mainly affect the cartilage and the subchondral bone, are relatively common, and have varied etiologies. However, in 50% of patients, these lesions may occur concomitantly with chronic instability of the ankle associated with lower limb deformities, acute sprains of the ankle, or fractures. We propose a classification into four types of lesions (traumatic, non-traumatic, with lateral instability of the ankle, and with mechanical axis defects), focusing not only on the diagnosis and treatment of OCL but also on associated injuries, such as instability and/or supramalleolar and hindfoot deformities.

Level of Evidence V; Therapeutic Studies; Expert Opinion.

Keywords: Osteochondritis/classification; Osteochondritis/diagnosis; Ankle joint/surgery; Ankle injuries/diagnosis.

Introduction

Osteochondral lesions (OCLs) of the ankle in adults are frequent lesions that mainly affect the cartilage and the subchondral bone, with an incidence ranging from 0.09% to 4%⁽¹⁾. There is still controversy about the etiology and pathogenesis of OCLs. Several terminologies have been used to classify these lesions: OC defects, transchondral fractures, osteochondritis dissecans, and intra-articular fractures^(2,3). The expression osteochondral lesion covers a wide range of diseases, including bone edema with or without subchondral contusion, OC fracture, osteochondritis dissecans, and osteoarthritis resulting from a long-term disease. Subchondral bone compromise may manifest as bone marrow edema, fractures, sclerosis, and/or formation of cysts. Ankle OCLs are relatively common lesions with many etiologies, but in 50% of patients they may occur concomitantly with chronic instability of the ankle, lower limb deformities, acute sprains of the ankle, or fractures.

We propose a classification into four types of lesions (traumatic, non-traumatic, with lateral instability of the ankle, and with mechanical axis defects), focusing not only on diagnosis and treatment of OCL, but also on associated injuries, such as instability and/or supramalleolar and hindfoot deformities.

Discussion

In the current literature, different hypotheses have been proposed for the origin of OCLs. These hypotheses, which include vascular diseases, hormone factors, endocrine disorders, ossification defects, genetic and embolic phenomena, could explain the onset of these disorders and, in some cases, the bilateral presentation of the lesions. The classification and understanding of these lesions have been developing in a gradual and staggered manner⁽⁴⁾. The emergence of computed tomography and magnetic resonance imaging (MRI) has changed the perspective on the correct classification and treatment of these lesions. Advances in these technologies and devices in the last 10 years, as well as new high-definition MRI techniques, have provided great detail on pathological anatomy and have allowed us to incorporate a new approach on these lesions.

The diagnostic strategies for suspected cartilage injuries of the ankle remain a subject of frequent debate worldwide. Up to date, there is no consensus in the literature with regard to optimal images and tests to request in patients with suspected ankle cartilage injury, as well as with regard to specific imaging protocols that should be used. Furthermore, no study has examined the relationship between the results of preoperative imaging scans and operative findings⁽⁵⁾.

Study performed at the Centro Artroscopico Jorge Batista, CABA, Buenos Aires, Argentina.

Correspondence: Leandro Casola, 1742 Azcuenaga Av., Vicente Lopez, Buenos Aires, Argentina, **Zip Code:** 1638. **Conflicts of interest:** none. **Source of funding:** none. **Date received:** April 06, 2021. **Date accepted:** April 07, 2021. **Online:** April 30, 2021.



The first description of the topic was made in 1959 by Berndt and Harty⁽⁶⁾, who identified and described several determining concepts, such as trauma as the primary cause of all OC “fractures”, and based their classification on radiological manifestation of the injury. For many years and after this publication, traumatic etiology was commonly accepted as the predominant causal agent and has been widely used to choose the best therapeutic option between conservative or surgical treatment. The main advantage of this classification is its generalized use and its simplicity. Although conventional radiography (CR) is still the diagnostic modality initially used to evaluate the ankle, Hepple showed that from 30 to 43% of OCLs of the talus diagnosed on MRI were invisible on CR. However, Lusse and O’Loughlin reported that, in a prospective study with 92 patients, 50% of OCLs were not identified on simple X-rays^(4,7).

In 1989, Anderson showed that the four-stage classification did not predict the formation of subchondral cysts during the pathogenesis of OCLs, and stage 2b was subsequently added to take this matter into account. With the use of axial computed tomography (ACT) and MRI, these cysts are more frequently observed. Histological studies suggest that such cysts develop in areas of post-traumatic bone necrosis containing fibrin, vascular granulation tissue, and often segments of articular cartilage⁽⁸⁻¹⁰⁾.

In 1990, Ferkel and Sgaglkione designed a staging system that assesses OCLs by ACT, based on the original classification by Berndt and Harty^(11,12). The authors introduced stage I, which described a cystic lesion within the talar dome with intact roof in all views; stage IIA was described as a cystic lesion that communicates with the talar dome surface; and stage IIB as a lesion of the open articular surface with overlying non-displaced fragments. Stages III and IV were similar to those described in the classification by Berndt and Harty⁽¹¹⁾. MRI can evaluate location and size of the injury in three planes, subchondral bone marrow edema, formation of subchondral cysts and/or sclerosis, status of the overlying cartilage, and depression in the contour of the articular bone plate.

Taranow et al.⁽¹³⁾ used MRI to describe the condition of both the cartilage and the subchondral bone using the classical four-stage classification for the bone component, while describing that the cartilage was viable and intact (grade A) or non-viable (grade B). Mintz et al.⁽¹⁴⁾ established a correlation between MRI and arthroscopic findings. Anderson classification⁽¹⁵⁾, presented in 1989, is another modification of the initial staging system based on conventional radiological assessment by Berndt and Harty. Stage 1 lesions result from bone marrow contusion. MRI is the most sensitive method to represent this stage, with no correlation sign on CR or on ACT with intra-articular contrast injection. Stage 2 refers to partial detachment of OCL, with formation of subchondral cyst or fissure that incompletely separates the lesion from the talar dome. In stage 3, it is possible to observe a completely separated non-displaced fragment on MRI, with adjacent bone marrow edema. Stage 4 consists of a displaced fragment, often accompanied by surrounding bone marrow edema.

The use of MRI should be evaluated in a clinical context, and in all cases ACT or cone beam CT (CBCT) are recommended to assess the size and extent of the lesion. Some authors, including us, believe that MRI may overdiagnose or overestimate the depth of OCLs and advise caution in using these classification systems^(16,17). The use of MRI should be reserved only to evaluate the subchondral bone⁽¹⁸⁾. Arthrographic techniques are often used in an OCL is detected on MRI and in those cases when arthroscopic treatment is considered. Similar to the Outerbridge classification (widely used in the staging of knee cartilage lesions), a modified staging system may be used to assess the extent of cartilage defects with correlation with knee arthroscopy⁽¹⁹⁾.

In a great number of patients, cartilage lesions may be isolated. In the last years, a new technique (CBCT) has been used for the first time in the preoperative assessment of dental implants, but its use has been recently expanded to musculoskeletal injuries. This technique combines high spatial resolution, a relatively low radiation dose, and low cost equipment, and is useful in the assessment of trauma of small bones and joints, particularly when there is clinical suspicion of fracture despite negative findings on simple radiographies⁽²⁰⁾. CBCT after intra-articular injection of iodine contrast (CBCT arthrography) may provide exquisite details of the articular cartilage using very thin slices and multiplanar reformatting. In patients with suspected isolated chondral lesion, the trabecular architecture of the subchondral bone is much better visualized on CBCT than on CR or MRI. In this sense, CBCT-arthrography (CBCT-A) may be a very promising technique that could be used in specific situations.

Complementary classification systems have emerged using intra-operative findings, with the development of new arthroscopic devices. Pritsch et al.⁽²¹⁾ classified OCLs of the talus according to the quality of cartilage, as it can be observed on arthroscopic visualization. The disadvantage of an arthroscopic classification system is the fact that it is centered on the cartilage injury and it does not consider the underlying bone component of the lesion.

A myriad of additional classification systems have been proposed, on the basis of computed tomography, MRI, arthroscopic findings, and an anatomical grid, which was introduced by Elias et al.⁽¹⁷⁾ in 2007 with the purpose of allowing for a better treatment planning. These authors assess the actual incidence of OCLs in talus dome by location and by morphological characteristics through MRI. The articular surface of the talar dome was divided using a grid with three columns and three rows, resulting in a configuration with nine equal zones in the axial axis. The nine equal areas were assigned numerical identifiers from 1 to 9, beginning with the most anterior and medial region and advancing laterally and then posteriorly⁽¹⁷⁾.

Other authors indicate treatment based on OCL size, symptoms, age, level de activity, and limb alignment^(18,22).

The aim of surgical treatment is to create an optimal biological environment to repair the subchondral bone and allow for the generation of a chondral surface⁽⁴⁾. Different treatment options have also been proposed, including conservative and surgical treatment, based on location, size and extent of sub-

chondral bone injury. Surgical treatment may be arthroscopic or open surgery that includes bone marrow stimulation (BMS), with debridement, curettage, and microfractures. Replacement and fixation of fragments, autologous transplantation, or allograft, and cultivation of chondrocytes are also indicated^(4,22). A minimally invasive (arthroscopic) approach to treat these lesions also brings some advantages^(23,24).

Most authors reported that more than 50% of patients with OCL have an acute ligament injury, an associated fracture, or history of chronic ankle instability. Based on our review and our experience on management and treatment of OCLs of the talus, we have introduced a reviewed classification, based on CR and specific radiographies with assessment of alignment of distal extremities, computed tomography, MRI, arthroscopic findings, and history of ankle instability (Table 1).

The focus of this new classification is based on determining associated instabilities and/or ankle and hindfoot deformities. It also refers to OCL size and depth. All these parameters allow us to define the appropriate treatment of each lesion and may predict its prognosis in an increasingly manner according to the type. The first distinction on which we based the new classification was between patients with or without associated trauma. Traumatic lesions (stage 1) were classified

into two groups: stage 1A in cases of previous trauma with isolated compromise of the talar cartilage (flap); and stage 1B in those with previous history of cartilage and subchondral bone trauma. Non traumatic lesions (Stage 2) were also divided into two types: stage 2A, in which an intact subchondral cyst can be visualized (Figure 1); and stage 2B, with open cyst in the talotibial joint (progression of stage 2A) (Figure 2). Stage 1B and 2B are subdivided in: .1: lesion <10mm diameter <5mm deep and .2: lesion >10mm diameter >5mm deep. Stage 3 refers to the above mentioned subtypes when associated with lateral ankle instability. Stage 4 includes any of the previous OCL stages when associated with varus or valgus misalignment of the hindfoot and/or talotibial joint and is divided into stage 4A, which encompasses calcaneus varus or valgus; and stage 4B, which encompasses varus or valgus deformities, mechanical axis deviation of the talotibial joint.

Table 1. Chart of the new classification of osteochondral lesions of the talus in adults

Osteochondral lesions of the talus in adults J. Batista, G. Joannas, L. Casola, L. Loggioco, G. Arrondo	
1A	Traumatic lesion with isolated cartilage injury (flap) Tx: arthroscopy, curettage, and microfractures.
1B	Traumatic lesion (cartilage and subchondral bone injury)
1B.1	Lesion <10mm in diameter and <5mm of depth (superficial lesion) Tx: arthroscopy, curettage, and microfractures.
1B.2	Lesion >10mm in diameter and >5mm in depth Tx: fragment fixation with osteosynthesis, open surgery, osteochondral graft, or mosaicplasty.
2A	Non-traumatic isolated bone injury, subchondral cyst. Tx: retrograde drilling.
2B	Non-traumatic open subchondral bone cyst with articular connection (progression of type 2A).
2B.1	Lesion measuring <10mm in diameter and <5mm in depth (superficial lesion). Tx: arthroscopy, curettage, and microfractures.
2B.2	Lesion measuring >10mm in diameter and >5mm in depth. Tx: open surgery, osteochondral graft, or mosaicplasty.
3	Type 1 or 2 lesions associated with lateral instability of the ankle Tx: ligament repair.
4	With limb deformities
4A	Types 1 or 2 lesions with hindfoot deformity = varus or valgus calcaneus Tx: varus or valgus calcaneal osteotomy.
4B	Type 1 or 2 lesion with supramalleolar deformity of distal tibia (varus or valgus) Tx: varus or valgus supramalleolar osteotomy.

Tx: treatment.

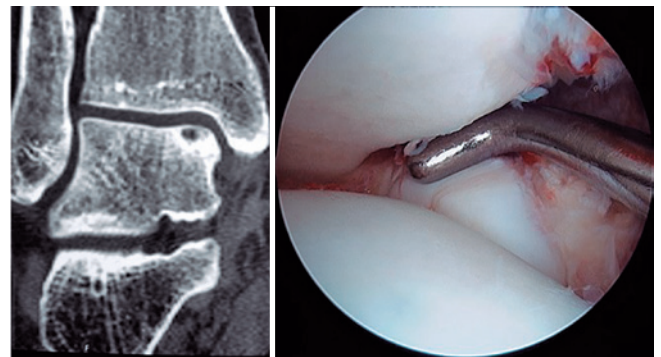


Figure 1. Intact subchondral cyst, computed tomography scan on the left. Arthroscopic image showing no evidence of communication between the cyst and the articular cavity.

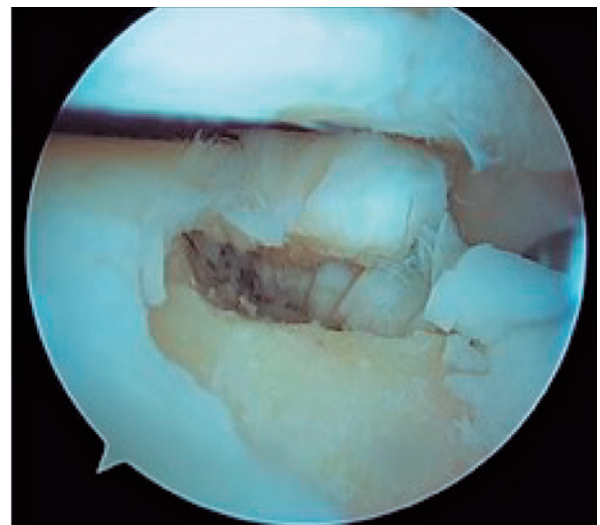


Figure 2. Arthroscopic view showing communication between the subchondral cyst and the articular cavity. It is the progression of type 2A in which cartilage collapse occurs within the bone defect.

Type 1A: traumatic (chondral flap with intact subchondral bone). We suggest arthroscopic treatment with flap resection, with subsequent curettage, debridement, and microfractures (Figure 3).

Type 1B: traumatic lesions that affect the cartilage and the subchondral bone.

1B.1: lesion <10mm of diameter and <5mm of depth (superficial lesion). We suggest arthroscopic treatment with curettage of the lesion, debridement, and microfractures.

1B.2: >10mm of diameter and lesion >5mm of depth. We suggest arthroscopic fixation of the fragment or open surgery with OC transplantation or mosaicplasty.

Type 2A: non-traumatic bone injury due to intact subchondral cyst. We suggest retrograde perforations with previous arthroscopic evaluation of the lesion to confirm that talar cartilage is intact.

Type 2B: non-traumatic lesion and visualization of an open subchondral bone cyst with articular connection (progression of type 2A).

2B.1: lesion measuring <10mm in diameter and <5mm in depth (superficial). We suggest arthroscopic treatment with curettage of the lesion, debridement, and microfractures.

2B.2: lesion measuring >10mm in diameter and >5mm in depth. We suggest open surgery with OC graft or mosaicplasty.

Type 3: type 1 or 2 OCLs associated with lateral instability of the ankle.

In both subtypes, the associated ligament injury should be treated by ligament repair, augmentation, or reconstruction, depending on the degree of lateral instability (Figure 4).

Type 4: type 1 or 2 OCLs associated with hindfoot deformity (varus or valgus) and/or talotibial deformity (supramalleolar).

4A: when the deformity occurs exclusively on the hindfoot, we treat the OCL according to the above mentioned subtypes and indicate varus or valgus calcaneal osteotomy, according to the deformity (Figure 5).

4B: when the deformity is on the talotibial joint, we indicate treating the OCL according to its type and subtype and then performing a varus or valgus supramalleolar osteotomy, according to the deviation of loading axis (Figure 6).

It is worth mentioning that this treatment for type 4 lesions is recommended only when the cartilage is at least 50% intact in asymmetric ankle arthrosis. When cartilage compromise is greater than 50%, indication changes to total ankle replacement or talotibial arthrodesis.

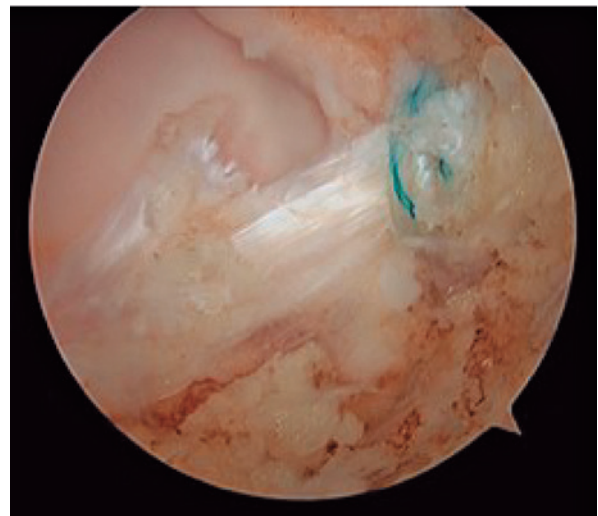


Figure 4. Arthroscopic repair of the anterior talofibular ligament.

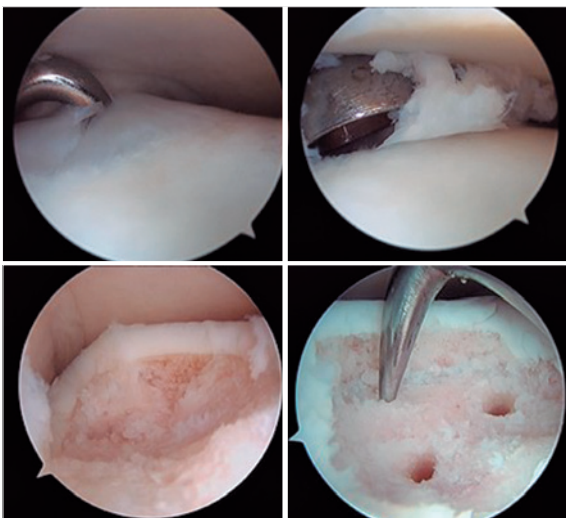


Figure 3. Arthroscopic treatment of type 1A: curettage, debridement, and microfractures.

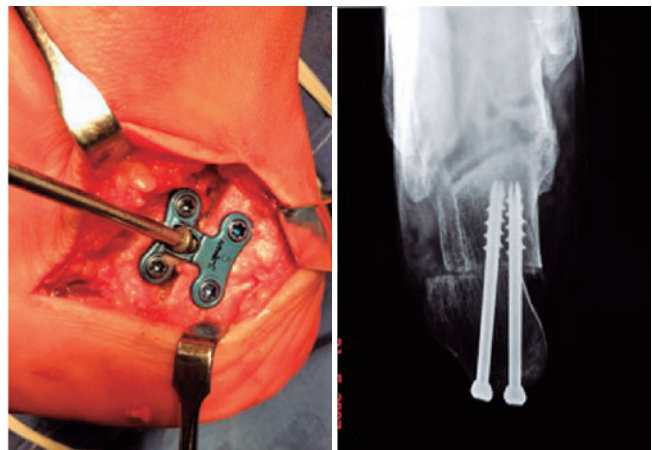


Figure 5. Valgus calcaneal osteotomy fixed with a staggered plate to the left and with two partially-threaded cannulated screws compressing the osteotomy to the right.

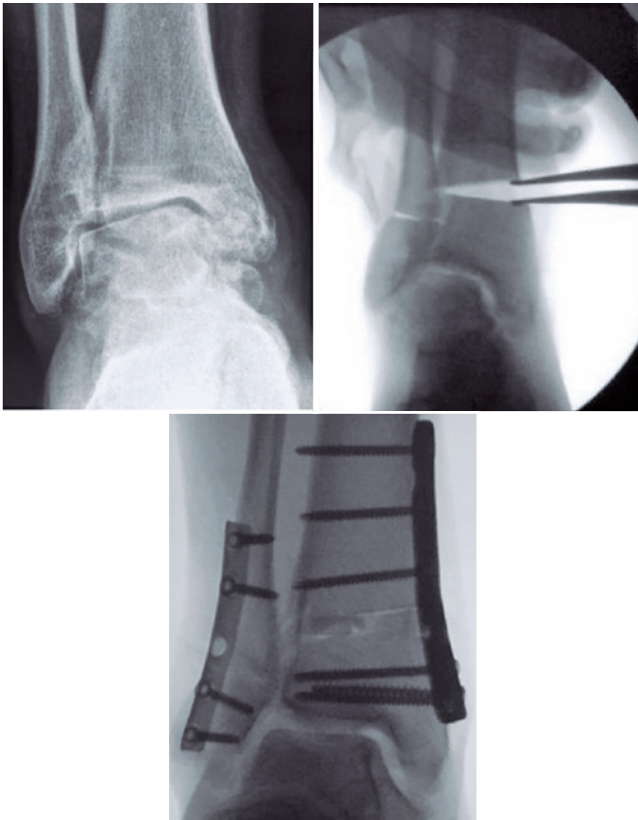


Figure 6. Varus deformity treated with supramalleolar opening wedge osteotomy.


With regard to postoperative rehabilitation, it is indicated to start self-assisted early passive mobilization as soon as pain and edema allow so. Partial support is initiated after from 2-4 weeks in lesions smaller than 10mm, and after 6 weeks in those larger than 10mm or if the lesion is located anteriorly. In patients subjected to concomitant procedures, such as supramalleolar or calcaneal osteotomy and/or ligament repair, support is initiated after 6 weeks. Recreational activities are limited for 3-6 months, and competitive activities for 6-12 months.

In the case of concomitant procedures, such as supramalleolar or calcaneal osteotomy and/or ligament repair, patients are immobilized for 3 weeks with orthopedic walker boots or plaster cast, without load, then partial support with assistive walkers for 3 weeks, and beginning of complete support after 6 weeks. Recreational activities are limited for 3-6 months, and competitive activities for 6-12 months.

Conclusion

The classification presented here allows us to provide a guide for the treatment of OCLs, according to their morphology, extension, and depth, along with their association with ankle instabilities and disorders in loading axes, which enables for the physician to indicate a specific treatment for each type and subtype of this multifactorial disease.

Yet, we still need to assess the reproducibility of our classification in the treatment of OCLs, with the conduction of a future prospective study.

Authors' contributions: Each author contributed individually and significantly to the development of this article: JB *(<https://orcid.org/0000-0003-0910-4140>) conceived and planned the activities that led to the study, performed the surgeries, bibliographic review and clinical examination; GA *(<https://orcid.org/0000-0003-4767-5489>) performed the surgeries, clinical examination and participated in the review process; GJ *(<https://orcid.org/0000-0001-9998-190X>) formed the surgeries, formatting of the article; LC *(<https://orcid.org/0000-0003-1187-0864>) participated in the review process, data collection, performed the surgeries; LL *(<https://orcid.org/0000-0001-9094-7609>) performed the surgeries and formatting of the article. All authors read and approved the final manuscript. *ORCID (Open Researcher and Contributor ID) .

References

- Batista JP, Duarte-Pereira HM., van Dijk CN. Del Vecchio JJ. Posterior arthroscopic treatment of ankle osteochondral lesions: technical note. *J ISAKOS: Joint Disord Orthop Sports Med.* 2020; 5(2):104.
- Stone JW. Osteochondral lesions of the talar dome. *J Am Acad Orthop Surg.* 1996;4(2):63-73.
- van Dijk CN, Scholten PE, Krips R. A 2-portal endoscopic approach for diagnosis and treatment of posterior ankle pathology. *Arthroscopy.* 2000;16(8):871-6.
- O'Loughlin PF, Heyworth BE, Kennedy JG. Current concepts in the diagnosis and treatment of osteochondral lesions of the ankle. *Am J Sports Med.* 2010;38(2):392-404.
- van Bergen CJA, Baur OL, Murawski CD, Spennacchio P, Carreira DS, Kearns SR, et al. Diagnosis: History, Physical Examination, Imaging, and Arthroscopy: Proceedings of the International Consensus Meeting on Cartilage Repair of the Ankle. *Foot Ankle Int.* 2018;39(1 suppl):3S-8S.
- Berndt AL, Harty M. Transchondral fractures (osteochondritis dissecans) of the talus. *J Bone Joint Surg Am.* 1959;41:988-1020.
- Lüsse S, Claassen H, Gehrke T, Hassenpflug J, Schünke M, Heller M, et al. Evaluation of water content by spatially resolved transverse relaxation times of human articular cartilage. *Magn Reson Imaging.* 2000;18(4):423-30.

8. Hepple S, Winson IG, Glew D. Osteochondral lesions of the talus: a revised classification. *Foot Ankle Int.* 1999;20(12):789-93.
9. Resnick D, Niwayama G, Coutts RD. Subchondral cysts (geodes) in arthritic disorders: pathologic and radiographic appearance of the hip joint. *AJR Am J Roentgenol.* 1977;128(5):799-806.
10. Rhaney K, Lamb DW. The cysts of osteoarthritis of the hip; a radiological and pathological study. *J Bone Joint Surg Br.* 1955; 37(4):663-75.
11. Ferkel RD, Sgaglione NA, Del Pizzo W. Arthroscopic treatment of osteochondral lesions of the talus: technique and results. *Orthop Trans.* 1990;14:172-3.
12. Ferkel RD, Zanotti RM, Komenda GA, Sgaglione NA, Cheng MS, Applegate GR, et al. Arthroscopic treatment of chronic osteochondral lesions of the talus: long-term results. *Am J Sports Med.* 2008;36(9):1750-62.
13. Taranow WS, Bisignani GA, Towers JD, Conti SF. Retrograde drilling of osteochondral lesions of the medial talar dome. *Foot Ankle Int.* 1999;20(8):474-80.
14. Mintz DN, Tashjian GS, Connell DA, Deland JT, O'Malley M, Potter HG. Osteochondral lesions of the talus: a new magnetic resonance grading system with arthroscopic correlation. *Arthroscopy.* 2003; 19(4):353-9.
15. Anderson IF, Crichton KJ, Grattan-Smith T, Cooper RA, Brazier D. Osteochondral fractures of the dome of the talus. *J Bone Joint Surg Am.* 1989;71(8):1143-52.
16. Elias I, Jung JW, Raikin SM, Schweitzer MW, Carrino JA, Morrison WB. Osteochondral lesions of the talus: change in MRI findings over time in talar lesions without operative intervention and implications for staging systems. *Foot Ankle Int.* 2006;27(3):157-66.
17. Elias I, Zoga AC, Morrison WB, Besser MP, Schweitzer ME, Raikin SM. Osteochondral lesions of the talus: localization and morphologic data from 424 patients using a novel anatomical grid scheme. *Foot Ankle Int.* 2007;28(2):154-61.
18. Batista J. *Artroscopia de tobillo. Bases y fundamentos.* 1ed. Ciudad Autónoma de Buenos Aires: Librofutbol; 2017.
19. Posadzy M, Desimpel J, Vanhoenacker F. Staging of Osteochondral Lesions of the Talus: MRI and Cone Beam CT. *J Belg Soc Radiol.* 2017;101(Suppl 2):1.
20. De Smet E, De Praeter G, Verstraete KL, Wouters K, De Beuckeleer L, Vanhoenacker FM. Direct comparison of conventional radiography and cone-beam CT in small bone and joint trauma. *Skeletal Radiol.* 2015;44(8):1111-7.
21. Pritsch M, Horoshovski H, Farine I. Arthroscopic treatment of osteochondral lesions of the talus. *J Bone Joint Surg Am.* 1986; 68(6):862-5.
22. Savage-Elliott I, Ross KA, Smyth NA, Murawski CD, Kennedy JG. Osteochondral lesions of the talus: a current concepts review and evidence-based treatment paradigm. *Foot Ankle Spec.* 2014;7(5):414-22.
23. Becher C, Thermann H. Results of microfracture in the treatment of articular cartilage defects of the talus. *Foot Ankle Int.* 2005; 26(8):583-9.
24. Schneider TE, Karakudi S. Matrix-induced autologous chondrocyte implantation (MACI) grafting for osteochondral lesions of the talus. *Foot Ankle Int.* 2009;30(9):810-4.