

## Original Article

# Mobilization protocol and early postoperative weight-bearing in transyndesmal ankle fractures

Diego Yearson<sup>1,2,3</sup> , Ignacio Melendez<sup>1,2</sup> , Federico Anain<sup>1,2</sup> , Santiago Siniscalchi<sup>1,2</sup> , Juan Drago<sup>1,2,3</sup> 

1. Sanatorio de la Trinidad Ramos Mejía, Ramos Mejía, Buenos Aires, Argentina.

2. Sanatorio Trinidad Palermo, CABA, Buenos Aires, Argentina.

3. CLIMBA, CABA, Buenos Aires, Argentina.

## Abstract

**Objective:** To disseminate a rehabilitation protocol with early mobilization and ambulation, with no external supports, reducing the time until full weight-bearing and providing greater postoperative comfort.

**Methods:** We prospectively assessed a series of 68 patients, with level of evidence IV, mean age of 33.3 years. We performed open reduction with ankle lateral approach (Kocher) and internal fixation with an interfragmentary compression screw and a one-third locked tubular plate for neutralization. All patients were subjected to a rehabilitation protocol with early mobilization and weight-bearing.

**Results:** No fracture displacements were observed on the postoperative radiographic controls, neither loosening nor ruptures of implants. There was no need to change rehabilitation guidelines either due to pain or to other subjective limitation.

**Conclusion:** We can state that early joint mobilization and controlled progressive support, with appropriate osteosynthesis, resulting in an early return to everyday activities, both work and sports ones.

**Level of Evidence IV; Therapeutic Studies; Case Series.**

**Keywords:** Fractures, bone; Ankle; Range of motion, articular; Early ambulation; Electrophoretic mobility shift assay.

## Introduction

Ankle fractures compromise both bone and ligament structures. According to the AO classification, which is based on that of Weber, these fractures belong to the 44 A, B or C group, according to the level at which fibula fracture is located with respect to syndesmosis; they are also subclassified into 1, 2 or 3, according to the involvement of one, two, or three malleoli or their equivalent ligaments. We have studied the 44-B1 group (transyndesmal fibula fracture with no medial or posterior involvement), the most frequent subtype among ankle fractures<sup>(1)</sup>. These fractures are mostly stable and can be conservatively treated with cast or plastic

immobilizers (Figure 1) or treated with surgery. Conservative treatment is indicated in non-displaced fractures, in older patients<sup>(2,3)</sup> or with limited ambulation<sup>(4)</sup>, in those with neurological or severe peripheral vascular disease, and in bedridden patients. Poor integumentary status may be also a conditioning in the choice for conservative treatment. Surgical indications are fractures with a displacement greater than 2mm in young patients, whether athletes or workers. One of the advantages of surgical treatment is postoperative rehabilitation protocol, with joint mobilization and early progressive weight-bearing, which allows for an earlier return to labor and sports activities.

Study performed at the Sanatorio de la Trinidad de Ramos Mejía, Ramos Mejía, Buenos Aires, Argentina.

**Correspondence:** Diego Javier Yearson. Calle Jose Antonio Maure, 2021, CABA - 1426, Buenos Aires, Argentina. **E-mail:** [dyearson@intramed.net](mailto:dyearson@intramed.net). **Conflicts of interest:** none. **Source of funding:** none. **Date received:** May 01, 2021. **Date accepted:** June 29, 2021. **Online:** August 31, 2021.

How to cite this article: Yearson D, Melendez I, Anain F, Siniscalchi S, Drago J. Mobilization protocol and early postoperative weight-bearing in transyndesmal ankle fractures. *J Foot Ankle*. 2021;15(2):100-4.

Classically, patients with this type of fractures are allowed to initiate weight-bearing after the fourth postoperative week, starting with two crutches and bearing from 30 to 50% of body weight<sup>(5,6)</sup>. Between the fifth and the sixth postoperative week, one crutch is removed (maintaining the one on the opposite side from the fractured ankle), which means loading 75% of body weight on the operated ankle, and full weight-bearing is achieved between the seventh and the eighth postoperative week.

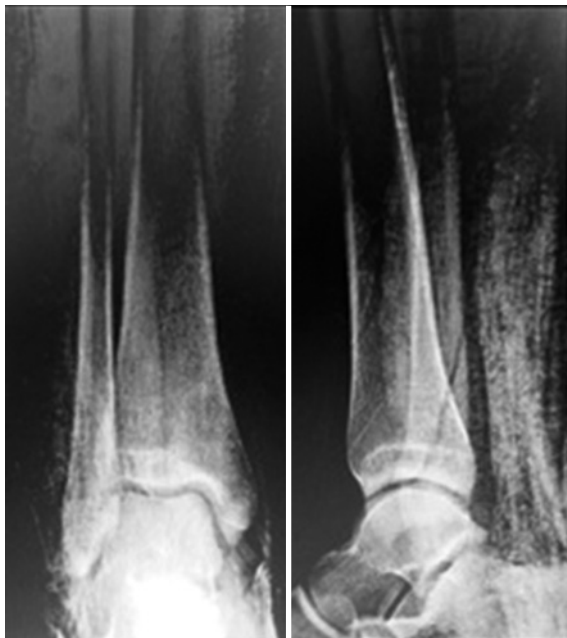Currently, fracture rehabilitation protocols tend to shorten recovery times so that patients can make an early return to their activities. The 44-B1 group is not only the most frequent type of ankle fracture but also predominates in young patients or athletes<sup>(7)</sup>. This reason, as well the scarce literature on the topic, led us to develop a new guideline on rehabilitation that meets the expectations of this group of patients.

The aim of this presentation is to disseminate a postoperative rehabilitation protocol in 44-B1 fractures, which reduces the usual time to initiate weight-bearing without external support in the postoperative period.

## Methods

This study was approved by the institutional ethics committee and was conducted by our team of specialists in this disease with specific selection criteria and pre-established algorithms, following identical parameters.

The project was performed under the ethical standards that regulate investigation in humans, according to the National Personal Data Protection Act No. 25326 (Habeas Data Act) and Declaration of Helsinki in its latest version.



**Figure 1.** Image showing a 44-B1 fracture with no displacement that could be conservatively treated.

We retrospectively assessed a series of cases with level of evidence IV.

All operated patients were in a good general state, with no integumentary complications that could delay or complicate surgical indication. Exclusion criteria were patients older than 65 years of age, with limited ambulation or bedridden, patients with multiple trauma who could not be subjected to the proposed protocol due to other injuries, severe neurological diseases, osteoporosis, comminuted fractures that made it impossible to perform the osteosynthesis established in the protocol, and fractures not classified into the 44-B1 type (Table 1).

From November 2015 to November 2018, we operated on 68 patients with 44-B1 ankle fractures (49 men and 19 women). Surgical indications were fibula fractures with a displacement greater than 2mm and those in young patients, whether athletes or workers, with no deltoid ligament involvement.

The surgical technique used was open reduction with ankle lateral approach (Kocher) and internal fixation with an interfragmentary compression screw measuring

3.5mm in diameter and a one-third locked tubular plate for neutralization<sup>(8,9)</sup> (Figure 2). We used locked implants in all assessed patients included in the protocol, who systematically received 2 proximal locked screws and 2 distal locked screws<sup>(10-12)</sup>. Post-surgical immobilization was not used in any case, only wound coverage and elastic bandage.

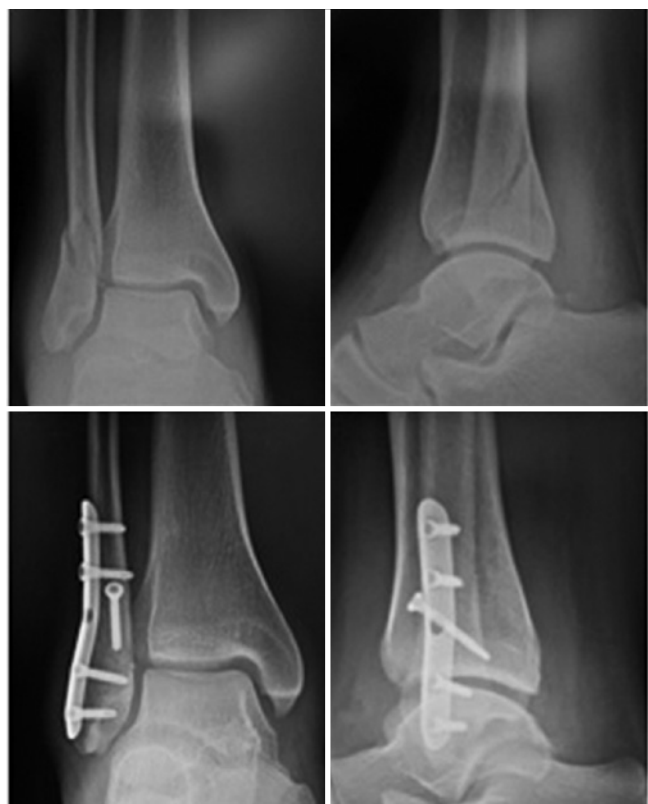## Postoperative management (Table 2):

Day 7: initial postoperative follow-up. Wound healing. Household ambulation was allowed with crutches, without support. Ankle flexion and extension exercises were indicated according to patient's tolerance, with active and passive mobilization with elastic band if possible.

Day 15: removal of stitches, control radiography. Weight-bearing was initiated with two crutches according to tolerance (up to 50% of body weight). Ankle movements were intensified, including forced inversion and eversion. At this point, patients were expected to have at least 50% of mobility with regard to the contralateral ankle.

**Table 1.** Inclusion and exclusion criteria for patient selection

|                    |  |
|--------------------|--|
| Inclusion criteria | >16 years old  |
|                    | < 65 years old   |
|                    | 44-B1 fractures  |
| Exclusion criteria | <16 years old  |
|                    | >65 years old  |
|                    | Limited ambulation or bedridden                          |
|                    | Severe neurological diseases                             |
|                    | Multiple trauma or impossibility to conduct the protocol |
|                    | Osteoporosis   |
|                    | Comminuted fractures                                     |



**Figure 2.** Treatment of transyndesmal fibula fractures with locked plates.

**Table 2.** Rehabilitation guidelines during the first 4 postoperative weeks

| Week | Mobilization (%) | Support (%) |
|------|------------------|-------------|
| 1    | No tolerance     | 0           |
| 2    | >50              | 50          |
| 3    | >70              | 75          |
| 4    | >90              | 100         |

Day 21: weight-bearing progressed using a single crutch contralateral to the fractured ankle (up to 75% of the body weight). Kinesiological rehabilitation was started combining magnet therapy, ultrasound (US), and stationary bicycle; moreover, there

was an emphasis on improving ankle dorsiflexion up to at least 70% of normal range. Exercises for evolver strengthening were initiated.

Day 28: crutches were removed, prior control radiography. Proprioceptive exercises on unstable surfaces are allowed, with kinesiological support. Expected mobility in this stage was around 90%.

After the fourth week, proprioceptive exercises and muscular strengthening were intensified with kinesiological assistance. Jogging was allowed after the third month, and return to high-impact sports activities was allowed from the 5th to the 6th month.

Control radiographies were obtained at the immediate postoperative period and at days 15, 30, 60, and 90.

## Results

In the 68 patients treated according to our protocol, we confirmed radiological signs of complete fibula union at 4 weeks in all cases, and no displacement or changes in fracture axis were observed in postoperative radiographic controls<sup>(13)</sup>; similarly, there were no cases of loosening or rupture of hardware. Four patients (5.88%) presented with focal wound dehiscence<sup>(14)</sup>, without exposure of hardware, which in all cases was resolved with local treatment by successive dressings and oral antibiotic. No patient required a new intervention. One should bear in mind that these complications were not related to arthrosis in the long term<sup>(15)</sup>.

Patients returned to their everyday and work activities (from home), with weight-bearing of 50% of body weight, at the end of the second postoperative week (day 15), whereas in-person work activities started 28 days after surgery, obviously

depending on the required activity. Complete weight-bearing without crutches was reached at the end of the 4th week, and the only limiting factor was local edema.

The return to sports activities was progressive and staggered, as mentioned before, starting with kinesiological rehabilitation with increased intensity up to the 4th week. The use of stationary bicycle was initiated between the 2nd and 3rd week, according to patient's tolerance, which was interchanged with a street bicycle after the 6th week, with no reported complications. As patients improved local edema, discomfort, muscle strength, and balance, jogging, sprint, and jumping exercises were started after the 3rd month. Only one patient suffered a mild sprain with no severe complications.

## Discussion

The published literature on surgical treatment of ankle fractures usually addresses criteria, surgical approaches, indications, and isolated results, but there were no studies that present results according to variables in postoperative protocols.

In this paper, we assessed the most frequent subgroup of ankle fractures. In general, we observed a population of young active individuals whose main demand is returning to work and sports activities as early as possible<sup>(7)</sup>. No previous studies have described a specific postoperative protocol for this type of fracture.

A meta-analysis of 25 articles published in 2015 studied early mobilization and early weight-bearing as variables to consider in the treatment outcomes and concluded that none of these variables resulted in increased rates of complications.

In this series of articles, we found the study by Gul et al.<sup>(16)</sup>, conducted in 2007, the first one to propose a protocol similar to that assessed in the present study:

immediate unprotected weight-bearing as tolerated did not increase the rate of perioperative complications, and mobilization from the immediate postoperative period associated with early weight-bearing as tolerated is the safest and most effective option for early functional recovery. They were the first authors to propose progressive weight-bearing with no external protection in the entire series. Studies published later reached similar conclusions<sup>(17)</sup>.

Early mobilization and weight-bearing are associated with a faster recovery of range of motion, shortening the time for the resumption of previous activities without increasing complication rates<sup>(16)</sup>. These measures did not expedite definite return to work, but drastically improves quality of life until this return. Immobilization led to more soft tissue adhesions to implants, with hypertrophic healing, and greater postoperative edema<sup>(15,18)</sup>.

Another meta-analysis published in *The Foot* in 2019<sup>(19)</sup> on the experience of 85 health centers in Great Britain divided cases into those with early weight-bearing, which started before 3 weeks after surgery, and delayed weight-bearing, which started after this period. Only 21% of patients performed unrestricted weight-bearing, but always with some external support. Conceptually, this experience was difference from that of our proposal, since it proposes early weight-bearing at the expenses of immediate mobilization, which, we emphasize, is key to short-term functional recovery.

Some studies recommend postponing early mobilization, stating that it increases infection rates and periarticular pain<sup>(20)</sup>.

Conversely, early mobilization allows to progressively reach full weight-bearing, which is most difficult in patients who remained immobilized<sup>(18)</sup>.

Furthermore, some studies did not show significant long-term differences with regard to motility and return to sports when comparing early and delayed support. Improvement in quality of life that implies in progressively disregarding prolonged

postoperative immobilization and crutches since the second postoperative week does not have an impact on isolated functional outcomes<sup>(18)</sup>.


It is important to identify patients with comorbidities such as diabetes or smokers, since it has been demonstrated that these factors increase the likelihood of wound dehiscence or infection. In our series, we excluded patients with comorbidities that could be a determinant in outcomes.

Although the present study did not present results for a control group, we believe that its results were satisfactory, considering that patients emphasized the postoperative comfort of allowing for weight-bearing with crutches and without external supports, with early joint mobilization, and follow-up assessment did not reveal any case with signs of loosening, loss in the reduction procedure, hardware fatigue, soft tissue injury requiring a second surgical procedure.

Although the study population is acceptable, the limitation of the study is the lack of a control group subjected to a postoperative protocol with another standard with the purpose of objectively demonstrating the observed benefits. Currently, we are working with the same age group and the same type of fracture, starting with early weight-bearing 72 hours after surgery, in an attempt to further expedite the time of functional recovery. The results of this analysis will be presented when allowed by the study population and by postoperative follow-up, but we have already made conclusions on the patients assessed in the present study, which could be used as a control group in further studies.

## Conclusion

Based on the obtained results, we can state that our protocol is effective with regard to early mobilization and early support, that it is not necessary to immobilize patients, and that they can resume to their everyday activities, both work and sports ones, promptly.

**Authors' contributions:** Each author contributed individually and significantly to the development of this article: DY \*(<https://orcid.org/0000-0002-9542-6914>) Conceived and planned the activities that led to the study, performed the surgeries and bibliographic review; IM \*(<https://orcid.org/0000-0002-9452-0175>); Performed the surgeries, interpreted the results of the study and data collection; FA \*(<https://orcid.org/0000-0001-6577-8911>) Participated in the review process, clinical examination and formatting of the article; SS \*(<https://orcid.org/0000-0003-0432-8102>) Bibliographic review, interpreted the results of the study and approved the final version; JD \*(<https://orcid.org/0000-0002-5733-6766>) Participated in the review process, performed the surgeries and statistical analysis. All authors read and approved the final manuscript. \*ORCID (Open Researcher and Contributor ID). 

## References

1. Michelson JD. Ankle fractures resulting from rotational injuries. *J Am Acad Orthop Surg*. 2003;11(6):403-12.
2. Tang YH, Zeng LR, Xin DW, Yue ZS, Hu ZQ, Xu CD. [Individual choice of distal fibula internal fixation for ankle fractures in elderly]. *Zhongguo Gu Shang*. 2016;29(12):1114-8.
3. Davis AT, Israel H, Cannada LK, Bledsoe JG. A biomechanical comparison of one-third tubular plates versus periarticular plates for fixation of osteoporotic distal fibula fractures. *J Orthop Trauma*. 2013;27(9):e201-7.
4. Lorente A, Palacios P, Lorente R, Mariscal G, Barrios C, Gandía A. Orthopedic treatment and early weight-bearing for bimalleolar ankle fractures in elderly patients: Quality of life and complications. *Injury*. 2020;51(2):548-53.
5. Smeeing DP, Houwert RM, Briet JP, Kelder JC, Segers MJ, Verleisdonk EJ, et al. Weight-bearing and mobilization in the postoperative care of ankle fractures: a systematic review and meta-analysis of randomized controlled trials and cohort studies. *PLoS One*. 2015;10(2):e0118320.

6. Dehghan N, McKee MD, Jenkinson RJ, Schemitsch EH, Stas V, Nauth A, et al. Early Weightbearing and Range of Motion Versus Non-Weightbearing and Immobilization After Open Reduction and Internal Fixation of Unstable Ankle Fractures: A Randomized Controlled Trial. *J Orthop Trauma*. 2016;30(7):345-52.
7. Simanski CJ, Maegele MG, Lefering R, Lehnen DM, Kawel N, Riess P, et al. Functional treatment and early weightbearing after an ankle fracture: a prospective study. *J Orthop Trauma*. 2006;20(2):108-14.
8. Eckel TT, Glisson RR, Anand P, Parekh SG. Biomechanical comparison of 4 different lateral plate constructs for distal fibula fractures. *Foot Ankle Int*. 2013;34(11):1588-95.
9. Bariteau JT, Blankenhorn BD, Lareau CR, Paller DJ, DiGiovanni CW. Biomechanical evaluation of mini-fragment hardware for supination external rotation fractures of the distal fibula. *Foot Ankle Spec*. 2013;6(2):88-93.
10. Gentile J, Taylor BC, Chan R, French B. Clinical Comparison of Minifragment Plates Versus Conventional Semitubular Plates for Fixation of Distal Fibula Fractures. *HSS J*. 2015;11(2):148-53.
11. Hallbauer J, Klos K, Rausch S, Gräfenstein A, Wipf F, Beimel C, et al. Biomechanical comparison of a lateral polyaxial locking plate with a posterolateral polyaxial locking plate applied to the distal fibula. *Foot Ankle Surg*. 2014;20(3):180-5.
12. Milner BF, Mercer D, Firoozbakhsh K, Larsen K, Decoster TA, Miller RA. Bicortical screw fixation of distal fibula fractures with a lateral plate: an anatomic and biomechanical study of a new technique. *J Foot Ankle Surg*. 2007;46(5):341-7.
13. Smeeing DPJ, Houwert RM, Briet JP, Groenwold RHH, Lansink KWW, Leenen LPH, et al. Weight-bearing or non-weight-bearing after surgical treatment of ankle fractures: a multicenter randomized controlled trial. *Eur J Trauma Emerg Surg*. 2020;46(1):121-30.
14. Thangarajah T, Prasad PS, Narayan B. Surgical site infections following open reduction and internal fixation of ankle fractures. *Open Orthop J*. 2009;3:56-60.
15. Höiness P, Engebretsen L, Strömsøe K. The influence of perioperative soft tissue complications on the clinical outcome in surgically treated ankle fractures. *Foot Ankle Int*. 2001;22(8):642-8.
16. Gul A, Batra S, Mehmood S, Gillham N. Immediate unprotected weight-bearing of operatively treated ankle fractures. *Acta Orthop Belg*. 2007;73(3):360-5.
17. Dehghan N, McKee MD, Jenkinson RJ, Schemitsch EH, Stas V, Nauth A, et al. Early Weightbearing and Range of Motion Versus Non-Weightbearing and Immobilization After Open Reduction and Internal Fixation of Unstable Ankle Fractures: A Randomized Controlled Trial. *J Orthop Trauma*. 2016;30(7):345-52.
18. Moseley AM, Beckenkamp PR, Haas M, Herbert RD, Lin CW; EXACT Team. Rehabilitation After Immobilization for Ankle Fracture: The EXACT Randomized Clinical Trial. *JAMA*. 2015;314(13):1376-85.
19. BONE Collaborative. Weight-bearing in ankle fractures: An audit of UK practice. *Foot (Edinb)*. 2019;39:28-36.
20. Lin CW, Donkers NA, Refshauge KM, Beckenkamp PR, Khara K, Moseley AM. Rehabilitation for ankle fractures in adults. *Cochrane Database Syst Rev*. 2012;11:CD005595.