

Original Article

Ankle arthrodesis through Meary's anterolateral access

José Vicente Pansini¹ , Cesar Augusto Baggio Pereira¹ , Flamarion dos Santos Batista¹ , Kaue Sabião¹ , Cássio Hiraga¹ 

1. Hospital Universitário Evangélico Mackenzie, Curitiba, Paraná, Brazil.

Abstract

Objective: This study aimed to assess indications for surgical treatment, position of the ankle, time and rate of fusion after arthrodesis; to ascertain whether the technique provides fusion rates similar to those described in the published literature; and to quantify patients' improvement according to the AOFA and VAS scores, and patients' satisfaction using a Likert scale.

Methods: This is a clinical study with a cohort of 18 patients (9 women and 9 men) with a mean age of 49.10 years, conducted from 2006 and 2016.

Results: Post-traumatic arthrosis (88.88%), rheumatoid arthritis (5.56%), and Charcot-Marie-Tooth disease (5.56%) motivated the surgeries. Six ankles fused in an equinus position, and 12 of them in a neutral position. Five ankles fused in valgus angulation, and 13 in a neutral position. Five ankles fused in external rotation, 2 in internal rotation and 11 in a neutral position. In the postoperative period, American Orthopaedic Foot and Ankle Society (AOFAS) and visual analogue scale (VAS) scores showed an improvement of 31.6 points and 5.1 points, respectively. Regarding the Likert scale, 2 patients reported being very satisfied, 14 satisfied, and 2 partially satisfied.

Conclusion: Fusion in a 100% of cases and patients' overall satisfaction have led to the conclusion that this treatment method is appropriate to attain ankle fusion, with results similar to those found in the medical literature.

Level of Evidence IV; Therapeutic Studies; Case Series.

Keywords: Ankle; Arthrodesis; Bone screws; Orthopedic procedures.

Introduction

Severe instabilities, deformities, and arthrosis resulting from trauma or chronic diseases compromise patients' ankle and locomotion^(1,2).

The quality of life of these patients requires improving their gait, which in turn requires simultaneously neutralizing pain and aligning and stabilizing the ankle for weight-bearing. Arthrodesis is the main option of surgical treatment of these ankles⁽¹⁾. Arthroplasty is also an option, but it is not indicated or available for all patients. Being first described by Albert in 1878, it was widely used until today^(3,4). In a critical analysis of the literature, Brazilian authors stated that arthroplasty has been the best option in the country until recent years to achieve a stable, pain-free ankle⁽⁴⁾.

Since the original description, many techniques have been described for ankle arthrodesis⁽¹⁾. Different approaches and different methods of fixation portray considerable variations in fusion rates with this type of arthrodesis⁽¹⁻⁷⁾. Such outcome is a challenging task, but it may be achieved with the mate-

rials available in hospitals for orthopedic care. Furthermore, it depends on patient's clinical conditions and bone quality, position and quality of ankle fixation, and appropriate postoperative follow-up⁽¹⁻⁷⁾.

Orthopedists and patients look forward to improving gait with a pain free ankle and a stable axis. Arthrodesis fusion contemplates this desire.

Arthrodesis approach is chosen by the surgeon, but fixation requires availability of material. The 4.5 mm screws used in this study are always available in hospitals that provide orthopedic trauma care.

Since good bone contact, opening, functional positioning, and joint stabilization are essential to achieve fusion, they determine the approach of choice^(5,8-11). We believe that Meary technique allows for positioning the ankle in a neutral position and with good bone contact; furthermore, well-positioned screws are sufficient to attain fusion⁽⁴⁾. This retrospective study had the following objectives: 1- To identify the causes that motivated surgeries, as well as rates, position, and time

Study performed at the Hospital Universitário Evangélico Mackenzie, Curitiba, Paraná, Brazil.

Correspondence: José Vicente Pansini. Rua Rodolfo Senf, 673, Jardim das Américas - 81530-240, Curitiba, Paraná, Brazil. **E-mail:** pansinijv@gmail.com.

Conflicts of interest: none. **Source of funding:** none. **Date received:** September 03, 2021. **Date accepted:** October 10, 2021. **Online:** December 20, 2021.



of arthrodesis fusion; 2- To ascertain whether this technique provides fusion rates similar to those found in the published literature; 3- To quantify improvements in American Orthopaedic Foot and Ankle Society (AOFAS) and visual analog scale (VAS) scores and patients' satisfaction using a Likert scale.

Methods

This research was approved by the Research Ethics Committee, being registered on Plataforma Brasil under number: CAAE: 50802021.8.0000.0103.

This is a retrospective non-randomized study involving 18 patients diagnosed com disabling arthrosis of the ankle. Nine men and 9 women aged from 39 to 71 years underwent ankle arthrodesis by 2 senior surgeons of the Foot and Ankle Group from 2006 to 2018. Surgeries were motivated by post-traumatic arthrosis in 16 patients and of rheumatoid arthritis (RA) and Charcot Marie Tooth (CMT) disease in 2 women. The greatest deformity was severe equinus deformity in the patient with CMT sequelae. Trauma sequelae resulted from malleolar fractures (none of them involving the pilon) that progressed to arthrosis due to incomplete reduction and/or instability in the initial treatment, which was conservative in 5 patients and surgical in 11.

Data from medical records identified the causes of pain and/or deformity, time of preoperative progression, day of surgery, and time for clinical and radiographic fusions. At the end of 2019, the patients were called for an outpatient evaluation and signed an informed consent form to participate in the study approved by hospital Research Ethics Committee.

This final evaluation consisted of clinical history and physical and radiographic tests. We assessed gait and checked for varus or valgus rotational deformities of the ankle, plantigrade posture, and changes in the dorsoplantar position. Weight-bearing radiographs of front, profile, and Saltzman views showed radiographic fusion, well-centralized talus, and position of the fused ankle.

Results were assessed according to AOFAS scales for ankle and hindfoot, pain VAS, and satisfaction questionnaire with agreement criteria applying a Likert scale.

Surgical procedures were performed using the technique described by Meary *apud* Tomeno and Piat⁽¹⁰⁾ and fixed with 4.5-mm non-cannulated screws, in order to maintain the ankle in a functional position. Figure 1 portrays skin incision up to the sinus tarsi and exposure of superficial nerves.

Figure 2 depicts opening of retinaculum, isolation of extensor tendons and the vasculo-nervous beam, and cross-shaped opening of the capsule, with longitudinal and horizontal incisions at the center of the joint line in order to expose the joint.

Regularization of joint contour and opening of surfaces were performed to achieve bone contact, joint position, and centralization of the talus. Aligned in the coronal, sagittal, and horizontal planes, the ankle was provisionally stabilized with Kirschner wires. Definite fixation started with the screw from distal to proximal, under radioscopic control (Figure 3).

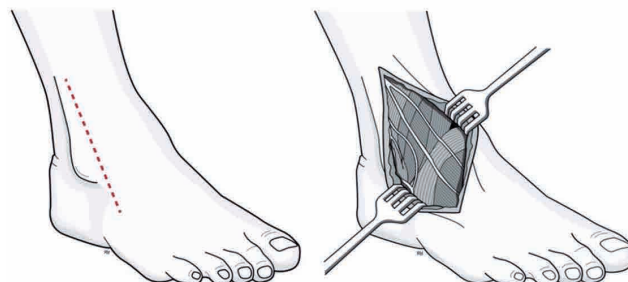


Figure 1. (A) Schematic drawing of the Meary technique and (B) Identification of superficial nerves.

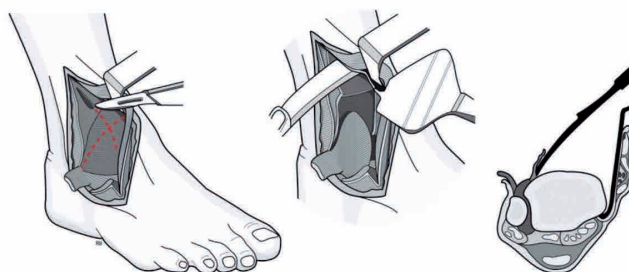


Figure 2. Incision of the capsule.

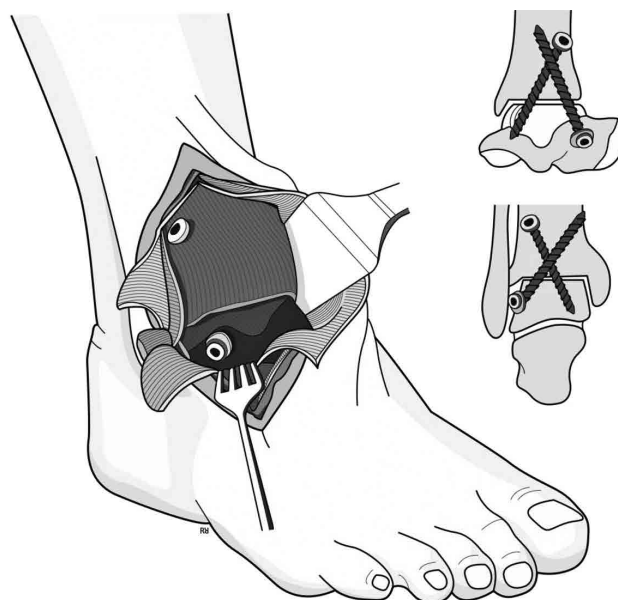


Figure 3. Position of screws for ankle fixation.

Subsequently, the wound was closed by planes, a Hemovac drain and bandage were placed, and the knee was immobilized with a plaster cast splint at 90 degrees.

Patients were discharged on the second postoperative day after dressing, removal of the drain, and cast boot with no bear weighting. Outpatient follow-up assessments were conducted every 3 weeks for 60 days, and then patients were allowed for weight-bearing with removable orthosis and crutches. Weight-bearing radiographs were performed every 6 weeks. Patients with pain-free full weight-bearing and were instructed to wear conventional shoes, with radiological controls up to fusion.

Results

Data from the study sample are reported in table 1.

Results were recorded on spreadsheets and underwent statistical calculations.

Preoperative progression was 2.6 years (1.5 to 4 years), and mean follow-up duration was 3.7 years (1.4 to 14 years).

Participants' age and sex are shown in table 2.

There was no significant difference between sexes with regard to age ($p=0.25$).

The percentages of reasons for arthrodesis are reported in table 3.

The most frequent reason was post-traumatic arthrosis.

The methods of arthrodesis fixation were the following: 2 patients with 2 screws, 15 patients with 3 screws, and 1 patient with 5 screws. One patient was treated only proximal-to-distal fixation with 3 screws.

Average time of clinical fusion (pain-free full weight-bearing) was 6.1 months after surgery (6 patients at 4 postoperative months, 5 patients at 6 months, and 7 patients at 8 months). Average time of radiographic fusion was 7.7 months de PO (2 patients at 4 postoperative months, 5 patients at 6 months, 6 at 8 months, 3 at 10 months, and 1 patient at 12 months). With regard to the position of the fused ankles, 5 fused in valgus angulation and 13 ankles in neutral position (72.22%), 6 fused in an equinus position and 12 of them in a neutral position (66.66%), 5 ankles fused in external rotation, 2 in internal rotation, and 11 in a neutral position (61.11%). A well-centralized talus was observed in all ankles.

Four patients experienced changes in dorsal sensitivity of the foot, which improved up to 12 months after surgery. Superficial infection and partial skin necrosis occurred in 2 patients, requiring only outpatient care.

AOFAS scores are shown in table 4.

There was a significant improvement in AOFAS postoperative scores ($p=0.0002$), with no significant differences between the sexes ($p=0.80$) and between ages ($p=0.83$). Mean VAS scores decreased from 7.7 points (7 to 10) preoperatively to 2.6 points (0 to 5) postoperatively, showing a significant improvement ($p=0.0002$). The Likert-scale satisfaction questionnaire showed that 2 patients were very satisfied, 14 were satisfied, 2 were partially satisfied, and none was dissatisfied. There were no complaints with regard to gait, pain, and/or ankle position. Figures 4 and 5 show pre- and postoperative radiographs of the patient with RA. Figures 6 and 7 show postoperative radiographs and pictures of the ankle of a patient with post-traumatic arthrosis.

Table 1. List of patients subjected to ankle arthrodesis

	Age	Sex	Reason	Side	Preoperative AOFAS score	Day of surgery	Postoperative AOFAS score
1	39	F	Trauma	L	35	08/17/17	66
2	41	F	Trauma	R	40	01/18/18	75
3	56	F	RA	L	50	06/25/18	80
4	59	F	Trauma	L	44	04/13/13	74
5	62	F	Trauma	R	42	10/26/17	76
6	43	F	Trauma	L	47	11/26/12	72
7	50	M	Trauma	R	48	11/03/14	70
8	45	M	Trauma	L	46	04/04/13	68
9	54	M	Trauma	L	45	07/07/17	79
10	39	M	Trauma	L	40	04/18/17	71
11	60	M	Trauma	R	44	11/12/18	74
12	47	M	Trauma	L	48	10/24/18	76
13	49	F	CMT	R	51	08/17/19	77
14	43	M	Trauma	R	49	07/13/14	76
15	25	M	Trauma	R	40	11/12/19	78
16	71	F	Trauma	R	55	05/05/06	88
17	45	M	Trauma	R	48	07/06/20	85
18	56	F	Trauma	L	52	05/03/10	85

AOFAS: American Orthopaedic Foot and Ankle Society; F: female; L: left; R: right; RA: rheumatoid arthritis; M: male; CMT: Charcot Marie Tooth disease.

Table 2. Patients' age and sex

Sex	Mean	n	Age		
			SD	Minimum	Maximum
Female	52.89	9	10.69	39	71
Male	45.33	9	9.84	25	60
Total	49.11	18	10.70	25	71

SD: standard deviation.

Table 3. Reasons for ankle arthrodesis

Reason	n	%
Trauma	16	88.89
RA	1	5.56
CMT	1	5.56
Total	18	100

RA: Rheumatoid arthritis; CMT: Charcot Marie Tooth disease.

Table 4. Pre- and postoperative AOFAS score

AOFAS score	n	Mean	Minimum	Maximum	SD
Preoperative	18	45.78	35	55	5.05
Postoperative	18	76.11	66	88	5.87

AOFAS: American Orthopaedic Foot and Ankle Society; SD: standard deviation

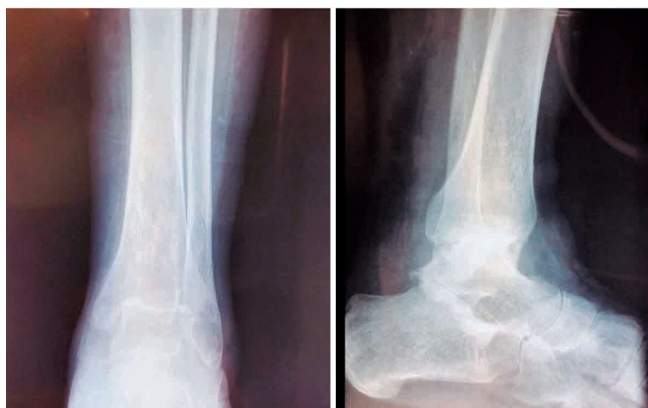

Figure 4. Preoperative image. Patient 3, who has RA.

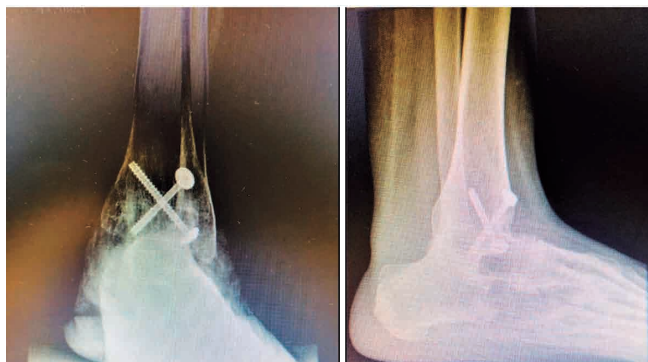

Figure 5. Postoperative image. Patient 3. Fixation with distal-to-proximal screw.

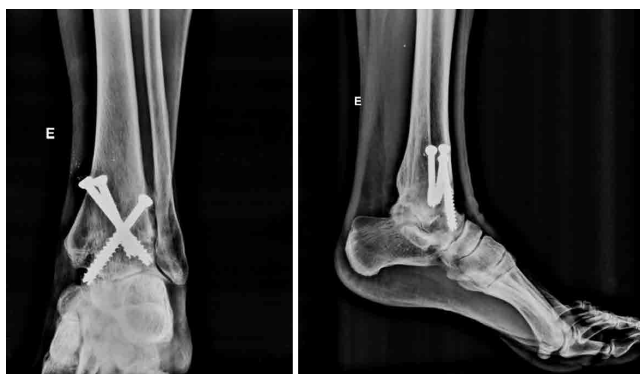

Figure 6. Postoperative 15-year follow-up. Patient 16. Fixation without distal-to-proximal screw.

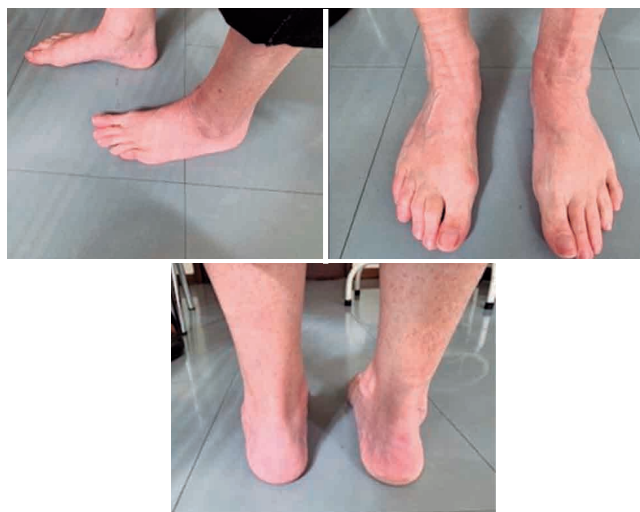

Figure 7. Patient 16. Post-traumatic arthrosis. Current pictures.

Discussion

Arthrodesis in functional position allows for a stable and pain-free ankle, with relief of pain and improvement of gait. It is indicated in cases of painful arthrosis and severe instability and/or deformities resulting from trauma or diseases that cause gait limitation, such as rheumatoid arthritis, Charcot arthropathy, and Charcot Marie Tooth disease⁽⁶⁾.

In the present series, the most frequent reason for arthrodesis was post-traumatic arthrosis (88.88%), a percentage similar to that reported by other authors^(2,4,12-15) but higher than that described by Saltzman et al.⁽¹⁶⁾. Rheumatoid arthritis and Charcot- Marie-Tooth disease were less frequently described in other studies^(2,5-7). There was no predominance of sex in the present sample, and mean age was lower for men (45.33 years) than for women (52.88 years).

Arthrodesis is not an easy procedure, and multiples factors are determining for fusion: routes of access, joint shape,

complete opening of joint surfaces, good contact between them, and final position of the fixed joint. These factors act jointly to obtain fusion^(1-8,11-19). We believe that the Meary technique, with appropriate exposure and visibility of the joint, potentiates the interaction between these factors to achieve successful fusion.

There are multiple routes of access for this arthrodesis, with similar rates of fusion and complications^(3,14). Posterior approach is used when Achilles tendon elongation is also required, but it does not allow for an easy control of joint position. Medial approach provides good exposure of the joint even without resection of the medial malleolus⁽¹⁾. The most frequently found in the published literature are anterior, lateral, and arthroscopic approaches^(1,5,10,12,13,17-20).

Lateral access allows for lateral fixation of the plate and use of fibula as a graft, if necessary^(1,12,19). Initially indicated for ankles with low levels of deformity^(1,2,17), arthroscopic approaches are currently used for ankles with great deformities^(14,15,17,18,20). Anterior approach, well tolerated by the patient and with few complications, is the most indicated to realign the ankle^(1,2,6).

There is consensus on the importance of ankle position in arthrodesis. The neutral angle (zero degree) is portrayed in the medical literature as the optimal position. This position in the coronal, sagittal, and rotational planes minimizes hyperpressure on subtalar and talonavicular joints and provides a pain-free plantigrade foot^(1,6,8,10,12). When this position is not obtained, or angles close it, functional limitations are expected. Internal rotation is little tolerated by patients, plantar flexion affects knee function, and dorsal flexion overloads the calcaneus. The varus position makes the subtalar joint unstable, and the valgus position exerts stress to the medial surface of the knee. When mispositioned, this type of arthrodesis also compromises knee and foot functions and causes gait disorders^(1,21,22).

The Meary anterolateral approach provides a visual control of the contact between bone surfaces and of the position of the ankle and of the screw from an anterolateral position in the talus to a posteromedial position in the tibia⁽¹⁰⁾. This approach optimizes the interaction between the determining factors for a successful arthrodesis that attains positions close to the optimal one. Gordon et al.⁽²⁾ also described this type of fixation, but with an anterior approach.

There are several options for fixing ankle arthrodesis, all of them with varied rates of fusion and complications, according to the published literature^(1,2,4-9,11,12,14,15,17,18).

In this series, arthrodeses were fixed with 4.5-mm screws, using 2 screws in 2 patients, 3 screws in 15 patients, and 5 screws in 1 patient. In 17 patients, 1 distal screw was placed from anterolateral in the talus to posteromedial in the tibia and the remaining screws were placed from proximal to distal. The patient who did not receive this distal-to-proximal screw received 3 proximal-to-distal screws. The method of screw fixation was chosen according to the availability in the surgical unit and their fixation capacity, as observed in daily procedures in the study hospital, which is specialized in the treatment of orthopedic trauma.

There is great variation in fusion rates for this type of arthrodesis, depending on the study population, approaches, and fixation methods^(1-6,8,12). Many studies showed fusion rates above 90%^(1,14,19,21).

Dohm et al.⁽³⁾ reported a variation from 29% to 100% within the same study, with different fixation methods performed by different surgeons. Frey et al.⁽⁷⁾ reported a rate of nonunion of 43% in patients with trauma sequelae and 33% in patients with other diseases, with no association with fixation methods. Nonunion rates of from 8.6% to 20% were reported with screw fixations^(3,17). Even using an arthroscopic approach, ankle arthrodesis fixed with screws may present a nonunion rate of up to 13%, according to Collman et al.⁽¹⁸⁾.

However, a fusion rate of 100% is not uncommon with different approaches and fixation methods, as reported by renowned authors^(2,6,12). The present series showed a fusion rate of 100% with the Meary technique and fixation with 4.5-mm screws, a rate higher than that of other publications^(1,3,5,7,13-15,17-19). Other authors also describe this rate in their series^(2,3, 5,12). It is not rare even with different approaches and fixation methods, as reported by Coughin et al.⁽¹²⁾ with a sample similar to the present one. Clinical fusion before radiographic fusion was previously described by Chanrley and also occurred in the present sample⁽⁵⁾. Our patients achieved clinical fusion at an average time of 16.1 postoperative weeks, and radiographic fusion at a mean time of 30 postoperative weeks, a time greater than that described by Gordon et al.⁽²⁾ with an open technique and screw fixation (13.3 weeks), by Myerson and Quill⁽²³⁾ (9 weeks with an arthroscopic approach and 15 with an open approach), and by Coughin et al.⁽¹²⁾ with open approach and fixation with a locked plate (24 weeks) for radiographic fusion.

Variations in the position of arthrodesis fusion were up to 10 degrees in the coronal and horizontal planes and of up to 15 degrees of equinus position in the sagittal plane.

Variations consisted of plantar flexion in 6 ankles, valgus angulation in 5, and external rotation in 5. None of the ankles fused in varus angulation. The published literature reports complications with this position^(6,18,13). Plantar flexion, valgus angulation, and external rotation were within the tolerated thresholds described by several authors^(1,12,14,15,17) and did not lead to patients' complaints of gait problems.

The most dreaded complication of ankle arthrodesis is nonunion^(1,13), which was absent in the present series. Chalayan et al.⁽¹³⁾ reported that the presence of previous subtalar arthrodesis and/or varus knee alignment represent the highest risks of nonunion. The patient with CMT disease presented the 2 previous risk factors simultaneously and attained radiographic fusion in 12 months.

Four patients experienced partial changes in dorsal sensitivity of the foot, with a gradual improvement up to 12 months after surgery. This complication is also reported by Tomeno and Piat⁽¹⁰⁾, with the same favorable outcome, and by Ogilvie-Harris et al.⁽²⁴⁾ with arthroscopic approaches, but no report of resolution. We believe that time and stress resulting

from displacing soft tissues were the causes of this complication. Superficial infection and partial skin necrosis occurred in 2 patients, requiring only outpatient care for healing. The rates of these complications were similar to those found in other reports^(1,4,6,7,12,14,19).


The mean AOFAS score for the hindfoot was 46 points (33 to 58) preoperatively and 74.6 points (59 to 90 points) postoperatively, with an increase of 32.6 points. The mean VAS score was 7.7 points (7-10) preoperatively and 2.9 points (0 to 10) postoperatively, with a decrease of 4.8 points, similar to that described in other studies^(12,19).

The Likert-scale questionnaire confirmed patients' satisfactions, although many complaint about postoperative quality of life, according to the published literature^(1,25). The patients in the present study did not complain of pain or functional

limitation, probably because loss of mobility is compensated by pain relief and full weight-bearing on the ankle, as reported in the medical literature^(13,26).

Conclusion

Fusion in 100% of cases and patients' overall satisfaction have led to the conclusion that the Meary technique and screw fixation are appropriate to attain ankle fusion, with results similar to those found in the medical literature. The Meary technique provides excellent exposure of joint and visual control of fixation, in addition to optimizing arthrodesis fusion. We believe that this is an efficient, low-cost, reproducible method that can be performed in hospitals providing orthopedic trauma care.

Authors' contributions: Each author contributed individually and significantly to the development of this article: JVP *(<https://orcid.org/0000-0003-1445-946>) Conceived and planned the activities that led to the study, performed the surgeries, evaluated and interpreted the results of the study, wrote the article, participated in the review process and approved the final version; CABP *(<https://orcid.org/0000-0003-0401-1164>) Conceived and planned the activities that led to the study, performed the surgeries, evaluated and interpreted the results of the study, wrote the article, participated in the review process and approved the final version; FSB *(<https://orcid.org/0000-0001-6073-8523>) Conceived and planned the activities that led to the study, participated in the review process and approved the final version; KS *(<https://orcid.org/0000-0003-2371-7680>) Assisted in surgeries, wrote the article, evaluated and interpreted the results of the study, approved the final version; CH *(<https://orcid.org/0000-0002-6697-8197>) Assisted in surgeries, evaluated and interpreted the results of the study, approved the final version. All authors read and approved the final manuscript. *ORCID (Open Researcher and Contributor ID) 

References

- Nihal A, Gellman RE, Embil JM, Trepman E. Ankle arthrodesis. *Foot Ankle Surg.* 2008;14(1):1-10.
- Gordon D, Zicker R, Cullen N, Singh D. Open ankle arthrodeses via an anterior approach. *Foot Ankle Int.* 2013;34(3):386-91.
- Dohm M, Purdy BA, Benjamin J. Primary union of ankle arthrodesis: review of a single institution/multiple surgeon experience. *Foot Ankle Int.* 1994;15(6):293-6.
- Mercadante MT, Santin RAL, Ferreira RC. Overview of the surgical techniques for ankle arthrodesis. *Rev Bras Ortop.* 2000;35(6):187-93.
- Charnley J. Compression arthrodesis of the ankle and shoulder. *J Bone Joint Surg Br.* 1951;33B(2):180-91.
- Hendrickx RP, Stufkens SA, de Bruijn EE, Sierevelt IN, van Dijk CN, Kerkhoffs GM. Medium- to long-term outcome of ankle arthrodesis. *Foot Ankle Int.* 2011;32(10):940-7.
- Frey C, Halikus NM, Vu-Rose T, Ebramzadeh E. A review of ankle arthrodesis: predisposing factors to nonunion. *Foot Ankle Int.* 1994;15(11):581-4.
- Morgan CD, Henke JA, Bailey RW, Kaufer H. Long-term results of tibiotalar arthrodesis. *J Bone Joint Surg Am.* 1985;67(4):546-50.
- Kennedy JG, Hodgkins CW, Brodsky A, Bohne WH. Outcomes after standardized screw fixation technique of ankle arthrodesis. *Clin Orthop Relat Res.* 2006;447:112-8.
- Tomeno B, Piat C. Arthrodèse tibio-astragaliennne. Techniques chirurgicales-Orthopédie-traumatologie. *Encycl Méd Chir (Elsevier SAS, Paris);* 1990.
- Glick JM, Morgan CD, Myerson MS, Sampson TG, Mann JA. Ankle arthrodesis using an arthroscopic method: long-term follow-up of 34 cases. *Arthroscopy.* 1996;12(4):428-34.
- Coughlin MJ, Nery C, Baumfeld D, Jastifer J. Tibiotalar compression Arthrodesis using a lateral locking plate. *Rev Bras Ortop.* 2015; 47(5):611-5.
- Chalayan O, Wang B, Blankenhorn B, Jackson JB 3rd, Beals T, Nickisch F, et al. Factors Affecting the Outcomes of Uncomplicated Primary Open Ankle Arthrodesis. *Foot Ankle Int.* 2015;36(10):1170-9.
- Townshend D, Di Silvestro M, Krause F, Penner M, Younger A, Glazebrook M, et al. Arthroscopic versus open ankle arthrodesis: a multicenter comparative case series. *J Bone Joint Surg Am.* 2013;95(2):98-102.
- Goetzmann T, Molé D, Jullion S, Roche O, Sirveaux F, Jacquot A. Influence of fixation with two vs. three screws on union of arthroscopic tibio-talar arthrodesis: Comparative radiographic study of 111 cases. *Orthop Traumatol Surg Res.* 2016;102(5):651-6.
- Saltzman CL, Salamon ML, Blanchard GM, Huff T, Hayes A, Buckwalter JA, et al. Epidemiology of ankle arthritis: report of a consecutive series of 639 patients from a tertiary orthopaedic center. *Iowa Orthop J.* 2005;25:44-6.
- Abicht BP, Roukis TS. Incidence of nonunion after isolated arthroscopic ankle arthrodesis. *Arthroscopy.* 2013;29(5):949-54.
- Collman DR, Kaas MH, Schuberth JM. Arthroscopic ankle arthrodesis: factors influencing union in 39 consecutive patients. *Foot Ankle Int.* 2006;27(12):1079-85.

19. Kim JG, Ha DJ, Gwak HC, Kim CW, Kim JH, Lee SJ, et al. Ankle Arthrodesis: A Comparison of Anterior Approach and Transfibular Approach. *Clin Orthop Surg*. 2018;10(3):368-73.
20. Gougoulas NE, Agathangelidis FG, Parsons SW. Arthroscopic ankle arthrodesis. *Foot Ankle Int*. 2007;28(6):695-706.
21. Mann RA, Rongstad KM. Arthrodesis of the ankle: a critical analysis. *Foot Ankle Int*. 1998;19(1):3-9.
22. Buck P, Morrey BF, Chao EY. The optimum position of arthrodesis of the ankle. A gait study of the knee and ankle. *J Bone Joint Surg Am*. 1987;69(7):1052-62.
23. Myerson MS, Quill G. Ankle arthrodesis. A comparison of an arthroscopic and an open method of treatment. *Clin Orthop Relat Res*. 1991;(268):84-95.
24. Ogilvie-Harris DJ, Lieberman I, Fitialos D. Arthroscopically assisted arthrodesis for osteoarthrotic ankles. *J Bone Joint Surg Am*. 1993; 75(8):1167-74.
25. Coester LM, Saltzman CL, Leupold J, Pontarelli W. Long-term results following ankle arthrodesis for post-traumatic arthritis. *J Bone Joint Surg Am*. 2001;83(2):219-28.
26. Waly FJ, Yeo EMN, Wing KJ, Penner MJ, Veljkovic A, Younger ASE. Relationship of Preoperative Patient-Reported Outcome Measures (PROMs) to Postoperative Success in End-Stage Ankle Arthritis. *Foot Ankle Int*. 2020;41(3):253-8.