

Case Report

Novel management of sizeable calcaneal UBC with autograft and allograft amalgamation: a case report and review of literature

Tapas Mohanty¹, Sameer Panchal¹, Stavan Amin¹, Sangeet Gawhale¹, Pritam Talukder¹

1. Grant Medical College and JJ Group of Hospitals, Mumbai, Maharashtra, India.

Abstract

Calcaneal unicameral bone cyst (UBC) is uncommon benign tumor that can be managed either conservatively or with different surgical interventions described in the literature. However, surgical intervention is usually preferred when the lesion is an active UBC significant in size, as there is the risk of pathological fracture due to thin bone, especially in load-bearing bones like the calcaneus. We report a case of calcaneal UBC considerable in size managed by open curettage and graft reconstruction using a combination of autograft and allograft in a 30-year-old male at two-years follow-up.

Level of Evidence IV; Therapeutic Studies; Case Report.

Keywords: Bone cysts; Calcaneus; Radiography; Adult.

Introduction

Unicameral bone cyst (UBC), also known as a solitary or simple bone cyst, is a cavity filled with a yellow-colored fluid and radiographically seen as a mildly expansile, lytic thin-walled lesion without periosteal reaction. It is considered benign since it does not spread beyond the bone. UBCs are more common in males. Most UBCs do not cause any symptoms and are discovered as incidental findings on radiographs or computed tomography (CT) scans for other reasons. However, large lesions can cause nearby areas of bone to thin, resulting in a fracture and causing pain. Most cases of UBCs present with pathological fractures due to thinning of bone. Less commonly, a patient may notice a painless bump if the cyst has caused the bone to enlarge in a local area. UBCs can be managed conservatively or by surgical interventions⁽¹⁾.

Case description

We report a case of a 30-year-old salesman with a Body Mass Index (BMI) of 35. He attended our emergency room with left ankle pain and swelling for the last three days. He had a history of blunt trauma to the left talocrural region

following a fall from a bike. Clinical evaluation revealed significant swelling around the left ankle, tenderness around the calcaneum region, and inability to fully weight bear, giving an impression of bony injury. Surprisingly, the radiographs were not suggestive of any fracture, but an incidental finding of lytic, expansile lesion, noticed in the calcaneus body (Figure 1A-B). CTs of the left foot and ankle were advised to investigate further, suggesting a well-defined expansile lytic lesion with lobulated non-sclerotic margins measuring 4.4x 3.2x 2.4cm in the anterior part of calcaneum (Figure 2A-B). There was thinning of medial cortex of calcaneum without cortical breach. Different diagnoses of simple bone cyst, giant cell tumour (GCT), and aneurysmal bone cyst (ABC) were given, and magnetic resonance imaging (MRI) was indicated for further evaluation. MRI of the left foot revealed a well-defined, expansile, sub-articular, eccentrically located lesion in the calcaneum body with minimal blood fluid levels at the subtalar joint (Figure 3A-B). A few internal septations were noted within the lesion; however, no obvious enhancement was seen within the mass. These findings on MRI were corroborative of features of ABC, unlikely of GCT due to the absence of soft tissue within. CT-guided biopsy was performed before any intervention confirming the diagnosis of calcaneal UBC.

Study performed at the Grant Medical College and JJ Group of Hospitals, Mumbai, Maharashtra, India.

Correspondence: Tapas Mohanty. Room No 743, 300 Residents Hostel, JJ Hospital Campus, Mumbai, India, 400008. **E-mail:** tapas.ku.mohanty@gmail.com.

Conflicts of interest: none. **Source of funding:** none. **Date received:** February 04, 2022. **Date accepted:** May 19, 2022. **Online:** August 31, 2022.



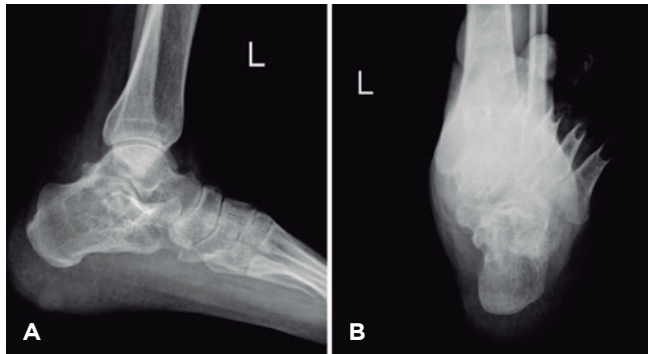


Figure 1. Plain radiographs. A) Lateral view. B) Harris axial view suggest expansile, lobulated, lytic lesion in the body of calcaneum encroaching subtalar joint.

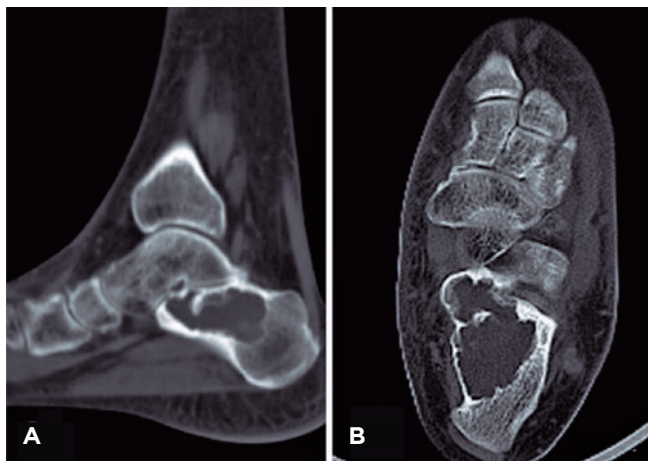


Figure 2. Computed tomography (CT scan). A) Sagittal section. B) Axial section suggestive of eccentric, expansile, lytic lesion with thinned out medial cortex and about to breach subtalar joint.

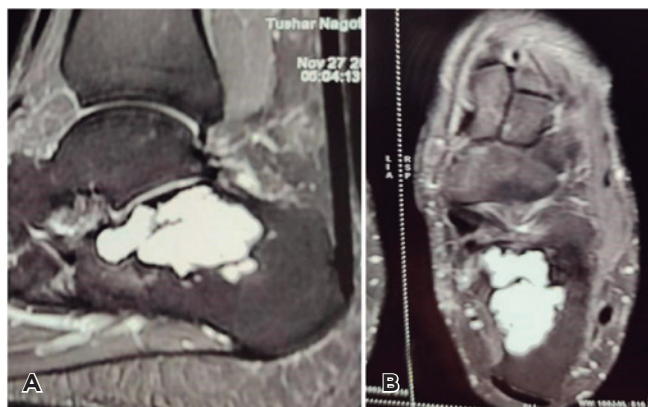


Figure 3. MRI T2 weighted image. A) Sagittal. B) Axial sections suggest well-defined, expansile, sub-articular, eccentrically hyperintense lesion in the body of calcaneum with minimal blood fluid levels at subtalar joint.

Open curettage and bone graft augmentation were planned to ameliorate the patient's symptoms due to poor response to rest, immobilization and analgesics.

The lesion was approached using a standard 'L' shaped incision taken over the lateral aspect of the calcaneus, passing behind the lateral malleolus and then curving just distal to it, extended up to the base of the 5th metatarsal. The incision was then deep to create a full-thickness flap containing the peroneal tendons and the sural nerve and held in place to expose the lateral aspect of the calcaneus. Corticotomy on the lateral wall was performed, and curettage was done to remove the necrotic tissue of the cyst (Figure 4A). Samples collected during curettage were sent for culture and histopathological examination. Debridement and thorough betadine wash were given throughout the cavity. The bone defect created after curettage was large enough which was then filled with amalgamation of cancellous autograft harvested from the iliac crest and cancellous allograft (lyophilised and irradiated) (Figure 4B-C). The wound was then closed in layers with 3-0 ethilon by Allgöwer-Donati suture technique (Figure 4D). Post-operatively, below knee slab was given for three weeks, and nil weight-bearing mobilization with a walker started in the immediate post-op period. Physiotherapy with ankle range of motion (ROM) started after three weeks, and full weight-bearing started after eight weeks.

Histopathological evaluation sent intra-operatively revealed necrotic bone and muscular tissue with no evidence of malignant cells. On sequential follow-up at one, three, six, twelve months, and two years functional ankle ROM and around 5

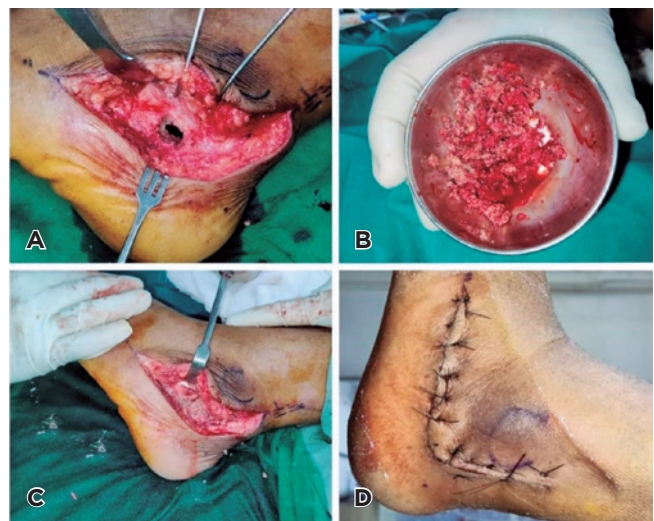


Figure 4. Intra-operative clinical pictures. A) Curettage and decompression with lateral wall corticotomy through a standard lateral approach. B) Mixture of cancellous autograft harvested from iliac crest and cancellous allograft procured from lyophilised, irradiated bone graft. C) Packing and impaction of the cavity with bone graft. D) Final closure of the wound with Allgöwer-Donati suture.

degrees of pain-free pronosupination movement were possible at subtalar joint, and radiographs were taken to assess osseointegration (Figure 5A-D). Currently, the patient is two years post-op and has no complaints and no signs of recurrence to date. The future probability of subtalar arthritis and the requirement of subtalar fusion was explained to the patient.

Discussion

The calcaneum is a relatively uncommon site for UBC occurrence, especially a large one, as was seen in this case. The risk of pathological fractures is very significant when the cyst is so large and the walls surrounding it so thin. Therefore, CT-guided biopsy is the gold standard investigation for diagnosis. Chang et al.⁽²⁾ formulated a radiological classification for UBCs based on findings on sequential follow-up radiographs and divided them into four categories – Healed, Healing with defect, persistent cyst, and recurrent cyst.

Different treatment for calcaneal UBC management have been mentioned in the literature, such as curettage with bone grafting, total/subtotal resection with bone graft, deroofing of cyst wall, curettage with combination of multiple drilling and decompression through a cannulated screw, autogenous bone marrow injected percutaneously, steroids or tricalcium phosphate ceramic injections, and curettage and autologous cancellous bone incorporation, done endoscopically⁽²⁻⁵⁾. In a case series consisting of calcaneal cysts alone, among the described techniques, curettage combined with bone grafting was reported to be the best treatment in obtaining the desired outcome in one of the largest series of calcaneal bone cysts⁽⁶⁾.

Our case presented a challenge due to the size and juxta-articular location of the lesion, particularly due to the lesion eroding into the subtalar joint. The lesion was quite large for just autograft to suffice in filling the void that would be created. To counter this problem, our operating team devised an approach of using both autograft and allograft to fill the bone void created after curettage. Our report demonstrated satisfactory results in terms of subtalar, ankle ROM, and pain-free weight-bearing, although currently proven only in the short term, in a challenging case due to the proximity of the lesion to the subtalar joint as well as the size of the lesion itself. There was minimal pronation-supination movement at subtalar joint of around 5 degrees which was painless. We considered the possible alternatives for intralesional medroxyprogesterone acetate (MPA) injection or percutaneous bone cement injection. Still, the size of the cyst made us lean toward the management method we eventually chose.

Simple bone cysts can be managed conservatively if the cyst is small and does not significantly affect the bone structural integrity. In weight-bearing bones like the calcaneus, however, operatively filling the bone defect creates a much more stable and sturdier construct and reduces the risk of pathological fractures significantly. Park et al.⁽³⁾ in a study including 23 calcaneal cysts management, compared the results of open chip allogeneic bone graft versus percutaneous injection of demineralized bone powder with autogenous bone marrow and concluded that a mixture of it injected percutaneously, is one of the less invasive procedures in the calcaneal UBC management. Minimally invasive procedure was associated with lesser postoperative morbidity, shorter hospital stay, and more compliance with the patient's unrestricted activity. A study performed by Ulici et al.⁽⁴⁾ suggested that an autogenous bone marrow injection is a safe and effective treatment method for simple bone cysts when compared with surgical management, but sometimes-repeated injections are necessary. Sung et al.⁽⁵⁾ summarized in a retrospective comparative study that open curettage with or without bone grafting is still the main treatment for simple bone cysts and superior to steroid injection in terms of healing rate. However, this technique is too aggressive, with occasional postoperative complications and recurrence after surgery. Rougraff et al.⁽⁷⁾ included 23 patients in their study, with an active UBC treated with trephination and injection of allogeneic demineralized bone matrix and autogenous bone marrow. They concluded that injecting this combination percutaneously as a minimally invasive procedure is a compelling alternative for UBCs. Complete cortical remodeling was evident radiographically by the end of one-year follow-up with five patients requiring a second injection because of cyst recurrence. All five had a clinically and radiographically quiescent cyst after a mean follow-up of 36 months. Seven of the 23 patients had incomplete healing manifested by small, persistent radiolucent areas within the original cyst. None of these cysts increased in size or resulted in pain or fracture. In a novel prospective study, Yildirim et al.⁽⁸⁾ compared and analyzed the outcome of open versus endoscopic curettage and bone grafting for simple calcaneal bone cysts treatment. The study concluded

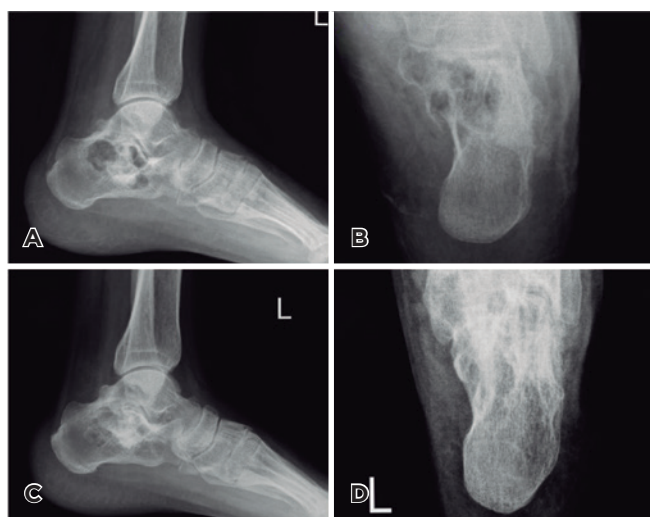


Figure 5. Immediate post-operative radiographs. A) Lateral view. B) Axial view immediately after open curettage and bone augmentation with a mixture of autograft and allograft. After two years of follow up. C) Lateral view. D) Axial view showing bony consolidation and remodeling with diminution of previous lytic lesion and evidence of early subtalar arthritis.

that endoscopic curettage and percutaneous grafting are minimalistic and effective treatments for calcaneal UBCs compared to those following open reduction. A drawback of this study was the incapacity to segregate the treatment effects of cyst puncture from those due to injection of steroids or bone marrow. To determine the role of mechanical disruption of the cyst in its resolution would require a prospective, randomized study comparing mechanical disruption of the cyst by multiple perforations with drills or awls with and without steroid injection. Monetary constraint was a convincing reason for not opting for endoscopic/percutaneous grafting procedures in our scenario.


In one of the largest series of 12 calcaneal UBCs, Glaser et al.⁽⁹⁾ compared the efficacy of MPA injection versus curettage and bone grafting. They concluded that curettage combined with bone grafting produced consistently great results in their series. However, they added that although steroid injections have given better results for UBCs at different sites, calcaneal UBCs might not be the ideal path of management.

In a systematic review of various methods of simple bone cysts treatment performed by Kadhim et al.⁽¹⁰⁾, the healing rate was higher with MPA injection than with inner wall disruption. The healing rate of UBCs managed by surgical curettage was resemblant (around 90%) irrespective of whether

either autograft or allograft was used (90%). Surgical curettage is thus an excellent treatment when combined with filling the defect with an auto or allograft. Although significant evidence supports active intervention of calcaneus UBCs, careful evaluation is required in every case to select the right treatment since no concrete evidence exists to support any treatment over the other. This is challenging due to the rarity of calcaneal bone cysts and their generally symptomless nature. Most practitioners, however, usually lean towards curettage and bone augmentation as a definitive procedure with acceptable functional outcome and least recurrence.

Conclusion

This report highlights a case of symptomatic calcaneal UBC with considerable size managed by curettage and a combination of autograft and allograft with no evidence of recurrence and complete osseointegration at two years follow-up. Amalgamation of autograft and allograft can be an acceptable option for large UBCs with cavitary defects after thorough curettage, particularly in weight-bearing areas like calcaneum. High BMI and preceding history of trauma in asymptomatic patients might present in an acute scenario with the clinical picture of fracture; such patients would require active intervention for calcaneal UBCs management.

Author's contributions: Each author contributed individually and significantly to the development of this article: TM*(<https://orcid.org/0000-0002-5167-5273>) Data collection, bibliographic review; SP *(<https://orcid.org/0000-0002-9327-9623>) Performed surgeries, formatting of the article; SA *(<https://orcid.org/0000-0002-8313-1844>) Statistical analysis, clinical examination; SG *(<https://orcid.org/0000-0003-3114-6937>) Conceived and planned the activities that led to the study, approved the final version; PT *(<https://orcid.org/0000-0001-8624-0213>) Participated in review process. All authors read and approved the final manuscript. *ORCID (Open Researcher and Contributor ID) 

References

1. Levy DM, Gross CE, Garras DN. Treatment of Unicameral Bone Cysts of the Calcaneus: A Systematic Review. *J Foot Ankle Surg.* 2015;54(4):652-6.
2. Chang CH, Stanton RP, Glutting J. Unicameral bone cysts treated by injection of bone marrow or methylprednisolone. *J Bone Joint Surg Br.* 2002;84(3):407-12.
3. Park IH, Micic ID, Jeon IH. A study of 23 unicameral bone cysts of the calcaneus: open chip allogeneic bone graft versus percutaneous injection of bone powder with autogenous bone marrow. *Foot Ankle Int.* 2008;29(2):164-70.
4. Ulici A, Balanescu R, Topor L, Barbu M. The modern treatment of the simple bone cysts. *J Med Life.* 2012;5(4):469-73.
5. Sung AD, Anderson ME, Zurakowski D, Hornicek FJ, Gebhardt MC. Unicameral bone cyst: a retrospective study of three surgical treatments. *Clin Orthop Relat Res.* 2008;466(10):2519-26.
6. Polat O, Sağlık Y, Adigüzel HE, Arikan M, Yildiz HY. Our clinical experience on calcaneal bone cysts: 36 cysts in 33 patients. *Arch Orthop Trauma Surg.* 2009;129(11):1489-94.
7. Rougraff BT, Kling TJ. Treatment of active unicameral bone cysts with percutaneous injection of demineralized bone matrix and autogenous bone marrow. *J Bone Joint Surg Am.* 2002;84(6):921-9.
8. Yildirim C, Akmaz I, Sahin O, Keklikci K. Simple calcaneal bone cysts: a pilot study comparing open versus endoscopic curettage and grafting. *J Bone Joint Surg Br.* 2011;93(12):1626-31.
9. Glaser DL, Dormans JP, Stanton RP, Davidson RS. Surgical management of calcaneal unicameral bone cysts. *Clin Orthop Relat Res.* 1999;(360):231-7.
10. Kadhim M, Thacker M, Kadhim A, Holmes L Jr. Treatment of unicameral bone cyst: systematic review and meta analysis. *J Child Orthop.* 2014;8(2):171-91.