

Original Article

Peroneal nerve injuries during anterior ankle arthroscopy

Jorge Pablo Batista¹ , Guillermo Martin Arrondo² , Germán Matías Joannas^{1,2,4} , Lucía Verónica Cangiano¹ , Rafael Baraousse³ , Leandro Casola² , Miki Dalmau-Pastor^{5,6} 

1. Centro Artroscopico Jorge Batista, CABA, Buenos Aires, Argentina.

2. Instituto Dupuytren, CABA, Buenos Aires, Argentina.

3. Centro Rossi, CABA, Buenos Aires, Argentina.

4. Instituto Barrancas, Quilmes, Buenos Aires, Argentina.

5. Human Anatomy and Embryology Unit, Department of Pathology and Experimental Therapeutics, School of Medicine and Health Sciences. University of Barcelona, Barcelona, Spain.

6. MIFAS by GRECMIP (Minimally Invasive Foot and Ankle Society), Merignac, France.

Abstract

Objective: Ankle arthroscopic surgery is considered a safe procedure with minimal risk of peripheral nerve injury. The primary objective of this study was to determine the incidence of peripheral nerve injuries during anterior ankle arthroscopy. The secondary objective was to evaluate the most frequent types and the clinical relevance of deep peroneal nerve injuries.

Methods: Patients who underwent anterior ankle arthroscopy at our institution from 2000 to 2020 were retrospectively analyzed. Those present neurological symptoms after surgery were evaluated with clinical examination and ankle ultrasonography looking for nerve injuries.

Results: Three hundred and thirty-four patients were included in the present study. There were 26 iatrogenic neurological complications (7.78%). The superficial peroneal nerve was injured in 16 cases (4.79%) and the deep peroneal nerve, in 10 cases (2.99%). Among the injuries of the deep peroneal nerve, 1.5% of cases had nerve entrapment in postoperative tissue adhesions, 0.9% presented neuromas, and 0.6% had axonotmesis. Complications were classified using the Modified Clavien-Dindo-Sink Complication Classification System: 2.1% of complications were grade I, while 0.9% were grade II.

Conclusion: Nerve injury is the most common complication related to anterior ankle arthroscopy. The deep peroneal nerve is rarely damaged during this procedure. We found that most deep peroneal nerve injuries are not clinically relevant and do not have a big impact on patient evolution during the postoperative period.

Level of Evidence II; Retrospective Study; Prognostic Studies.

Keywords: Ankle; Arthroscopy; Deep peroneal neuropathies; Peroneal nerve; Postoperative complications.

Introduction

Ankle arthroscopic surgery has been well accepted worldwide and has become an important part of orthopedic surgery. It is considered a safe procedure, with minimal risk of peripheral nerve injury. The use of arthroscopy has reduced patient hospital stay, overall costs of surgery, and the time required for patients to return to sports, work, and daily life activities. However, during this procedure, arthroscopic ins-

truments and portals are in close proximity to neurovascular structures, thus, there is a potential risk of nerve injury⁽¹⁻⁴⁾.

Nerve injury is the most common complication related to anterior ankle arthroscopic procedures^(1-3,5). Such procedures are usually performed through two classic portals: the anteromedial (AM) portal and the anterolateral (AL) portal. The superficial peroneal nerve (SPN) is one of the most frequently injured structures during ankle arthroscopy, specifi-

Study performed at the Centro Artroscopico Jorge Batista, CABA, Buenos Aires, Argentina.

Correspondence: Jorge Pablo Batista. Av. Pueyrredon, 2446, piso 1, CABA, CP1119, Buenos Aires, Argentina. **E-mail:** jbatista20@hotmail.com. **Conflicts of interest:** none. **Source of funding:** none. **Date received:** June 13, 2022. **Date accepted:** June 15, 2022. **Online:** August 31, 2022.

How to cite this article: Batista JP, Arrondo GM, Joannas GM, Cangiano LV, Baraousse R, Casola L, et al. Peroneal nerve injuries during anterior ankle arthroscopy. *J Foot Ankle.* 2022;16(2):126-31.

cally occurring when the AL portal is performed^(5,6). On the other hand, the deep peroneal nerve (DPN) is rarely injured during ankle arthroscopy.

The primary objective of this study is to determine the incidence of peripheral nerve injuries during anterior ankle arthroscopy. The secondary objective is to evaluate the most frequent types and the clinical relevance of DPN injuries.

Anatomical review

At the level of the ankle, the anterior neurovascular bundle is located just anterior to the joint capsule, being composed by the DPN and the anterior tibial artery (ATA) or dorsalis pedis artery and veins⁽⁷⁾ (Figure 1).

The DPN and SPN are the terminal branches of the common peroneal nerve, which divides around the proximal fibula. At the ankle, the DPN runs deep to the inferior extensor retinaculum, between the tibialis anterior and the extensor hallucis longus (EHL) tendons, just anterior to the ankle joint capsule. In its turn the SPN reaches the lower third of the leg, pierces the deep crural fascia, and divides into two terminal branches: the medial and intermediate dorsal cutaneous nerves. These nerves enter the foot to innervate the majority of its dorsal surface.

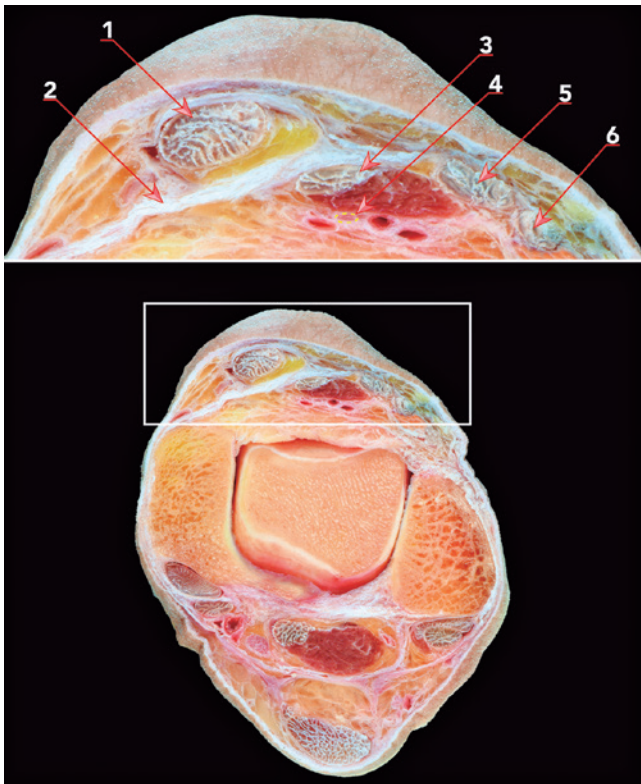


Figure 1. Transversal cross-section of a specimen showing the anatomy of anterior ankle structures: 1. Anterior tibialis tendon; 2. Oblique superomedial band of the inferior extensor retinaculum; 3. Extensor hallucis longus; 4. Deep peroneal nerve; 5. Extensor digitorum longus tendons; and 6. Peroneus tertius tendon.

Nerve injury diagnosis

The diagnosis of nerve injury is based on symptoms referred by the patient, physical examination, and diagnostic imaging, among which ultrasonography plays an important role.

Symptoms manifested by patients with neurological injury after ankle arthroscopy include pain, hypoesthesia, or anesthesia on the dorsum of the foot.

The degree of nerve injury is classified as neuropraxia, axonotmesis, or neurotmesis with or without intra-fascicular fibrosis, and with or without change in nerve diameter.

High-resolution ultrasonography is an excellent imaging method to explore normal anatomy and disorders of peripheral nerves⁽⁸⁾. Recent improvements on transducer quality allow the examination of large- and medium-sized nerves, but can also be used to explore small peripheral nerves, especially when they are superficially located^(9,10).

Methods

Patients who underwent anterior ankle arthroscopy at our institution from 2000 to 2020 were retrospectively analyzed. All procedures were performed by the senior author (JPB) using two arthroscopic portals: the AL portal and the AM portal.

Inclusion criteria: All patients who underwent anterior ankle arthroscopy at our institution between 2000 and 2020, answered our telephone call, and could be evaluated by physical examination in order to find nerve damage signs.

Exclusion criteria: Patients who could not be evaluated by physical examination to identify signs of neurological damage.

The arthroscopic surgeries analyzed in this study included: synovectomy, excision of osteophytes, debridement of the lateral gutter, removal of loose bodies, removal of painful ossicles, excision or drilling of osteochondral lesions of the talus, and repair of the anterior talofibular ligament. These procedures were performed to treat patients with a number of primary diagnoses, including synovitis, osteophytes, soft tissue and bone impingement, loose bodies, painful ossicles, osteochondral lesions of the talus, and lateral ankle instability.

Neurological complication was defined as any problem involving a peripheral nerve of the ankle with any of the following symptoms: diffuse pain in the anterior region of the ankle and foot, postoperative paresthesia, hypoesthesia, hyperesthesia, or anesthesia. Only patients who presented any of these neurological symptoms upon interrogation and clinical examination were evaluated by ankle ultrasonography.

Ultrasonographic evaluation

Ultrasonographic evaluations were performed by a musculoskeletal radiologist experienced in nerve evaluation using a Philips ultrasound equipment with a 418 Mhz multi-frequency, linear transducer.

The anterior aspect of the ankle was examined and the structures at risk during ankle arthroscopy were assessed.

The EHL and extensor digitorum longus (EDL) tendons, ATA, DPN, and medial branch of SPN were examined with particular attention.

Color Doppler imaging was used in all examinations to identify vessels and investigate blood flow. The ATA was examined to rule out the presence of pseudoaneurysm^(1,4,11-13), looking for integrity and intact blood flow.

The DPN was identified. Integrity and continuity, areas of focal thickening and thinning, and alterations in its arrangement with signs of displacement or retraction related or not to areas of perineural or intraneural fibrosis were assessed.

The SPN was identified at the point where it pierces the crural fascia, proximal to the ankle joint. The medial and intermediate dorsal cutaneous branches were identified and studied looking for the presence of neuroma.

Complication classification system

The different types of nerve injuries were analyzed and classified according to the Modified Clavien-Dindo-Sink Complication Classification System. This system consists of five grades of complications based on their severity and considering the therapy required to treat such complications.

Results

A total of 526 patients who underwent ankle arthroscopy at our institution from 2000 to 2020 were identified, but only 334 patients answered our telephone call and could be examined and being were finally included in the present study.

The mean age of patients was 32 years old (range 15-59 years old, median 31 years old). Two hundred and fourteen patients (64.07%) were male, and 120 patients (35.93%) were female. The right ankle was operated in 131 cases (39.22%) and the left ankle in 203 cases (60.78 %) (Table 1).

Of the 334 patients evaluated, 26 (7.78%) had neurological symptoms manifested during interrogation and physical examination, and thus underwent ultrasonographic evaluation.

Ultrasonography confirmed the integrity of ATA in all patients who underwent ultrasonographic evaluation (Figure 2). However, the 26 patients with neurological symptoms demonstrated ultrasonographic signs of nerve damage. Of these 26 complications, 16 cases (4.79%) affected the SPN, and 10 cases (2.99%) affected the DPN.

Among the 10 patients with DPN injuries, five cases (1.5%) had an entrapment of the nerve in postoperative tissue adhesions of the capsule joint; three patients (0.9%) presented neuromas, two neuromas-in-continuity and one terminal neuroma (neurotmesis); and two patients (0.6%) had axonotmesis (Table 2).

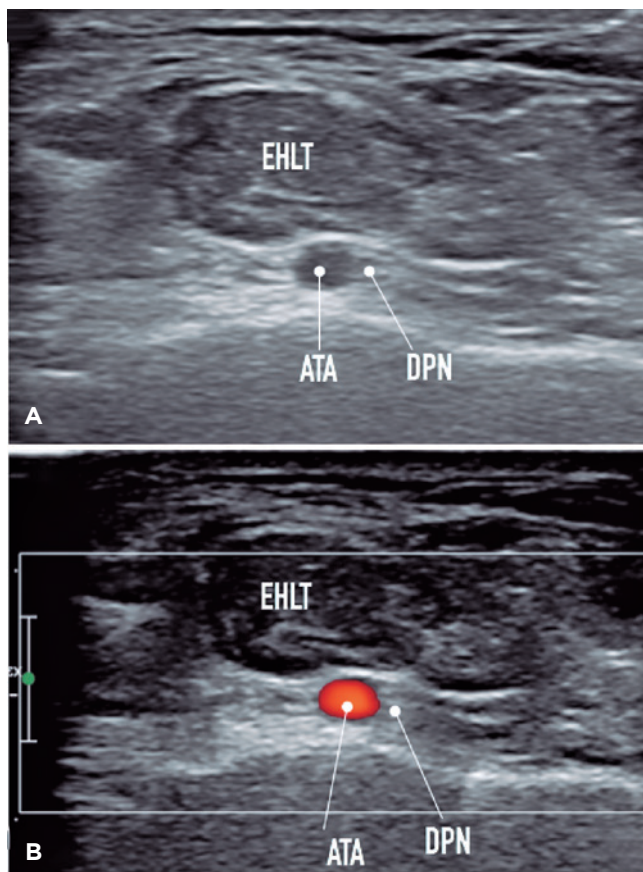


Figure 2. The images show the relationship of the deep peroneal nerve (DPN) with the anterior tibial artery (ATA), deep to the extensor hallucis longus tendon (EHLT). A) B-mode image with the anatomical relationship of vasculonervous structures. B) Color Doppler technique allows differentiation of the vascular structure from the adjacent nerve.

Table 1. Demographic data

Mean age	32 (15-59)
Gender	
Male	214 (64.07%)
Female	120 (35.93%)
Side	
Right	131 (39.22%)
Left	203 (60.78%)

Table 2. Nerve injury due to anterior ankle arthroscopy

	N
Superficial peroneal nerve injury	16
Deep peroneal nerve injury:	10
- Nerve entrapment in scar tissue	5
- Neuroma	3
- Axonotmesis	2
Total	26

No cases of neurological injury due to compartment syndrome or tourniquet compression were observed (Figures 3, 4, 5, and 6).

The abovementioned complications were classified based on the Modified Clavien-Dindo-Sink Complication Classification System⁽¹⁴⁾.

We considered the cases of entrapment of the nerve in postoperative tissue adhesions and neuromas-in-continuity as grade I complications (complications that do not result in a deviation from routine follow-up in the postoperative period, have minimal clinical relevance, and require minimal treatment, such as analgesics and physical therapy, or no treatment at all). This kind of complication had an incidence of 2.1% in the present study.

Cases of terminal neuroma (neurotmesis) and axonotmesis were considered as grade II complications (complications that result in a deviation from the normal postoperative course, including unplanned clinic/office visits, and require outpatient treatment, either pharmacological or for close monitoring). Grade II complications had an incidence of 0.9% in this study.

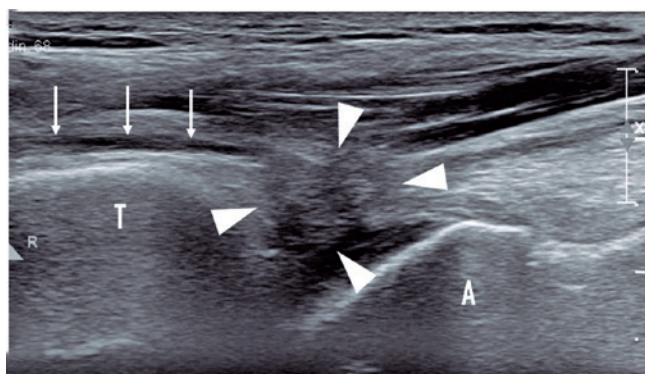


Figure 3. Ultrasonography showing an entrapment of the deep peroneal nerve within postoperative tissue adhesions of the capsule joint. White arrows mark the course of the deep peroneal nerve in longitudinal plane. White arrowheads show the margins of the area of periarticular fibrosis that entraps the nerve in its course.

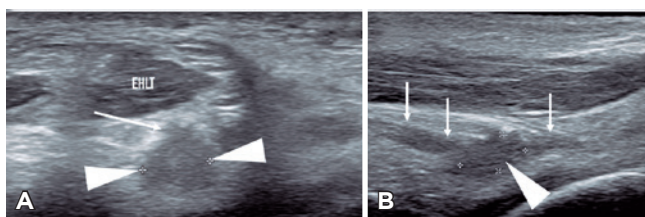


Figure 4. Ultrasonography showing a neuroma-in-continuity. A) Axial plane. B) Longitudinal plane. Short white arrows show the path of the deep peroneal nerve in longitudinal plane, proximal and distal to a neuroma in lateral continuity (arrowheads) adjacent to the nerve visualized in axial plane (long white arrow).

Considering that all complications were grade I or II, they were not serious complications and did not have clinical relevance for patient recovery.

Discussion

There are different causes of DPN injury, such as due to direct trauma or repetitive microtrauma, as happens in soccer players, where DPN injury is related to frequent trauma to the dorsum of the ankle and foot during the kicking action. Other causes are recurrent ankle sprains or bony impingement, with prominent osteophytes near the DPN (or its branches), in which the nerve may be stretched.

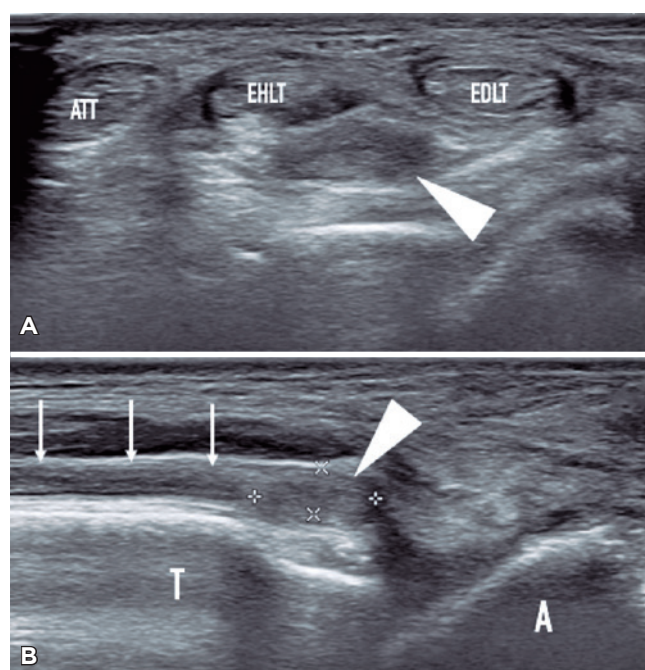


Figure 5. Ultrasonography showing a terminal neuroma. A) Axial plane. B) Longitudinal plane. White arrows mark the course of the deep peroneal nerve. Arrowheads mark the terminal neuroma.

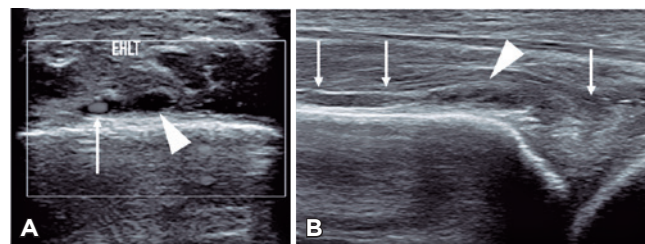


Figure 6. Ultrasonography showing a case of axonotmesis. A) Color Doppler axial plane. B) Color Doppler longitudinal plane. In axial plane, heterogeneous thrust of the deep peroneal nerve is observed in its course (arrowhead) adjacent to the anterior tibial artery (long white arrow), which can be recognized in the course of the nerve (white arrows).

However, one of the most important causes of DPN disorders is iatrogenic nerve damage during or after arthroscopic surgery, in which the nerve may be directly damaged by the shaver or entrapped in scar tissue. In these patients, nerve injury may be caused by the pressure exerted by surgical instruments, nerve stretching, or nerve section while using the shaver. Furthermore, an entrapment of the nerve caused by postoperative fibrosis might produce similar symptoms.

Nerve injury is the most common complication related to anterior ankle arthroscopy. Superficial peroneal nerve is one of the most frequently injured structures during ankle arthroscopy more specifically, during anterolateral portal placement and several articles about this complication have been published⁽¹⁻⁵⁾. However, only a few studies have been focused on DPN injury after ankle arthroscopy^(2,3,5).

The primary objective of this study was to determine the incidence of neurological injuries during anterior ankle arthroscopy. We found an incidence of neurological complications of 7.78%. Although this is a high complication rate, most of these cases were not clinically relevant (grade I or II in the Modified Clavien-Dindo-Sink Complication Classification System)⁽¹⁴⁾. The SPN was injured in 4.79% of cases and the DPN was affected in 2.99% of cases. The secondary objective of this study was to evaluate the most frequent DPN injury types. Among patients who presented DPN injuries, 1.5% had an entrapment of the nerve in postoperative tissue adhesions of the capsular joint, 0.9% presented neuromas, and 0.6% had axonotmesis.

There are different factors that predispose to injuries of the DPN during arthroscopic procedures. The main risk factor is the overuse of the shaver against the joint capsule: as the DPN is located just anterior to the joint capsule, excessive shaver use against the capsule may cause direct nerve damage.

Most surgeons recommend working in ankle dorsiflexion, which increases the working area during arthroscopic surgery, allowing the use of larger diameter arthroscopes and wider arthroscopic instruments. In addition, working in ankle dorsiflexion reduces the tension on anterior neurovascular structures, thus reducing the complication rate associated with anterior ankle arthroscopy⁽³⁾ while allowing the performance of advanced arthroscopic techniques⁽¹⁵⁾. Another advantage of this maneuver is that, during ankle dorsiflexion, the articular cartilage of the talus is protected against iatrogenic damage⁽¹⁶⁾.

Preventing neurological complications are crucial, because these are directly related to the arthroscopic technique employed. Extensive knowledge of the ankle arthroscopic anatomy, surgeon training, and experience in this field are essential variables that can play an important role in preventing this undesirable complication.

Conclusions

Nerve injury is the most common complication related to anterior ankle arthroscopy.

We found an overall incidence of neurological complications of 7.78%. Although this is a high complication rate, most of these were not clinically relevant (grade I or II in the Modified Clavien-Dindo-Sink Complication Classification System).

Preventing this kind of neurological complication is crucial because they are directly related to the arthroscopic technique employed.

Further studies with a multicenter approach might be useful to determine the actual incidence of DPN injuries during ankle arthroscopy.

Authors' contributions: Each author contributed individually and significantly to the development of this article: JPB *(<https://orcid.org/0000-0003-0910-4140>) Conceived and planned the activities that led to the study, performed the surgeries, participated in the review process, interpreted the results of the study, approved the final version; GMA *(<https://orcid.org/0000-0003-4767-5489>) Data collection and approved the final version; GMJ *(<https://orcid.org/0000-0001-9998-190X>) Participated in the review process, formatting of the article, approved the final version; LVC *(<https://orcid.org/0000-0002-0202-9603>) Data collection, bibliographic review; RB *(<https://orcid.org/0000-0001-5940-7540>) Clinical examination, bibliographic review; LC *(<https://orcid.org/0000-0003-1187-0864>) Data collection and approved the final version; MDP *(<https://orcid.org/0000-0001-6043-698X>) Interpreted the results of the study, bibliographic review, participated in the review process and approved the final version. All authors read and approved the final manuscript.

*ORCID (Open Researcher and Contributor ID) .

References

- Carlson MJ, Ferkel RD. Complications in ankle and foot arthroscopy. *Sports Med Arthrosc Rev.* 2013;21(2):135-9.
- Deng DF, Hamilton GA, Lee M, Rush S, Ford LA, Patel S. Complications associated with foot and ankle arthroscopy. *J Foot Ankle Surg.* 2012;51(3):281-4.
- Zengerink M, van Dijk CN. Complications in ankle arthroscopy. *Knee Surg Sports Traumatol Arthrosc.* 2012;20(8):1420-31.
- Epstein DM, Black BS, Sherman SL. Anterior ankle arthroscopy: indications, pitfalls, and complications. *Foot Ankle Clin.* 2015; 20(1):41-57.
- Yamine K, Assi C. Neurovascular and tendon injuries due to ankle arthroscopy portals: a meta-analysis of interventional cadaveric studies. *Surg Radiol Anat.* 2018;40(5):489-97.

6. Stotter C, Klestil T, Chemelli A, Naderi V, Nehrer S, Reuter P. Anterocentral portal in ankle arthroscopy. *Foot Ankle Int.* 2020; 41(9):1133-42.
7. de Leeuw PAJ, Golano P, Clavero JA, van Dijk CN. Anterior ankle arthroscopy, distraction or dorsiflexion? *Knee Surg Sports Traumatol Arthrosc.* 2010;18:594-600.
8. Riegler G, Lieba-Samal D, Brugger PC, Pivec C, Platzgummer H, Vierhapper M, et al. High-resolution ultrasound visualization of the deep branch of the ulnar nerve. *Muscle Nerve.* 2017;56(6):1101-7.
9. Causeret A, Lapègue F, Bruneau B, Dreano T, Ropars M, Guillin R. Painful traumatic neuromas in subcutaneous fat: visibility and morphologic features with ultrasound. *J Ultrasound Med.* 2019;38(9):2457-67.
10. Becciolini M, Pivec C, Riegler G. Ultrasound imaging of the deep peroneal nerve. *J Ultrasound Med.* 2021;40(4):821-38.
11. Verbrugghe P, Vandekerckhof J, Baeyens I. Pseudoaneurysm of the anterior tibial artery: a complication of ankle arthroscopy. *Acta Chir Belg.* 2011;111(6):410-1.
12. Jeffery CA, Quinn SJ, Quinn JM. Pseudoaneurysm of the anterior tibial artery after ankle arthroscopy. *ANZ J Surg.* 2014;84(5):391-3.
13. Schaarschmidt BM, Heuser LJ. Diagnostics and treatment of pseudoaneurysms of the distal anterior tibial artery after upper ankle joint arthroscopy: a case report and a review of literature. *Rofo.* 2013;185(2):169-71.
14. Dodwell ER, Pathy R, Widmann RF, Green DW, Scher DM, Blanco JS, et al. Reliability of the modified clavien-dindo-sink complication classification system in pediatric orthopaedic surgery. *JBJS Open Access.* 2018;3(4):e0020.
15. Dalmau-Pastor M, Vega J. Ankle arthroscopy: no-distraction and dorsiflexion allows advanced techniques. *Arthroscopy.* 2019; 35(12):3171-2.
16. Tol JL, van Dijk CN. Anterior ankle impingement. *Foot Ankle Clin.* 2006;11(2):297-310.