

## Case Report

# Ankle desarthrodesis: report of three cases

Tiago Soares Baumfeld<sup>1</sup> , Beatriz Marinho Guimarães<sup>2</sup> , Caio Augusto de Souza Nery<sup>3</sup> , Daniel Soares Baumfeld<sup>4</sup> 

1. Hospital Felício Rocho, Belo Horizonte, MG, Brazil.
2. Hospital Risoleta Tolentino Neves, Belo Horizonte, MG, Brazil.
3. Hospital Israelita Albert Einstein, São Paulo, SP, Brazil.
4. Universidade Federal de Minas Gerais, Belo Horizonte, MG, Brazil.

## Abstract

The good results of primary ankle arthroplasty and long-term dissatisfaction with arthrodesis have made arthrodesis, that is, the conversion of an arthrodesis into arthroplasty, an option for patients with a painful ankle fusion. This study presents the results of three patients submitted to ankle desarthrodesis in Brazil between 2019 and 2021. Two men and one woman, aged between 48 and 52 years and with an arthrodesis-prosthetic interval between two and 30 years, presented satisfactory results after arthroplasty. Pain reduction and increased functional capacity were observed, representing an improvement in the visual analog scale (VAS) between 5 and 6 points, range of motion (ROM) gain between 20° and 45° and progress in the American Orthopaedic Foot & Ankle Society (AOFAS) score between 17 and 54 points in the postoperative follow-up. Although it is a procedure with a long learning curve, desarthrodesis should be considered a therapeutic alternative to painful ankle arthrodesis.

**Level of Evidence IV; Case Series; Therapeutic Studies - investigating the results of treatment.**

**Keywords:** Arthrodesis; Arthroplasty; Osteoarthritis; Ankle.

## Introduction

Osteoarthritis (OA) is a chronic, progressive and irreversible disease associated with pain, mobility limitation, and reduction in quality of life that affects 15% of the population worldwide, totaling approximately 250 million people<sup>(1-3)</sup>. Among these, the ankle represents 1% of the total cases. Unlike the large joints of the lower limb, where the primary origin is the main etiology<sup>(3)</sup>, the ankle is predominantly post-traumatic (78%), followed by other systemic secondary causes (13%), such as rheumatoid arthritis and hemophilia. The primary etiology is rare and represents only 9% of the cases<sup>(4,5)</sup>.

Due to the global increase of OA, among the ten leading causes of disability in developed countries, and the repercussion of using economic resources in health and absenteeism at work<sup>(6,7)</sup>, great effort has been made to improve the treatment of this disease. Previously considered the gold standard for OA in advanced stages<sup>(8)</sup>, ankle arthrodesis is associated with medium and long-term complications, especially arthrodesis of adjacent joints, making total ankle arthroplasty (TAA) an option highly indicated as primary treatment<sup>(5,9,10)</sup> and a therapeutic alternative for cases of painful joint fusions.

## Case descriptions

The study was approved by the institution's ethics committee, and all patients signed an informed consent form to be included in the study.

Three patients underwent conversion of painful tibiotarsal arthrodesis into TAA with the Infinity implant (Wright Medical, Memphis, TN, USA), in Brazil, from 2019 to 2021.

Case 1: A 51-year-old female patient diagnosed with undetermined inflammatory arthritis with polyarticular involvement without other comorbidities. The patient presented mixed pain (mechanical and inflammatory) and sporadic incapacitation for daily activities with decreased ankle range of motion (ROM). Due to a traumatic fracture of the medial malleolus, it evolved into severe ankle OA. The patient underwent arthrodesis of the right ankle and then developed ankle pseudarthrosis (sagittal alignment in neutral and coronal with 6° of valgus) and chronic pain. After three years, due to disabling ankle pain, arthrodesis was converted to TAA with satisfactory results: a 5-point reduction in the visual analog scale (VAS) [interval: preoperative 8 to postoperative 3], a

Study performed at the Hospital Felício Rocho, Belo Horizonte, MG, Brazil and Hospital Israelita Albert Einstein, São Paulo, SP, Brazil.

**Correspondence:** Tiago Soares Baumfeld. Av. do Contorno, 9530, Barro Preto, Belo Horizonte, MG, Brazil, 30110-017. **E-mail:** [tiago.baumfeld@gmail.com](mailto:tiago.baumfeld@gmail.com).  
**Conflicts of interest:** Daniel Soares Baumfeld and Caio Augusto de Souza Nery: Stryker: Speaker. Tiago Soares Baumfeld: Medartis: Speaker. **Source of funding:** none. **Date received:** July 11, 2022. **Date accepted:** November 17, 2022. **Online:** December 20, 2022.

**How to cite this article:** Baumfeld TS, Guimarães BM, Nery CAS, Baumfeld DS. Ankle desarthrodesis: report of three cases. *J Foot Ankle.* 2022;16(3):295-8.

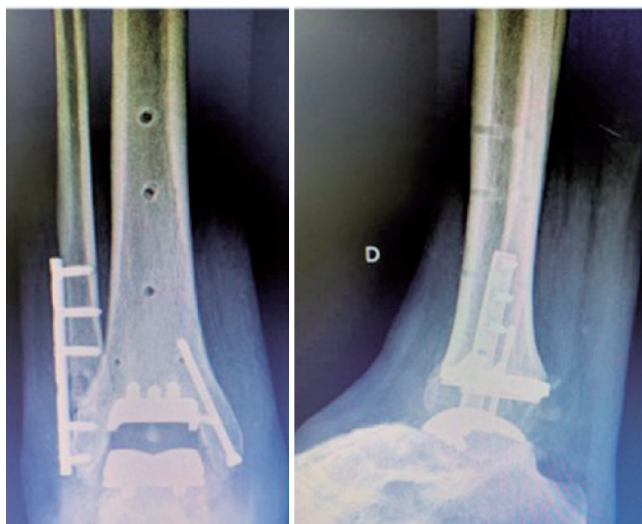


gain of 45° in active ROM [interval: 15° of equine to 30° dorsiflexion], measured by closed kinetic chain goniometry by one of the authors and an improvement of 54 points [interval: 18 to 72] in The American Orthopaedic Foot and Ankle Society (AOFAS) score (Ankle-Hindfoot Score) after 12 months of postoperative follow-up.

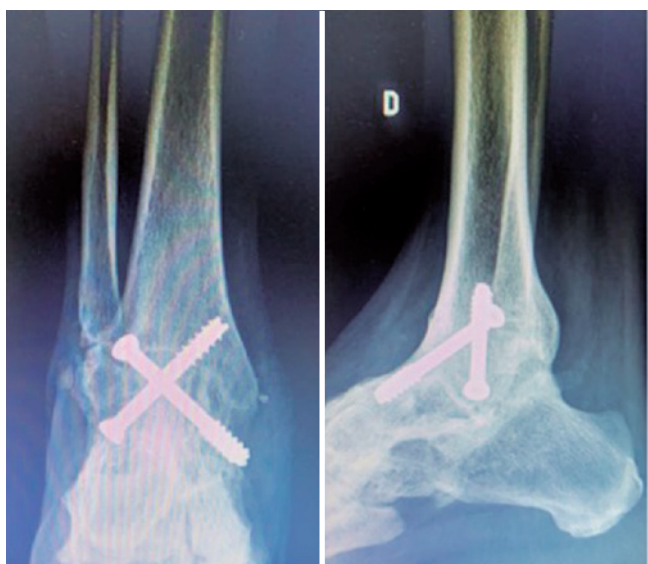
Case 2: 48-year-old male patient, obese (Body mass index (BMI = 30)), with post-traumatic arthrosis due to bimalleolar ankle fracture (medial and lateral malleolus). The patient underwent tibiotalar arthrodesis to treat chronic pain, a mechanical pattern of strong intensity and functional limitation presenting poor postoperative evolution. However, consolidation of the arthrodesis with good angular parameters and radiographic consolidation was obtained. After five years of conservative treatment failure using optimized analgesia, physiotherapy, and orthopedic shoes, it was decided to convert the tibiotalar arthrodesis, performed 12 years ago, into TAA and obtaining the following results: a 6-point reduction in VAS [interval: 8 to 2], a gain of 20° in active ROM [interval: 0° to 20°], measured by closed kinetic chain goniometry by one of the authors and an improvement of 52 points in the AOFAS score [interval: 33 to 85] after nine months of postoperative follow-up (Figures 1, 2 and 3).

Case 3: A 52-year-old female patient with poliomyelitis in the lower limb without other comorbidities, with 20 years of evolution of panarthrosis (tibiotalar, subtalar, and talonavicular) that resulted in chronic ankle pain of mechanical pattern and functional limitation. The tibiotalar joint showed no angular or rotational deviations. The alignment of the hindfoot was 5°. Then, the tibiotalar arthrodesis, performed 20 years ago, was converted into TAA, associa-

ted with calcaneal valgus osteotomy and elongation of the hook-type Achilles tendon (triple hemisection). Significant postoperative improvement was observed with a 6-point reduction in VAS [interval: 8 to 2], a gain of 20° in ROM [range: 0° to 20°], measured by closed kinetic chain goniometry by one of the authors and an improvement of 17 points in the AOFAS score [interval: 48 to 65] after eight months of postoperative follow-up (Table 1).



**Figure 2.** Case 2: Postoperative right ankle radiographs in anteroposterior (left) and lateral (right) views where TAA is observed with adequate component positioning and prophylactic malleolar fixation.



**Figure 1.** Case 2: Preoperative right ankle radiographs in anteroposterior (left) and lateral (right) view with consolidated arthrodesis and without angular deviations.



**Figure 3.** Case 2: Ectoscopy with maximum ROM obtained after six months postoperatively.

**Table 1.** Patient demographics and clinical data

Gender	age	Etiology	VAS		AOFAS		ROM	
			Pre-op	Post-op	Pre-op	Post-op	Pre-op	Post-op
F	51	Inflammatory	8	3	18	72	<15	30°
M	48	Post-traumatic	8	2	33	85	0°	20°
F	52	Secondary to poliomyelitis	8	2	48	65	0°	20°

\*VAS: Visual analog scale; AOFAS: American Orthopaedic Foot & Ankle Society; ROM: Range of motion.

The three patients complained of mechanical ankle pain, with no predominant symptoms in adjacent joints, and underwent removal of the synthesis material and single-stage TAA via anterior access to the ankle. In addition, prophylactic malleolar fixation, bone cuts through the extramedullary guide, and TAA with the Infinity implant (Wright Medical, Memphis, TN, USA) was performed, as originally described in the literature<sup>(9,11)</sup>.

The patients were submitted to the same postoperative protocol with immobilization with a cast without support and ROM training during the first four weeks, in which the dressing was changed weekly. In the fourth week, the stitches were removed, and the patients were referred to functional rehabilitation with individualized physical therapy aiming at a progressive ROM gain, gait training, muscle strengthening, balance, and proprioception. The support was performed in a protected manner with an immobilizer boot until the sixth week and removed later. Activities in the open kinetic chain academy and indoor bicycle training were allowed after this period. In addition, closed kinetic chain walks and exercises were allowed after three months postoperatively.

## Discussion

The prevalence and biopsychosocial impact of ankle OA have resulted in improved therapeutic modalities in recent years. In the final stage, the surgical treatment of OA, until recently, as a gold standard, was based on pain control at the expense of mobility and joint preservation through arthrodesis<sup>(3,8)</sup>. This treatment was associated with a high rate of arthrosis in adjacent joints in the medium and long-term, especially in the hindfoot<sup>(4,12)</sup>, requiring additional surgical procedures and decreasing patient satisfaction<sup>(2)</sup>.

Total ankle arthroplasty, an alternative to joint fusion in severe cases, was little used until the mid-2000s due to higher complication rates than arthrodesis<sup>(4,10)</sup>. For this reason, improvements were sought to enable the performance of TAA and reduce its high complication rates. These improvements were obtained with a 3rd generation system and allowed greater use of the technique with more satisfactory results<sup>(4)</sup>.

Therefore, the good results with primary arthroplasty and decrease in late satisfaction after arthrodesis, related to secondary arthrosis or due to complications, such as non-union or vicious consolidation, raise the possibility of converting an arthrodesis to TAA<sup>(6,8)</sup>. Unfortunately, this procedure, of great technical difficulty, although described in 2004 by Greisberg

et al.<sup>(9)</sup> in a cases series involving 18 patients with a mean follow-up of 39 months, has not been reported in Brazil until the publication of this study.

Common indications for conversion of arthrodesis into TAA include pseudarthrosis, vicious consolidation, or arthrodesis with symptoms in adjacent joints. The absolute contraindications are the presence of active infection, severe peripheral vascular disease, inadequate soft tissues for coverage, and Charcot arthropathy; the relative ones are the absence of distal fibula, talar osteonecrosis, extensive ligament injury, active smoking, and anticipation of inadequate postoperative alignment<sup>(2,7)</sup>.

Schuberth et al.<sup>(13)</sup> were responsible for the largest case series ever published, involving 77 ankles in a mean follow-up of 101 months, finding encouraging functional results with statistical significance ( $p < 0.05$ ). Despite a lower ROM gain than expected in a primary arthroplasty (16-20° versus 34-40°), the reduction or absence of pain and the mobility restoration improved the AOFAS score for ankle and hindfoot and VAS<sup>(2,3,12)</sup>.

These results are compatible with other studies available in the literature. Pellegrini et al.<sup>(14)</sup>, in a study involving 23 ankles with a mean follow-up of 33 months and a minimum of 12, obtained a reduction in VAS and improved quality of life through the Short Form-36 (SF-36). Preis et al.<sup>(15)</sup> evaluated 18 patients for a mean follow-up of 54 months and a minimum of 27 and also found statistically significant results for pain reduction and increased quality of life and mental health, represented by VAS and SF-36, respectively. Hintermann et al.<sup>(11)</sup>, evaluating the same parameters in 29 ankles of 27 patients for a mean follow-up of 55 months and a minimum of 36, reached 82% of patient satisfaction and a mean of 24° ankle ROM gain.


Therefore, as described above, the patients in this study met the procedure's formal indications and had no absolute contraindications. Furthermore, the results obtained about the improvement of pain, quality of life, and important ROM gain, combined with the possibility of performing daily living activities, such as walking on uneven surfaces, climbing stairs, or low-impact sports practice, met the patient's expectations and are favorable to the proposal of desarthrodesis followed by TAA.

However, the study has limitations. The study is a case report with a short number of patients and a limited follow-up time of 12 months. In addition, the ROM evaluation was performed by goniometry and not by serial radiography, resulting in a tibiopodal and not a tibiotarsal angle.

Thus, a greater number of cases is necessary to objectively evaluate the results of desarthrodesis followed by TAA in Brazil with long-term follow-up.

## Conclusion

Desarthrodesis is a treatment option with good results for painful ankle arthrodesis.

**Authors' contributions:** Each author contributed individually and significantly to the development of this article: TSB \*(<https://orcid.org/0000-0001-9244-5194>), BMG \*(<https://orcid.org/0000-0002-7428-2798>) CASN \*(<https://orcid.org/0000-0002-9286-1750>) and DSB \*(<https://orcid.org/0000-0001-5404-2132>) Conceived and planned the activity that led to the study, wrote the article, participated in the review process. All authors read and approved the final manuscript. \*ORCID (Open Researcher and Contributor ID) .

## References

1. Herrera-Pérez M, González-Martín D, Vallejo-Márquez M, Godoy-Santos AL, Valderrabano V, Tejero S. Ankle osteoarthritis aetiology. *J Clin Med*. 2021;10(19):4489.
2. Brigido SA, Carrington SC, Protzman NM. Complex total ankle arthroplasty. *Clin Podiatr Med Surg*. 2017;34(4):529-39.
3. Brodsky JW, Jaffe D, Pao A, Vier D, Taniguchi A, Daoud Y, et al. Long-term functional results of total ankle arthroplasty in stiff ankles. *Foot Ankle Int*. 2021;42(5):527-35.
4. Chu AK, Wilson MD, Hough B, Thompson J, So E. Outcomes of ankle arthrodesis conversion to total ankle arthroplasty: a systematic review. *J Foot Ankle Surg*. 2021;60(2):362-7.
5. Cody EA, Scott DJ, Easley ME. Total ankle arthroplasty: a critical analysis review. *J Bone Joint Surg Am*. 2018;60(8):e8.
6. Coetzee JC, Raduan F, McGaver RS. Converting ankle arthrodesis to a total ankle arthroplasty. *Orthop Clin North Am*. 2021;52(2):181-90.
7. Cunha-Miranda L, Faustino A, Alves C, Vicente V, Barbosa S. [Assessing the magnitude of osteoarthritis disadvantage on people's lives: the MOVES study]. *Rev Bras Reumatol*. 2015; 55(1):22-30.
8. Deorio JK, Easley ME. Total ankle arthroplasty. *Instr Course Lect*. 2008;57:383-413.
9. Greisberg J, Assal M, Flueckiger G, Hansen ST Jr. Takedown of ankle fusion and conversion to total ankle replacement. *Clin Orthop Relat Res*. 2004;(424):80-8.
10. Godoy-Santos AL, Fonseca LF, de Cesar Netto C, Giordano V, Valderrabano V, Rammelt S. Ankle osteoarthritis. *Rev Bras Ortop* (Sao Paulo). 2020;56(6):689-96.
11. Hintermann B, Barg A, Knupp M, Valderrabano V. Conversion of painful ankle arthrodesis to total ankle arthroplasty. Surgical technique. *J Bone Joint Surg Am*. 2010;92 Suppl 1 Pt 1:55-66.
12. Günther KP, Stürmer T, Sauerland S, Zeissig I, Sun Y, Kessler S, et al. Prevalence of generalised osteoarthritis in patients with advanced hip and knee osteoarthritis: the Ulm Osteoarthritis Study. *Ann Rheum Dis*. 1998;57(12):717-23.
13. Schuberth JM, King CM, Jiang SF, Ross JS, Christensen JC, Steck JK. Takedown of Painful Ankle Arthrodesis to Total Ankle Arthroplasty: A Case Series of 77 Patients. *J Foot Ankle Surg*. 2020;59(3):535-40.
14. Pellegrini MJ, Schiff AP, Adams SB Jr, Queen RM, DeOrio JK, Nunley JA 2nd, et al. Conversion of Tibiotalar Arthrodesis to Total Ankle Arthroplasty. *J Bone Joint Surg Am*. 2015;97(24):2004-13.
15. Preis M, Bailey T, Marchand LS, Barg A. Can a three-component prosthesis be used for conversion of painful ankle arthrodesis to total ankle replacement? *Clin Orthop Relat Res*. 2017;475(9):2283-94.