

## Case Report

# Achilles tendon reconstruction using a biosynthetic graft: a case report

Kepler Alencar Mendes de Carvalho<sup>1</sup> , Eli Schmidt<sup>1</sup> , Amanda Ehret<sup>1</sup> , Ki Chun Kim<sup>1,3</sup> ,  
Nacime Salomão Barbachan Mansur<sup>1,2</sup> , César de César Netto<sup>1</sup> 

1. Department of Orthopedics and Rehabilitation, Carver College of Medicine, University of Iowa, Iowa City, IA, USA.

2. Department of Orthopedics and Traumatology, Paulista School of Medicine, Federal University of Sao Paulo, Sao Paulo, SP, Brazil.

3. Department of Orthopedic Surgery, Seoul Medical Center, Seoul, Korea.

## Abstract

A 56-year-old male was admitted to an outpatient clinic five months after feeling a snap in his right heel while walking in the yard. Clinical and imaging evaluation demonstrated a discontinuity of Achilles tendon (AT). The measured gap between the insertion and the proximal stump was 13cm. The patient underwent reconstruction using a bio-absorbable synthetic graft associated with a Flexor Hallucis Longus (FHL) transfer. Good functional outcomes were noted. Achilles tendon reconstruction with the biosynthetic flexible band proved feasible for massive tendon defects by inserting a biological scaffold for native tendon healing, improving postoperative recovery and strength.

**Level of Evidence V; Therapeutic Studies; Expert Opinion.**

**Keywords:** Achilles tendon; Graft; Tendon injuries; Reconstruction; Rupture.

## Introduction

One of the definitions of a chronic Achilles Tendon (AT) rupture is the delay in diagnosis or treatment of at least four to six weeks after the initial event<sup>(1,2)</sup>.

Management of patients with chronic Achilles ruptures involves both operative and nonoperative options. The choice between these options should be made after considering the patient's overall health status, assessment of risk factors for healing, and the patient's level of activity<sup>(3)</sup>.

Surgical treatment aims to reestablish a stable connection between the triceps and its insertion and secure a proper tendon length and tensioning<sup>(1-4)</sup>. Several techniques have been described, depending on the size of the injury and the

local conditions<sup>(5)</sup>. Ruptures smaller than 2cm can direct tendon repair<sup>(3)</sup>.

For defects ranging from 2 to 5cm, tendon-lengthening procedures, with or without tendon transfer, are advised. Injuries greater than 5cm may require a tendon transfer, with or without a tendon-lengthening procedure. Patients with extensive chronic tears and healthy muscles can present a unique challenge for the surgeon to fill the defect<sup>(2)</sup>.

The aim of the study was to report a chronic insertional AT rupture surgically treated with a bioabsorbable synthetic graft to insert a biological scaffold for native tendon healing, enhancing recovery and postoperative strength. The patient was informed that data concerning the case would be submitted for publication, and he provided consent.

Study performed at the UIOWA Orthopedic Functional Imaging Research Laboratory (OFIRL), University of Iowa, Carver College of Medicine, Department of Orthopedics and Rehabilitation. Iowa City, IA, USA.

**Correspondence:** Kepler Alencar Mendes de Carvalho. Department of Orthopaedic and Rehabilitation, University of Iowa, Carver College of Medicine, 200 Hawkins Dr. John PappaJohn Pavillion (JPP). Room 01066, Lower Level. Iowa City, IA, 52242, United States. **Email:** kepler-carvalho@uiowa.edu. **Conflicts of interest:** César de César Netto: CurveBeam: Paid consultant; Stock or stock Options; Foot and Ankle International: Editorial or governing board; Editor in Chief Foot and Ankle Clinics; Nextremity: Paid consultant; Ossio: Paid consultant; Paragon 28: IP royalties; Paid consultant; Weightbearing CT; International Study Group: Board or committee member; American Orthopaedic Foot and Ankle Society: Board or committee member. **Nacime Salomao Barbachan Mansur:** Brazilian Foot and Ankle Society: Board or committee member; American Orthopaedic Foot and Ankle Society: Board or committee member. **Source of funding:** none. **Date received:** August 30, 2022. **Date accepted:** November 17, 2022. **Online:** December 20, 2022.

How to cite this article: Carvalho KAM, Schmidt E, Ehret A, Kim KC, Mansur NSB, César Netto C. Achilles tendon reconstruction using a biosynthetic graft: a case report. *J Foot Ankle.* 2022;16(3):288-94.



## Case description

The study was approved by the Research Ethics Committee of the institution and the patient signed the informed consent form.

## Preoperative evaluation

A 56-year-old male (BMI: 38.6Kg/m<sup>2</sup>, height: 185.4cm, limb length: 42.1cm) was admitted to an outpatient clinic five months after feeling a snap in his right heel while walking in the yard.

The patient stated that the severity of pain, swelling, and weakness is progressively aggravating, limiting his activities, including golf. He denied any comorbidities or smoking. On physical examination, the patient presented with intact skin. There was moderate tenderness to palpation at mid-substance and insertion of the Achilles. A 4 out of 5 muscle strength in plantar flexion was noted. Dorsiflexion, inversion, and eversion had 5 out of 5 strength. The patient had a 15° increase in passive dorsiflexion of the right ankle compared to the left side. The double heel raise test was negative, and the single heel raise was positive.

The radiograph and the whole blood clotting test demonstrated a bone spur at Achilles insertion with no signs of avulsion (Figure 1 A-B). Magnetic resonance images (MRI) confirmed the Achilles discontinuity at the insertion site, scar tissue formation on the gap, and minor fatty infiltration of the gastrosoleus complex (Goutalier 1) (Figure 1 C-J).

## Surgical technique

The patient received general anesthesia, a popliteal block, and was in supine position on the operating room table. No tourniquet was used.

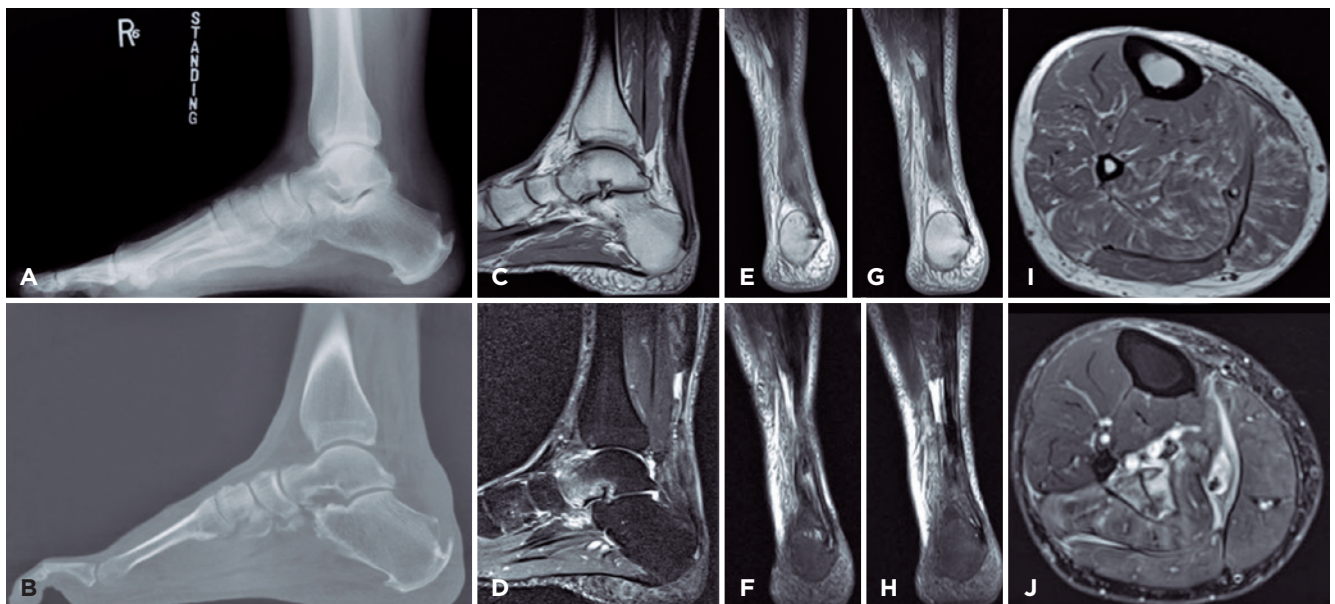
First, we proceeded with a 10cm long longitudinal incision, starting 1cm proximal to the plantar pad and running medially and parallel to the trajectory of the residual AT.

The peritenon was incised in line with the residual AT that was confirmed ruptured at its insertion and retracted. A significant amount of scar tissue was filling the space of the old AT. The few distal remaining fibers were severely degenerated and were resected (Figure 2 A-B).

Achilles' degenerations and calcifications were removed with a sharp knife to the level of good tissue (pearly, shining, organized fibers) (Figure 2 C). The measured gap between the insertion and the proximal stump was 13 cm (Figure 2 D).

The Flexor Hallucis Longus (FHL) tendon and muscle belly were found at the deep crural fascia and carefully dissected (Figure 3A). A longitudinal 4 cm medial approach was then performed just to the plantar aspect of the first metatarsal base along the longitudinal arch of the foot. The FHL tendon was identified and cut distal to Henry's knot (Figure 3B) and retrieved proximally in the posteromedial wound. The FHL tendon was measured with a diameter of 5 mm, and its distal stump was prepared (Figure 3C).

A guidewire for an interference screw in a central position was then placed into the calcaneal tuberosity from dorsal to



**Figure 1.** Preoperative imaging assessment. Lateral radiograph (A) and sagittal weight-bearing computed tomography scan (B) demonstrated a bone spur at Achilles insertion with no signs of avulsion. Sagittal (C, D) and coronal (E-H) MRI confirmed the Achilles discontinuity at the insertion site and scar tissue formation over the gap. Axial leg MRI showed minor fatty infiltration of the gastrosoleus complex (Goutalier 1) (I, J).

plantar at the Achilles insertion footprint (Figure 3D). Next, a 5.5mm tunnel was drilled into the calcaneal tuberosity (Figure 3E). Using the guidewire, the FHL tendon was inserted into the calcaneal tuberosity and delivered into the plantar aspect of the foot (Figure 3F).

While maintaining the foot in 30° of plantar flexion, the FHL tendon transfer was tensioned distally into the plantar aspect of the foot. A 5mm peek interference screw was inserted into the calcaneal tuberosity tunnel from dorsal to plantar. Adequate tensioning of the FHL tendon was maintained. Good deformity correction with maintained plantar flexion of the ankle joint was noted.

Two 2.9mm anchors were inserted medially and laterally into the central tunnel. A 7mm x 32cm bio-absorbable synthetic graft (Artelon™, Marietta, GA, USA) flex band was weaved into the Achilles proximal stump with 0 Vicryl™ sutures (Figure 4A). The construct was brought distally and sutured to the FHL tendon using three interrupted horizontal mattresses (Figure 4B). The biosynthetic graft was then sutured into the calcaneal tuberosity using the two anchors while maintaining the foot into 30° of plantar flexion (Figure 4 C-E). Tension was placed at the biosynthetic graft and brought back proximally into the proximal stump of the AT. Adequate ankle positioning, tensioning, and stability of the entire construct were noted (Figure 5).

Achilles peritendon was sutured with 3-0 Vicryl™, protected with a dehydrated human amnion/chorion membrane allograft (Figure 6A-C).

### Postoperative course

Prophylaxis for deep vein thrombosis was prescribed. The patient remained non-weight-bearing with a cast in a 15°

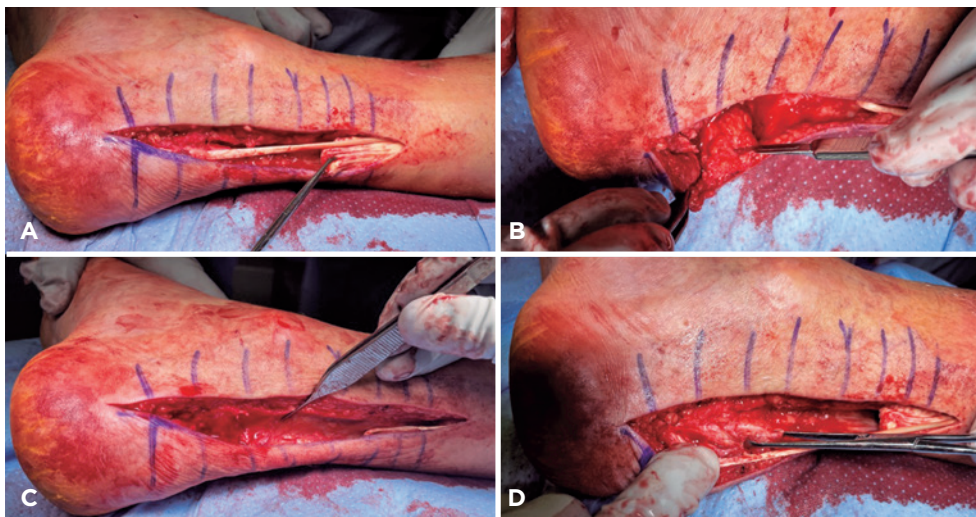
plantar flexion position for two weeks. This was followed by two weeks of using a walking boot when weight-bearing was initiated. The rehabilitation program started six weeks after the surgery, consisting of a range of motion gain and progressive resistance exercises while taking care to avoid dorsiflexion stretching of the ankle above neutral until the 12<sup>th</sup> week. The boot was discontinued after 12 weeks of surgery when the patient progressed to a muscle training, balance, and proprioception program.

No medical or surgical complications have occurred to date, 12 months after surgery (Figure 7A-D). Postoperative radiographs showed the implant in a good position with no signs of loosening or osteolysis (Figure 8A). After 12 months, the MRI demonstrated complete healing of the biosynthetic graft at the muscular and bone attachments. The FHL tendon was also integrated, and its muscle hypertrophied (Figure 8 B-J). Incisions were healed, plantar flexion strength was 5 of 5, and the single heel raise test was positive. The ankle joint had 5° of dorsiflexion and 40° of plantar flexion.

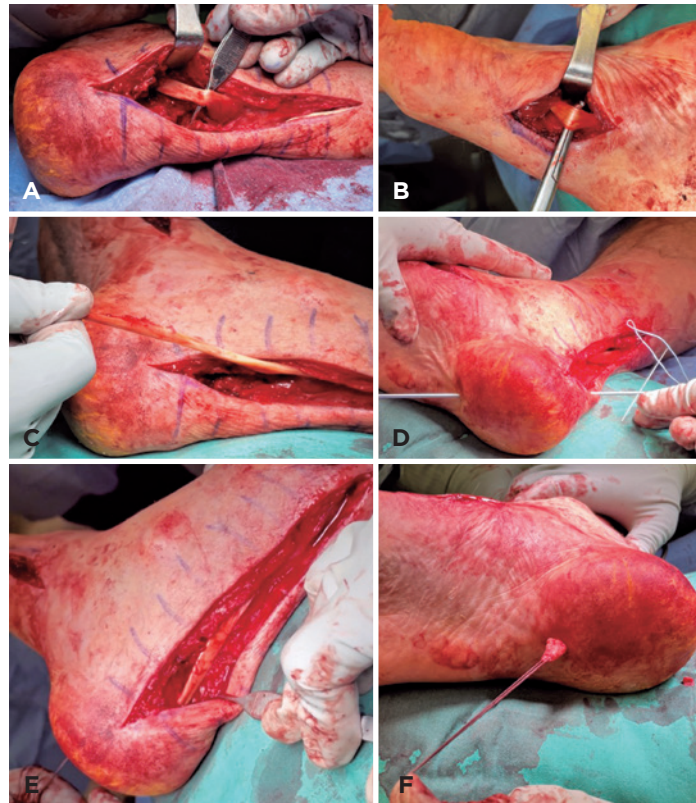
Patient-Reported Outcomes Measurement Information System (PROMIS) consistently demonstrated positive changes in symptoms and function. PROMIS Global Physical Health T-score increased from 42 to 54 at 12 months. The Foot Function Index (Activity Limitation Score) reduced from 100 to 21 points, while PROMIS Pain T-Score reduced from 71 to 53<sup>(6)</sup>.

### Discussion

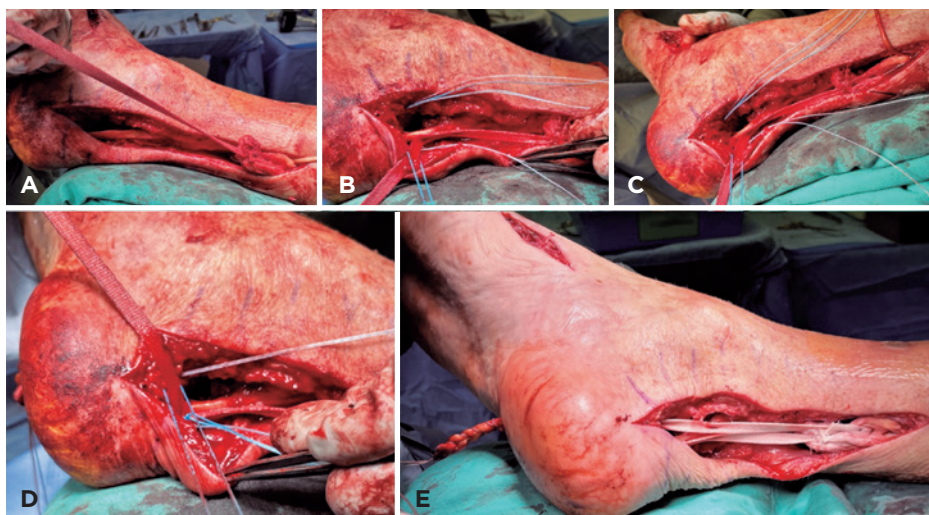
The treatment for chronic AT ruptures remains a challenge for orthopedic surgeons. Several reconstructive strategies are described to reestablish the muscle-tendon unit and avoid potential complications<sup>(2)</sup>. We demonstrated a technique that can minimize soft-tissue dissection and the morbidity of



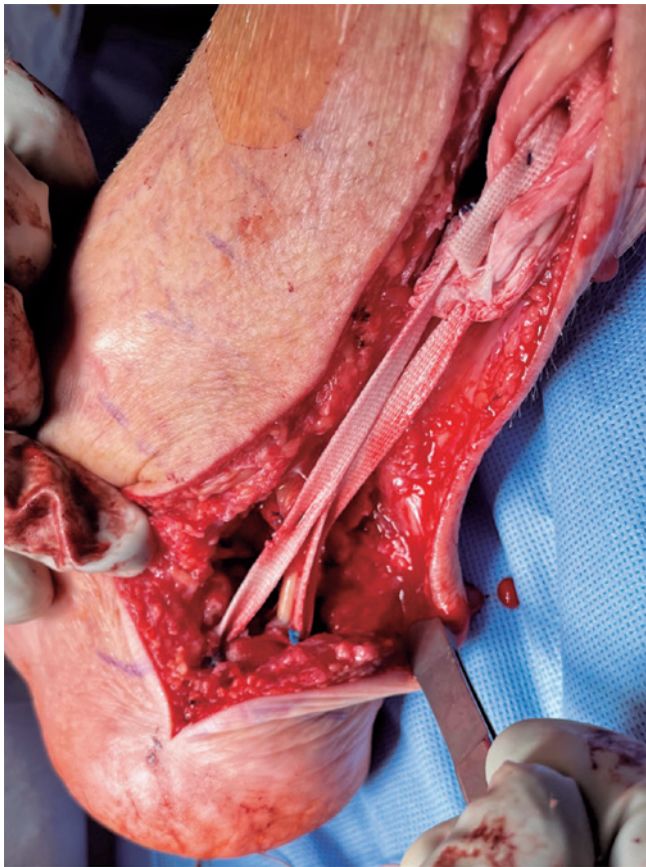
**Figure 2.** Remaining degenerated proximal fibers were resected (A). Scar tissue filling the space distally of the native ruptured AT was resected along with the plantaris (B). Achilles degenerations and calcifications were removed until good-quality tissue was found (pearly and shiny organized fibers) (C). The distance measured between the insertion and the proximal stump was 13cm (D).



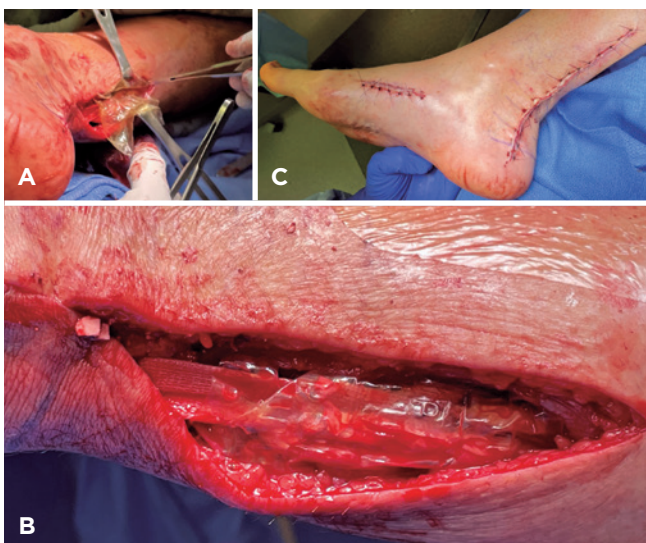
**Figure 3.** The FHL tendon and muscle belly were carefully dissected (A). The FHL tendon was identified and cut distally to Henry's knot (B) and retrieved proximally in the posteromedial wound measuring 5mm in diameter (C). The guidewire for an interference screw was placed centrally at the Achilles insertion footprint (D). The FHL tendon was inserted into the calcaneal tuberosity (E) and delivered to the plantar surface of the foot (F) while a 5.5mm interference screw secured its tensioned position.



**Figure 4.** A flexible 7mm x 32cm bioabsorbable synthetic graft band (Artelon™, Marietta, GA, USA) was woven into the proximal stump of Achilles with 0 Vicryl™ stitches (A). The construct was brought distally and sutured to the FHL tendon in tension with three interrupted horizontal mattresses (B). The biosynthetic graft was inserted to the calcaneal tuberosity (C) using two 2.9mm anchors, keeping the foot at 30° of plantar flexion (D). The remaining Artelon stump was then returned to the proximal Achilles native stump, where new Vicryl™ sutures were used to complete the construction (E).



**Figure 5.** Final appearance of the entire reconstruction with the proper ankle positioning.



**Figure 6.** The Achilles peritendon was protected (A) with a dehydrated human amnion/chorion membrane allograft (B). The subcutaneous tissue was closed with 3-0 Vicryl™ suture, and the skin with 4-0 nylon sutures in horizontal mattress fashion (C).

autograft harvesting while inserting a biological scaffold for native tendon healing.

Choosing a treatment strategy historically relies on the quality of the existing tendon, the gap size, muscle status, and the surgeon's comfort with each technique<sup>(1)</sup>. However, treatment algorithms focus solely on defect size<sup>(7,8)</sup>. Myerson<sup>(7)</sup> and Kuwada<sup>(8)</sup> developed two classification systems based on the tendon gap with a therapeutic impact. In chronic cases, the tendon gap corresponds to what remains after the complete debridement of the fibrous tissue to the viable ends of the tendon.

The primary goal of surgery is to restore proper length and tension to the triceps surae with healthy tissue<sup>(9)</sup>. In patients with chronic tears, tendon retraction, muscle atrophy, and severe tissue degeneration present an extra challenge to treatment, sometimes requiring augmentation with endogenous or exogenous material<sup>(2)</sup>. Preliminary studies suggest that tendon augmentation is an effective method to improve the strength of the repaired tendon. Using autografts or biological scaffolds of an allogenic or xenogenic base could be an option in this scenario<sup>(4,10)</sup>.

While autografts are associated with donor-site morbidity, there have been conflicting reports regarding the use of xenogenic scaffolds<sup>(4)</sup>. In addition, there are multiple reports of problems related to adverse reactions to this construction, failing the primary surgery, and the potential for multiple reoperations<sup>(4,10)</sup>. Synthetic scaffolds have thus been developed to overcome the disadvantages of existing biological scaffolds and to provide an alternative for tendon augmentation. In our case, with 12 months postop outcome, we used a flexible biocompatible, knitted mesh synthetic scaffold band derived from poly (urethane urea)<sup>(11)</sup>.

In a biomechanical study, Giza et al.<sup>(1)</sup> evaluated the strength added to an AT repair reinforced with this biosynthetic scaffold. The authors demonstrated superior mechanical properties of the group that used synthetic augmentation compared to the non-augmented group. The study argued that the biosynthetic is thinner, has the potential for fibroblast ingrowth, and has improved handling characteristics compared to a xenograft. Additionally, the graft has been included to facilitate healing via internal cell growth, angiogenesis, and neocollagenesis<sup>(1)</sup>.

Many authors advocate using a tendon transfer to protect the healing Achilles, bringing vascularity to the region and enhancing plantar flexion power<sup>(12)</sup>.

The FHL tendon is the most used donor for tendon transfer due to its biomechanical strength, phase of action, and line of pull<sup>(13)</sup>. Wapner et al.<sup>(14)</sup> described transferring the FHL tendon through a medial midfoot incision to the calcaneus, anterior to the Achilles insertion, with satisfactory results. Multiple techniques for fixation of the tendon to the calcaneus are described, including using bone tunnels, suture anchors, or an interference screw<sup>(14)</sup>.

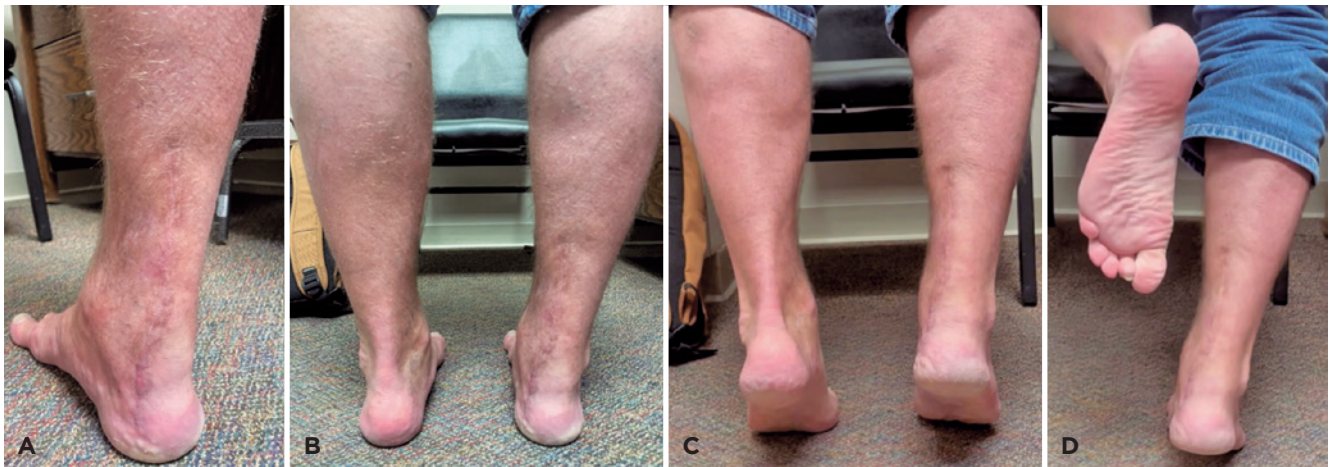
Martin et al.<sup>(15)</sup> observed that patients with chronic Achilles tendinosis treated with complete excision of the AT (distal 4

to 6 cm from the tendon), transfer, and anastomosis of the FLH tendon to the proximal stump of the AT, had a significant reduction in the level of pain and improved function. However, they had deficits in strength and range of motion in plantar flexion.

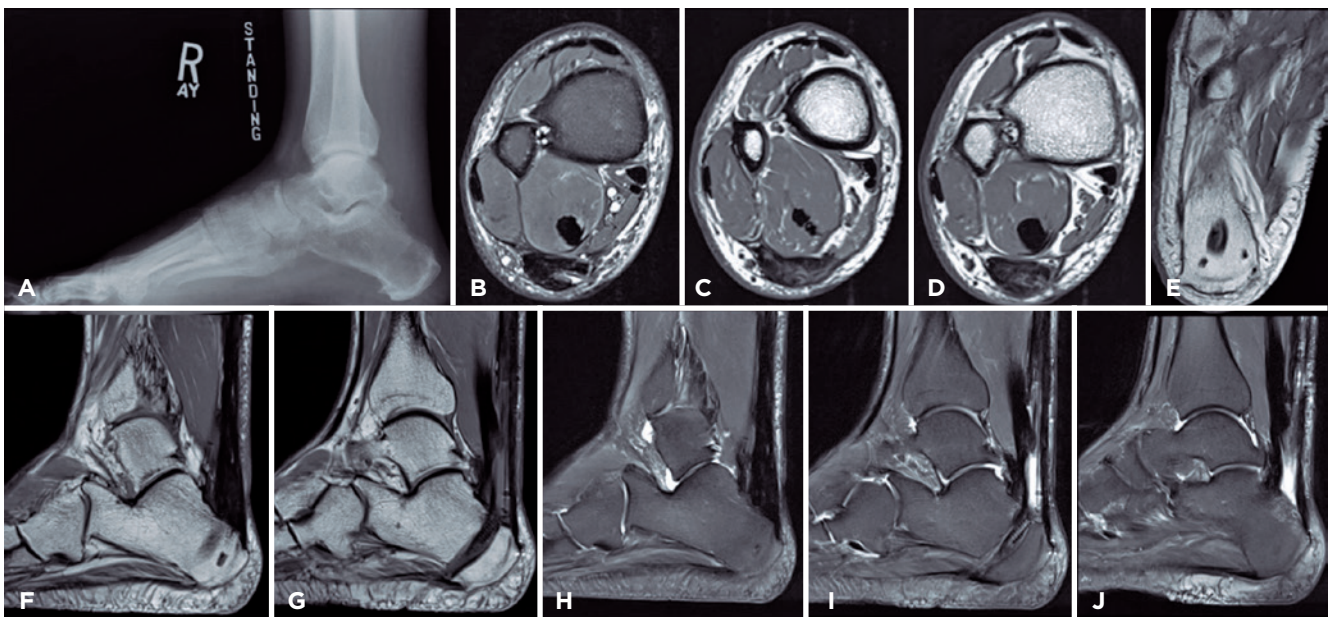
Schweitzer et al.<sup>(16)</sup>, in a literature review, found studies that support the use of synthetic materials in cases of extensive tearing because, according to these studies, the additional

strength provided by the initial reconstruction may allow earlier mobilization and a faster return to activity. However, there are still minimal long-term data in the current literature on the specific application of these materials in the foot and ankle<sup>(16)</sup>.

In addition, we must consider the costs of using these materials and concerns about using unabsorbable material in a region prone to contracture and soft-tissue compromise, wound formation, and infection.



**Figure 7.** Clinical images with 12 months follow-up. Posteromedial view of the right hindfoot (operated side) (A). Bilateral standing posterior view (B). Posterior view with the patient in heel-raise position and with a right-side monopodal support (D).




**Figure 8.** Postoperative imaging assessment. The three months postoperative lateral radiograph (A) demonstrated good tunnel position and no lysis. The MRI after 12 months depicted good gastrocnemius appearance and FHL muscle hypertrophy on axial views (B, C, D). Tunnel and anchors positioning are also shown (E). Sagittal MRI demonstrates good healing on proximal and distal attachments of the biosynthetic graft (F, H, J). FHL placement and its relationship with the reconstructed AT are also exhibited (G, I).

We added FHL transfer anteriorly to the biosynthetic graft reconstruction in our technique to potentialize healing and postoperative strength. There were no complications, and the patient presented a good recovery, showing good functional results.

## Conclusion

Achilles tendon reconstruction with the biosynthetic flexible band proved feasible for massive tendon defects by inserting a biological scaffold for native tendon healing, improving postoperative recovery and strength.

**Authors' Contribution:** Each author contributed individually and significantly to the development of this article: KAMC \*(<https://orcid.org/0000-0003-1082-6490>) Conceived and planned the activities that led to the study, wrote the paper, interpreted the results of the study, statistical analysis, formatting of the article, participated in the reviewing process, bibliographic review, approved the final version; ES \*(<https://orcid.org/0000-0002-6922-5238>) Data collection, interpreted the results of the study, participated in the reviewing process; AE \*(<https://orcid.org/0000-0001-6180-4780>) Data collection, interpreted the results of the study, participated in the reviewing process; KCK \*(<https://orcid.org/0000-0002-3731-8448>) Interpreted the results of the study, participated in the reviewing process; NSBM \*(<https://orcid.org/0000-0003-1067-727X>) and CCN\* (<https://orcid.org/0000-0001-6037-0685>) Data collection, participated in the reviewing process, approved the final version. All authors read and approved the final manuscript. \*ORCID (Open Researcher and Contributor ID) 

## References

1. Giza E, Frizzell L, Farac R, Williams J, Kim S. Augmented tendon Achilles repair using a tissue reinforcement scaffold: a biomechanical study. *Foot Ankle Int.* 2011;32(5):S545-9.
2. Ellison P, Mason LW, Molloy A. Chronic Achilles tendon rupture reconstructed using hamstring tendon autograft. *Foot (Edinb).* 2016;26:41-4.
3. Padanilam TG. Chronic Achilles tendon ruptures. *Foot Ankle Clin.* 2009;14(4):711-28.
4. Gersoff WK, Bozynski CC, Cook CR, Pfeiffer FM, Kuroki K, Cook JL. Evaluation of a novel degradable synthetic biomaterial patch for augmentation of tendon healing in a large animal model. *J Knee Surg.* 2019;32(5):434-40.
5. Maffulli N, Aicale R, Tarantino D. Autograft reconstruction for chronic achilles tendon disorders. *Tech Foot Ankle Surg.* 2017; 16:117-23.
6. Cella D, Yount S, Rothrock N, Gershon R, Cook K, Reeve B, et al. The Patient-Reported Outcomes Measurement Information System (PROMIS): progress of an NIH Roadmap cooperative group during its first two years. *Med Care.* 2007;45(5 Suppl 1):S3-S11.
7. Myerson MS. Achilles tendon ruptures. *Instr Course Lect.* 1999; 48:219-30.
8. Kuwada GT. An update on repair of Achilles tendon rupture. *Acute and delayed.* *J Am Podiatr Med Assoc.* 1999;89(6):302-6.
9. Galloway MT, Lalley AL, Shearn JT. The role of mechanical loading in tendon development, maintenance, injury, and repair. *J Bone Joint Surg Am.* 2013;95(17):1620-8.
10. Longo UG, Lamberti A, Maffulli N, Denaro V. Tendon augmentation grafts: a systematic review. *Br Med Bull.* 2010;94:165-88.
11. Gisselgård K, Edberg B, Flodin P. Synthesis and properties of degradable poly(urethane urea)s to be used for ligament reconstructions. *Biomacromolecules.* 2002;3(5):951-8.
12. Mansur NSB, Fonseca LF, Matsunaga FT, Baumfeld DS, Nery CAS, Tamaoki MJS. Achilles Tendon Lesions - Part 2: Ruptures. *Rev Bras Ortop (Sao Paulo).* 2020;55(6):665-72.
13. Chen C, Hunt KJ. Open Reconstructive Strategies for Chronic Achilles Tendon Ruptures. *Foot Ankle Clin.* 2019;24(3):425-37.
14. Wapner KL, Pavlock GS, Hecht PJ, Naselli F, Walther R. Repair of chronic Achilles tendon rupture with flexor hallucis longus tendon transfer. *Foot Ankle.* 1993;14(8):443-9.
15. Martin RL, Manning CM, Carcia CR, Conti SF. An outcome study of chronic Achilles tendinosis after excision of the Achilles tendon and flexor hallucis longus tendon transfer. *Foot Ankle Int.* 2005;26(9):691-7.
16. Schweitzer KM Jr, Dekker TJ, Adams SB. chronic Achilles ruptures: reconstructive options. *J Am Acad Orthop Surg.* 2018;26(21):753-63.