

## Case Report

# Subungual tumor of the hallux: a diagnostic challenge

Talissa Oliveira Generoso<sup>1</sup> , José Felipe Marion Alloza<sup>1</sup> , Renée Zon Filippi<sup>1</sup> , Reynaldo Jesus-Garcia Filho<sup>1,2</sup> 

1. Hospital Israelita Albert Einstein, São Paulo, SP, Brazil.

2. Department of Orthopedics and Traumatology, Paulista School of Medicine. Federal University of Sao Paulo, São Paulo, SP, Brazil.

## Abstract

Subungual tumors of the hallux are rare, with a varied spectrum of differential diagnoses, and it may be challenging to reach the correct diagnosis. Depending on the health system where the patient will be treated, the specialist physician may follow different paths in the search for pathological definitions, which may lead to delays in obtaining the diagnosis and even to mistaken results. We present a case of a patient with a subungual tumor of the hallux, which represents the singular process above, aiming to demonstrate relevant differential diagnoses, determining factors for the correct diagnosis, and the importance of pathological elucidation for its proper treatment so that the outcomes for the patient are prevented.

**Level of Evidence V; Case Report; Expert Opinion.**

**Keywords:** Bone neoplasms; Hallux; Oncology; Orthopedic.

## Introduction

Subungual tumors of the hallux are rare, with a varied spectrum of differential diagnoses, and it may be challenging to reach the correct diagnosis. Depending on the health system where the patient will be treated, the specialist physician may follow different paths in the search for pathological definitions, which may lead to delays in obtaining the diagnosis and even to mistaken results<sup>(1,2)</sup>.

We present a case of a patient with a subungual tumor of the hallux initially diagnosed and treated as superficial acral fibromyxoma. After an unsatisfactory outcome with recurrence and progressive nail deformity, suspicions of subungual exostosis and bizarre parosteal osteochondromatous proliferation (BPOP), or Nora's lesion, were raised.

The objective of this report is to present relevant differential diagnoses of subungual tumors of the hallux, determining factors for the correct diagnosis, and the importance of pathological elucidation for its appropriate treatment so that the outcomes for the patient, such as onychodystrophy and even amputation, are prevented.

## Case description

The study was approved by the institution's ethics committee, and the informed consent form was signed.

A 15-year-old male presented to a dermatologist's office complaining of a subungual lesion in the left hallux. The patient denied episodes of trauma and reported rapid lesion growth, with nail deformity due to elevation of subungual mass, without pain. A biopsy was performed by superficial scraping, with an anatomopathological result of the fibroblastic proliferation of reaction pattern, with myxoid areas without atypia. The immunohistochemical profile was positive for CD99 and smooth muscle actin, suggestive of superficial acral fibromyxoma (Figure 1).

Initially treated with superficial excision, the lesion presented new growth with progressive nail deformity. The patient underwent a radiographic examination and was referred for consultation with a foot specialist orthopedic surgeon. The radiograph showed ossification near the hallux's dorsomedial end of the distal phalanx, measuring 1cm, associated with sclerosis and phalanx irregularities (Figure 2).

The clinical evolution associated with imaging suggested differential diagnoses, such as subungual exostosis, Nora's lesion, and subungual osteochondroma. Therefore, surgical treatment was then performed with excision of the lesion (Figures 3 and 4), as follows: 1) incision of the medial, anterior, and lateral region of the left hallux, above the midline in the longitudinal plane; 2) dissection of the tissues to the tumor's base in the phalanx and the subungual bed superiorly; 3) dis-

Study performed at the Hospital Israelita Albert Einstein, São Paulo, SP, Brazil.

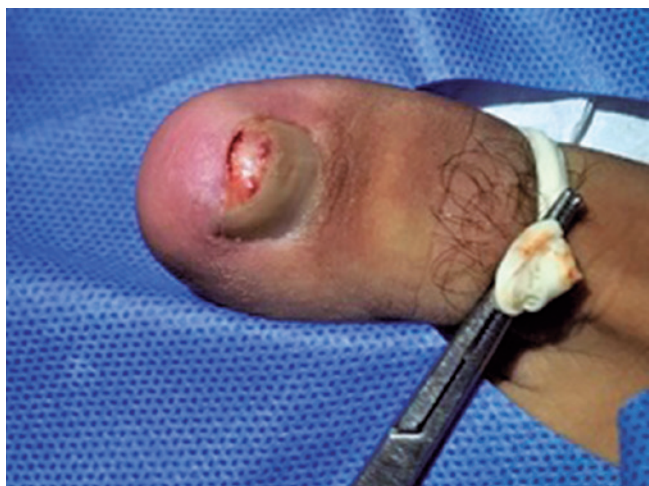**Correspondence:** Talissa Oliveira Generoso. Hospital Israelita Albert Einstein, 627, Albert Einstein Av., Room 310, A1 Block, Jardim Leonor, 05652-900, São Paulo, SP, Brazil. **E-mail:** talissa.generoso@outlook.com. **Conflicts of interest:** none. **Source of funding:** none. **Date received:** November 17, 2022. **Date accepted:** December 13, 2022. **Online:** December 20, 2022.



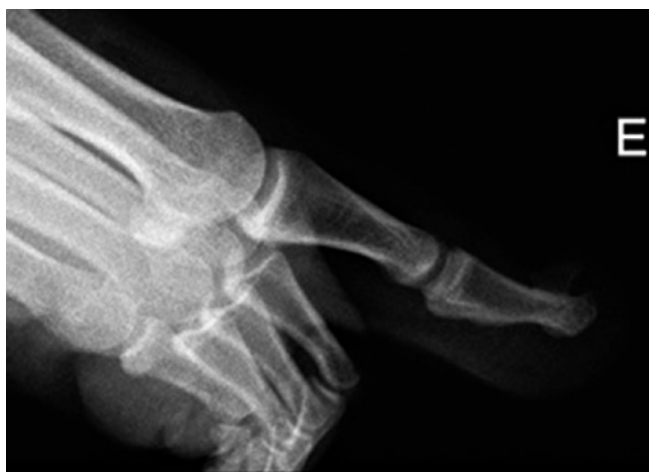section of the whole exostosis base; 4) control with radiocopy and osteotomy with microdrill of the exostosis base; 5) lesion resection; 6) intraoperative histopathological analysis of the lesion - without malignancy characteristics; 7) regularization of the phalanx base; 8) skin and flap closing between the nail and the skin; 9) dressing; and 10) use of footwear with forefoot wedge in the postoperative period.

The detailed anatomopathological report characterized the lesion as bone neof ormation partially covered by cartilage without atypia, with nail erosion, associated acute inflammatory process, histiocytic reaction around hemorrhage (previous biopsy site), foci of fibrosis, myxoid degeneration and ischemic necrosis in adjacent connective tissue, without morphological evidence of malignancy, concluding by bone exostosis.

The patient evolved well, with good wound healing and no lesion recurrence to date (Figure 5).



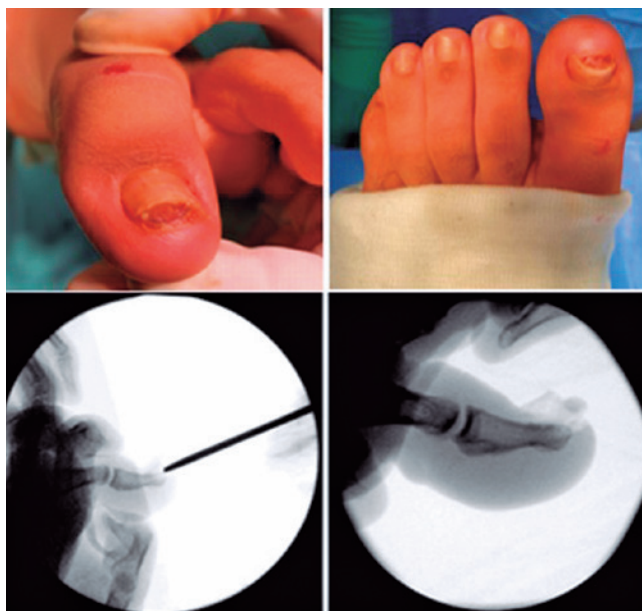**Figure 1.** Subungual lesion of the left hallux at the time of the first biopsy by superficial scraping.



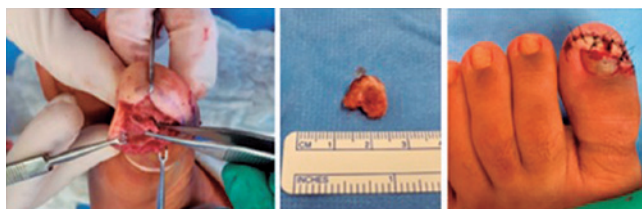
**Figure 2.** Left hallux radiograph.

## Discussion

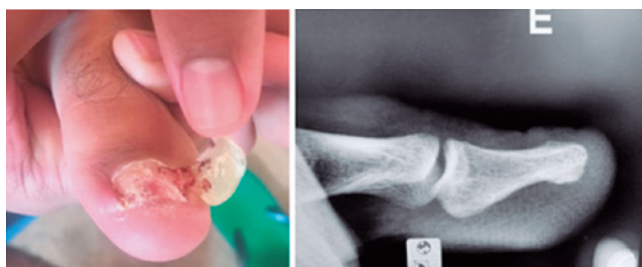Subungual tumors of the hallux are uncommon lesions that present a wide spectrum of differential diagnoses, such as subungual exostosis, subungual osteochondroma, BPOP or Nora's lesion, superficial acral fibromyxoma, glomus tumor, onychomycosis, and pyogenic granuloma. The patient can seek help in different areas of medicine, such as dermatology, orthopedics, and oncology, or from non-medical health professionals, such as podiatrists. Therefore, varied approaches



**Figure 3.** Steps of the surgical approach.



**Figure 4.** Lesion resection and wound regularization.



**Figure 5.** Two months postoperative.

can lead to delayed diagnosis or even mistaken results. It is relevant to analyze the main differential diagnoses for subungual lesions of the hallux that were investigated in this case report and determine factors in the investigative process.

### Superficial acral fibromyxoma

Superficial acral fibromyxoma is a rare benign soft tissue tumor, more common in patients in the fifth decade of life, with a mean age of 43 years, affecting more males in a 2:1 ratio to females<sup>(1,2)</sup>. It is usually located on the tips of the fingers and toes, preferably subungual or periungual, and the hallux is the most affected digit<sup>(3)</sup>.

It appears as a slow-growing solitary nodule, reaching mean dimensions of 0.6 to 5 cm, and painless in most cases<sup>(1,4)</sup>. On histological analysis, it is described as a myxoid tumor with spindle-shaped, stellate cells and fibroblasts, usually confined to the dermis and subcutaneous tissue. It may also involve deeper tissues, causing erosion of the underlying bone limited to the cortical bone, without tumor calcification, a characteristic lesion that can be visualized on radiographs<sup>(2,4)</sup>. Magnetic resonance imaging usually presents hypointense signal on T1-weighted sequences and a hyperintense signal on T2-weighted<sup>(5)</sup>. On immunohistochemical analysis, it is reactive for CD34, CD99, and epithelial membrane antigen, being negative for S100, which distinguishes it from myxoid neurofibroma<sup>(1)</sup>.

The treatment of superficial acral fibromyxoma should be conducted with its complete excision to prevent recurrence<sup>(1)</sup>.

### Nora's lesion

Bizarre parosteal osteochondromatous proliferation, described by Nora in 1983, is a rare benign tumor lesion, with just over 100 cases reported in the literature. Although its etiology is not yet fully defined, it is believed to be associated with genetic alterations, such as translocation t(1:17)(q32;q21)<sup>(5)</sup>. It usually presents as a fast-growing nodule for weeks to months, painless or slightly painful. It is preferentially located in the hands and feet of young adults in the third decade of life, especially in the phalanges, metacarpals and metatarsals, with no preference for gender<sup>(5,6)</sup>.

Morphologically, it appears as a mass of heterotopic mineralization that rises from the periosteal or intact cortex without medullary involvement, presenting a nodular surface covered by metaplastic cartilage<sup>(7)</sup>. There are osteoblasts irregularly disposed in the bony trabeculae, along with bizarre fibroblasts between the trabeculae<sup>(6)</sup>. Magnetic resonance imaging is characterized as a low-signal lesion on T1-weighted sequences and a low-intermediate signal on T2-weighted, without periosteal reaction and gadolinium enhancement. When it is not completely resected, it presents a high local recurrence rate, reaching up to 55% of the cases<sup>(5,6)</sup>.

### Subungual exostosis

An important diagnosis is a subungual exostosis, a rare benign tumor late diagnosed in about 10% of cases, with reports in the literature showing a significant interval of two months to four years from the onset of symptoms until the correct lesion elucidation<sup>(8)</sup>.

Initially described by Dupuytren in 1817, this benign tumor affects patients more frequently in the second and third decades of life, with no difference between genders. It is a slow-growing solitary mass, usually painful, with progressive involvement of the nail and nail bed and a preference for hallux in about 80% of cases. There are no reports of malignant transformation<sup>(9)</sup>.

Its etiology is still uncertain, and its development may be related to traumas, infections, tumors, hereditary factors, and the translocation t(X;6)(q22; q13-14)<sup>(8,9)</sup>.

On physical examination, it may present as a fixed subungual nodule with a hyperkeratotic surface in the distal region of the nail<sup>(8)</sup>. In subungual exostosis, the formed bone originates from fibrous tissue and does not present continuity with the cortical or medullary bone, having a fibrocartilage cover, an important characteristic that differentiates it from osteochondroma<sup>(8,9)</sup>. On radiographical examination, there is no bone destruction or periosteal reaction<sup>(10)</sup>.

### Subungual osteochondroma


An important differential diagnosis of subungual exostosis is subungual osteochondroma. Osteochondroma is the most common benign bone neoplasm, corresponding to 10-15% of all bone tumors; however, its subungual form is rare<sup>(10)</sup>. The latter affects the hallux in 45% of cases and the other toes in most other cases.

It is presented as a bone mass derived from endochondral ossification, pedunculated or sessile, continuous with the cortical and bone marrow, and hyaline cartilage<sup>(9,10)</sup>.

For both subungual exostosis and osteochondroma, removing the entire lesion to its base, with its curettage until visualization of the cancellous bone, is recommended to avoid recurrence. The nail bed should be preserved whenever possible<sup>(9,10)</sup>.

### Conclusion

Subungual tumors are rare lesions with a wide spectrum of differential diagnoses. For diagnostic investigation, imaging exams and pathological examinations are of great value and should be used to perform early appropriate treatment and prevent harm to the patient.

**Authors' contributions:** Each author contributed individually and significantly to the development of this article: TOG \*(<https://orcid.org/0000-0001-9277-7746>) Wrote the article, participated in the review process and approved the final version; JFMA \*(<http://orcid.org/0000-0002-7664-2064>) Conceived and planned the activities that led to the study, wrote the article, participated in the review process and approved the final version; RZF \*(<https://orcid.org/0000-0002-2589-1183>) Conceived and planned the activities that led to the study, approved the final version; RJGF \*(<http://orcid.org/0000-0001-7895-5729>) Conceived and planned the activities that led to the study, wrote the article, participated in the review process and approved the final version. All authors read and approved the final manuscript. \*ORCID (Open Researcher and Contributor ID) 

---

## References

1. Bindra J, Doherty M, Hunter JC. Superficial acral fibromyxoma. *Radiol Case Rep.* 2015;7(3):751.
2. Hashimoto K, Nishimura S, Oka N, Tanaka H, Kakinoki R, Akagi M. Aggressive superficial acral fibromyxoma of the great toe: A case report and mini-review of the literature. *Mol Clin Oncol.* 2018;9(3):310-4.
3. Lee S, Reid MAR. Superficial acral fibromyxoma: a case report with radiological review. *Skeletal Radiol.* 2018;47(7):1021-8.
4. Varikatt W, Soper J, Simmons G, Dave C, Munk J, Bonar F. Superficial acral fibromyxoma: a report of two cases with radiological findings. *Skeletal Radiol.* 2008;37(6):499-503.
5. James A, Henderson S. Multiple recurrences of subungual exostosis in a child: a unique presentation of a Nora's lesion. *Foot Ankle Int.* 2013;34(3):445-7.
6. Mohammad A, Kilcoyne A, Blake S, Phelan M. Second toe swelling: Nora's lesion or glomus tumour, case report and literature review. *Ir J Med Sci.* 2012;181(3):357-60.
7. Dhondt E, Oudenhoven L, Khan S, Kroon HM, Hogendoorn PC, Nieborg A, et al. Nora's lesion, a distinct radiological entity? *Skeletal Radiol.* 2006;35(7):497-502.
8. DaCambra MP, Gupta SK, Ferri-de-Barros F. Subungual exostosis of the toes: a systematic review. *Clin Orthop Relat Res.* 2014;472(4):1251-9.
9. Göktay F, Atış G, Güneş P, Macit B, Çelik NS, Gürdal Kösem E. Subungual exostosis and subungual osteochondromas: a description of 25 cases. *Int J Dermatol.* 2018;57(7):872-81.
10. Lee SK, Jung MS, Lee YH, Gong HS, Kim JK, Baek GH. Two distinctive subungual pathologies: subungual exostosis and subungual osteochondroma. *Foot Ankle Int.* 2007;28(5):595-601.