

Original Article

Correlation between the region of interest in digital radiography, Hounsfield units, and histological maturation on Wistar rats submitted to tibial fracture

Eduardo de Oliveira Carrilho Padula¹ , Lucas Alves Sarmiento Pires² , Marcio Antonio Babinski² 

1. Serviço de Cirurgia do Pé e Tornozelo, Hospital Municipal Lourenço Jorge, Rio de Janeiro, RJ, Brazil.

2. Experimental Morphology Laboratory, Morphology Department, Fluminense Federal University, Niteroi, RJ, Brazil.

Abstract

Objective: Study the relationship between the region of interest (ROI) and Hounsfield units (HU) in the tibial bone callus.

Methods: Twenty-one adult Wistar rats were submitted to tibial fracture. The fracture was radiographed after their euthanasia, and the bone calluses were analyzed histologically after being stained with hematoxylin and eosin. Euthanasia occurred between the 2nd and 6th weeks after fracture and fixation, thus obtaining various consolidation stages. Histologically, vessels, chondroblasts, connective tissue (collagen), maximum size of the chondrocyte, and the concentration of chondrocytes were quantified.

Results: It was observed that the higher the HU, the more mature and closer to bone consolidation it is, proving that the use of ROI and bone callus measurement with HU is reliable for the histological process of maturation of the bone callus and can be safely used as proof of evolution of the bone healing process.

Conclusion: The ROI was successfully used in digital radiography to observe HU in fractured bones.

Level of Evidence IV; Therapeutic Studies; Case Series.

Keywords: Fracture healing; Digital radiography; Hounsfield units; Histomorphometry.

Introduction

The fracture healing process is complex and carefully coordinated, having evolved over eons as an essential adaptation for the survival of healthy individuals⁽¹⁾.

The bone consolidation process and its stages have been studied over the years. These studies are evaluated using invasive and traumatic techniques, often requiring the death of the individual being evaluated. The use of radiographs and computed tomography (CT) scans to assess the evolution of the bone callus until final healing (complete consolidation) has been used thanks to the Hounsfield units (HU)^(2,3).

These units are a relative quantitative measure of radio-density used by radiologists in interpreting images. The

absorption/attenuation coefficient of radiation within a tissue produces a grayscale image. The physical density of the tissue is proportional to the absorption/attenuation of the radiograph beam; that is, the denser it is, the more HU a tissue has. The HU analysis is used to identify pathologies in the most diverse types of tissues, such as liver⁽⁴⁾, bone⁽⁵⁾, vascular⁽⁶⁾, and renal⁽⁷⁾, among others, due to its objective method rather than a subjective one.

Interest in studying the bone healing process has increased over time due to several factors, particularly the significant increase in metabolic bone diseases and a concomitant increase in fragility fractures, both because of these diseases and the longer life expectancy⁽⁸⁾.

Study performed at the Serviço de Cirurgia do Pé e Tornozelo, Hospital Municipal Lourenço Jorge, Rio de Janeiro, RJ, Brazil.

Correspondence: Eduardo de Oliveira Carrilho Padula. Av. Ayrton Senna, 2.000, Barra da Tijuca, Rio de Janeiro, RJ, Brazil. **Email:** eocpadula@hotmail.com

Conflicts of interest: None. **Source of funding:** None. **Date received:** November 25, 2023. **Date accepted:** March 1, 2024. **Online:** April 30, 2024.

How to cite this article: Padula EOC, Pires LAS, Babinski MA. Correlation between the region of interest in digital radiography, Hounsfield units, and histological maturation on Wistar rats submitted to tibial fracture. *J Foot Ankle.* 2024;18(1):46-51.

The region of interest (ROI) means a specific area of interest of the radiograph that will be submitted to analysis without interference from the rest; that is, it will be processed separately in the computer^(9,10). As the search for new parameters to evaluate bone consolidation is essential to avoid costly and unnecessary methods, the objective of the study is to verify a possible relationship between HU and bone callus maturity through an ROI analysis of the fractured tibia of Wistar rats.

Methods

Ethical aspects

The study was performed at the Laboratory of the Urogenital Research Unit of the Universidade Estadual do Rio de Janeiro (UERJ).

The handling of the animals followed the principles described in The Guide for the Care and Use of Laboratory Animals⁽¹¹⁾, CIOMS ethical code for animal experimentation⁽¹²⁾, and Use of animals in experimental surgery⁽¹³⁾. This study was approved by the Ethics Committee for the care and use of experimental animals of the Instituto de Biologia Roberto Alcântara Gomes of the Universidade Estadual do Rio de Janeiro (CEUA/O20/2021). This study was conducted in accordance with the ARRIVE 2.0 guidelines⁽¹⁴⁾.

Animal model and sampling

Adult 90-day-old Wistar rats (*Rattus norvegicus albinus*) were used. The sample size was chosen as five animals per minimum in accordance with other experimental studies in rats with this timeframe (4 weeks); thus, the chosen sample was by convenience. In total, 25 animals were included; however, only 21 animals were analyzed, as four died due to complications during anesthesia.

Determining the time of analysis

To evaluate the healing process of fractures in their different evolutionary stages, 21 animals were used. The distribution and selection of the animals was performed by probabilistic allocation using a simple draw without replacement and they were sacrificed between two and six weeks after the fracture.

Production of fractures

The animals were anesthetized using ketamine hydrochloride (Laboratório Pfizer Ltda., São Paulo, SP, Brazil) at a dose of 40 mg/kg/weight associated with xylazine (Virbax® 2%, Virbac do Brasil, Jurubatuba, SP, Brazil) at a dose of 5 mg/kg/weight, intramuscular injection in the medial surface of the animal's right thigh. Animals that presented regular breathing, flaccid skeletal muscles and absence of reflexes were considered anesthetized.

A metallic wire of 1 mm in diameter was introduced into the medullary canal of the tibias⁽¹⁵⁾, and subsequent production of the fracture in the middle third of the two tibias of the rats

mechanically (7.5 joules per cm²) with a guillotine (Figure 1), with three support points on the diaphysis described by An et al. (1994)⁽¹⁶⁾, similar in terms of trait and without exposure to the external environment, after realigning the fragments, thus facilitating the histological cuts. With clinical evidence of the fracture, that is, mobility in the focus, and radiological control (Figure 2); after recovery from anesthesia, the animals were placed back in the previously identified boxes, with water and food ad libitum.

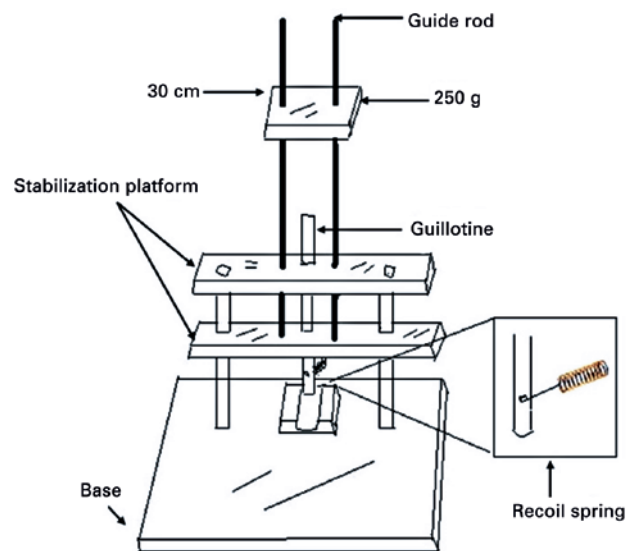


Figure 1. Schematic model of the guillotine.

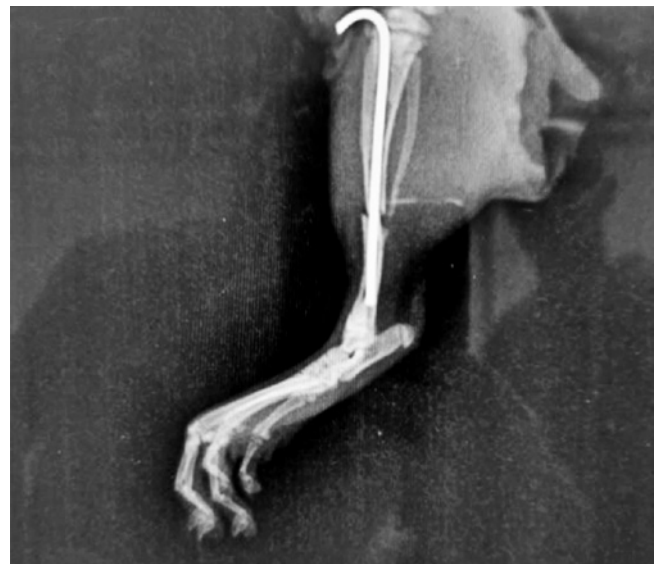

Figure 2. Radiological control after fracture.

Between two and six weeks, the animals were sacrificed using ketamine at a dose of 50 mg/kg/weight associated with xylazine at a dose of 10 mg/weight. kg/weight, intraperitoneally.

Histopathological analysis

After euthanasia (inhalation of isoflurane followed by exsanguination), the tibias were removed by means of disarticulation at the ankles and knees. The tibias were dissected, maintaining the periosteum envelope around the fracture focus. The surgical instruments used during this procedure were disinfected using a 2% glutaraldehyde solution for 30 minutes. All organs were harvested for other studies regarding stress fractures and the animals remains were incinerated.

The pieces obtained were fixed for 48 hours in a formalin solution (10% formaldehyde, 37%, 0.65% Na₂HPO₄, pH7.2). Initially, the pieces were washed in running water and demineralized in EDTA for 48 hours, after these 48 hours the tibias were longitudinally sectioned and returned to the EDTA for another 24 hours to complete the demineralization. Then, the pieces were washed again in running water, the bone ends without bone callus were removed, the bone callus region was then dehydrated in 70%, 80%, 90% and 100% alcohol baths, cleared in xylol and included in paraffin. The material was sectioned on an RM2125RT microtome (Leica, Heerbrugg, St.Gallen, Switzerland) obtaining consecutive 5 μ sections, which were stained with Hematoxylin & Eosin (HE).

Vertical sections of the fracture site were analyzed using an optical microscope at 200X magnification and adapted to a digital camera. Histomorphometric analysis was performed, evaluating the area of the bone callus, quantifying vessels, chondrocytes, connective tissue (collagen) and the maximum size of the chondrocyte, as well as the concentration of chondrocytes in each animal. For this analysis, the Image J software (National Institutes of Health, USA) was used.

Digital radiographic analysis

The radiographic examinations were performed in the same day of the euthanasia and processed in the radiology sector of the Hospital Universitário Pedro Ernesto (HUPE) with all radiological safety standards respected. All paws were identified with animal number and laterality (Figure 3).

The images were analyzed using the RadiAnt viewer (with Anvisa approval) applying a ROI, a surrounding ellipse capable of reading and measuring the HU, in the tibial fracture zone. To normalize the measurement, the HU value was reduced from the most hypodense point on the screen, thus analyzing the anterior region of the callus (area of mechanical tension) and the posterior part of the callus (area of compression), thus allowing a analysis whether the changes were proportional in the two regions that are mechanically distinct (Figure 4).

Statistical analysis

Descriptive statistical analysis (mean and standard deviation) was performed. Spearman's correlation test was

performed to verify correlations between the HU value and the mean percentage of collagen, vessels, intermediate connective tissue, calcium, and chondrocytes.

For all analyses, a p value < 0.05 was considered significant and the SPSS 23 software was used to perform the statistical analysis.

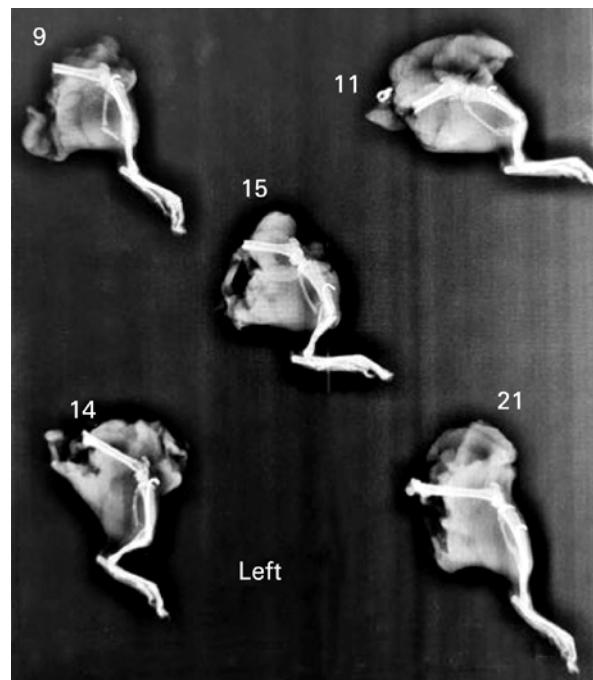


Figure 3. Radiological image of the animals and the side of their fracture.

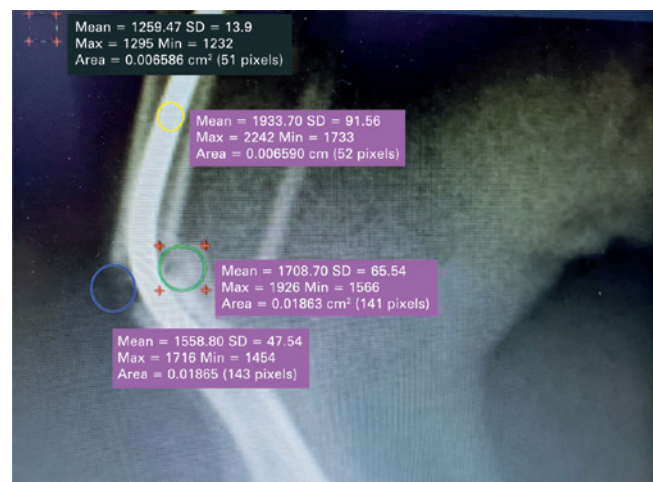


Figure 4. Region of interest.

Results

No rats died of complications during surgery, fracture procedure or implant. There were no adverse events throughout the study.

It was observed that the higher the HU, the lower the concentration of connective tissue with collagen (Figure 5) albeit without statistical significance ($p = 0.13$), the greater the intermediate connective tissue, the greater the HU, without statistical significance ($p = 0.10$) (Figure 6). The HU levels were significantly proportionate with calcium levels ($p = 0.01$) (Figure 7). When evaluating the concentration of chondrocytes, the same pattern found in collagen was identified, the lower the concentration of chondrocytes, the greater the HU with statistical significance ($p = 0.003$) (Figure 8) and when quantifying the blood vessels, it was verified that the HU is not significantly ($p = 0.29$) altered proportionally with its concentration, presenting only a tendency for the HU to increase as the concentration of vessels decreases (Figure 9).

The histological findings showed osteoblasts, connective tissue, and vessels compatible with the bone healing process (Figure 10).

Discussion

Fractures are one of the most common medical events in the general population. Failure in the healing process leads to nonunion, and account to 5% to 10% of long bones fractures. It leads to financial impact due to longer hospital stay, more complex surgeries, increased prescriptions, and overall healthcare resources utilization⁽¹⁷⁾.

Bone healing is a well-known and described process which is affected by several factors: nutrition, age, comorbidities.

Histological analysis of a bone healing slide typically reveals different stages of the healing process, depending on the time

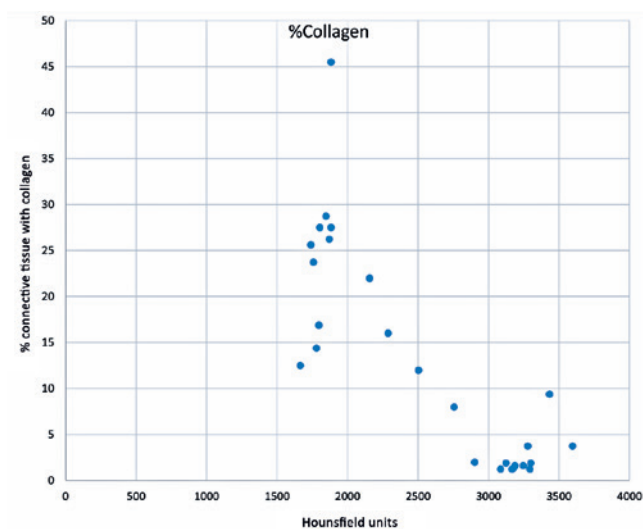


Figure 5. Mean percentage of collagen and its relation to Hounsfield units.

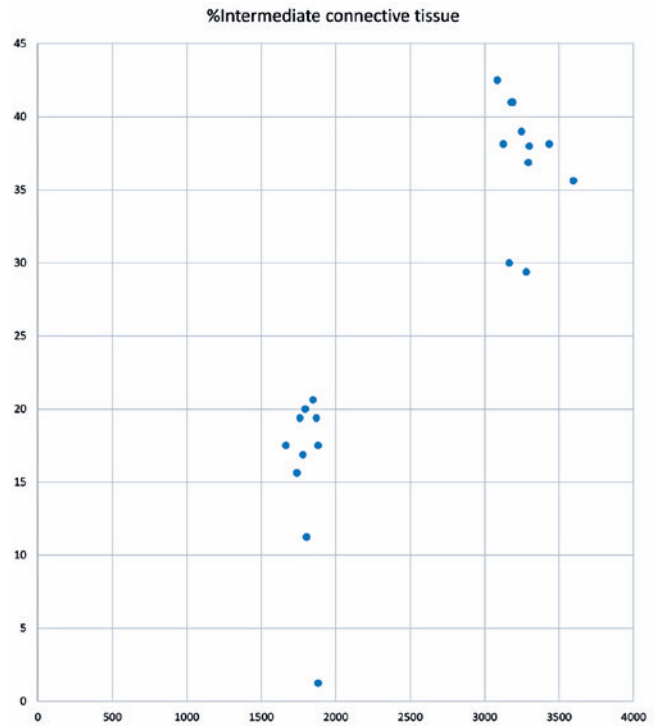


Figure 6. Mean percentage of intermediate connective tissue and its relation to Hounsfield units.

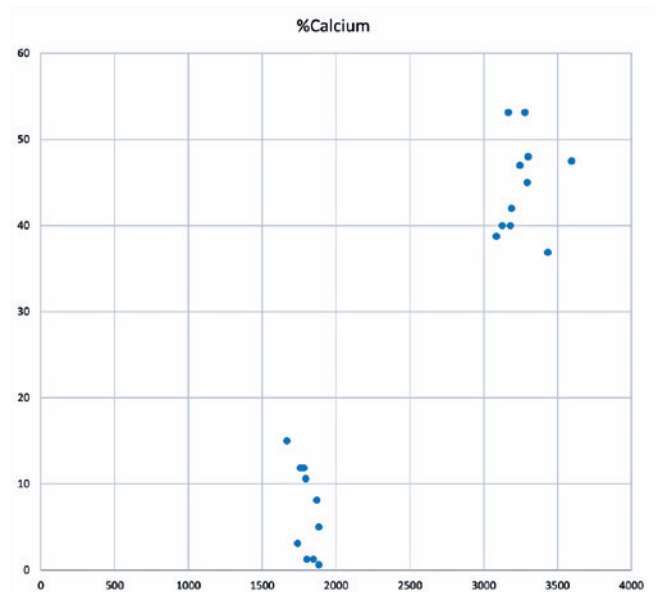


Figure 7. Mean percentage of calcium and its relation to Hounsfield units.

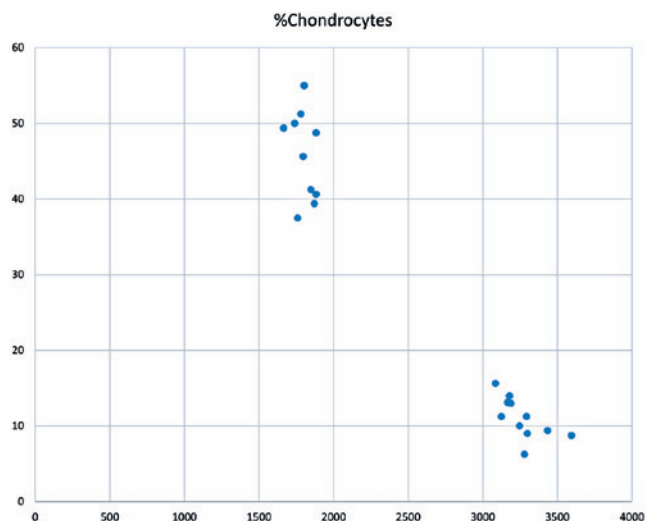


Figure 8. Mean percentage of chondrocytes and its relation to Hounsfield units.

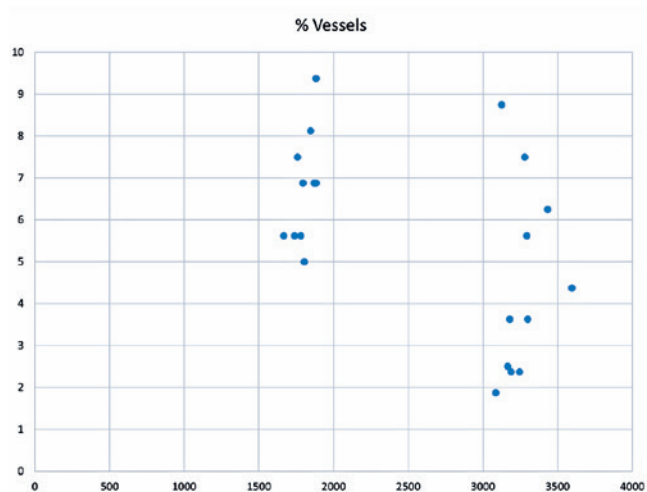


Figure 9. Mean percentage of vessels and its relation to Hounsfield units.

elapsed since the fracture occurred. Initially, there is signs of acute inflammatory process: This stage typically occurs in the first few days after the fracture and is characterized by the presence of inflammatory cells, such as neutrophils and macrophages, in the fracture site⁽¹⁸⁾.

Then, there is the formation of a soft callus, around one to two weeks after the fracture and a callus made of cartilage and collagen is seen. The third phase is the hard callus stage (woven bone), which happens three to four weeks after the fracture, here, ossification of the soft callus can already be seen. Finally, the last step is the remodeling phase, which can

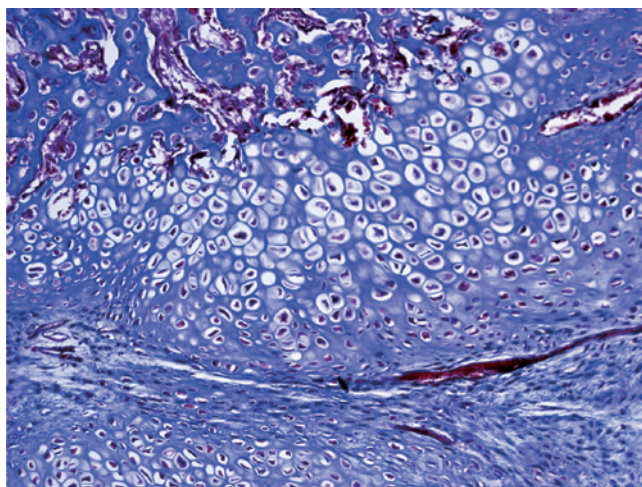


Figure 10. Histological slide of the second week of bone healing process. Chondrocytes, vessels, and abundant connective tissue can be seen. (Hematoxylin/Eosin, 200X).

take months after the fracture and there a reshaping of the bone tissue—the callus is replaced by newformed bone. During bone healing, blood vessels and bone-forming cells, such as osteoblasts and osteoclasts, as well as the organization and alignment of the bone tissue are also observed in the histological evaluation. As the healing process progresses, the bone callus gradually becomes denser as it is replaced by new bony tissue⁽¹⁸⁾.

In the context of bone healing, HU can be used to monitor the density of the bone tissue at the site of a fracture during the healing process. During the early stages of bone healing, the bone tissue at the fracture site is less dense than the surrounding healthy bone tissue. This is because the bone callus that forms during the healing process is initially made of soft tissue, such as cartilage and collagen fibers, which have lower HU than mature bone tissue^(5,10). To highlight the importance of the HU measurement, a recent study showed that it can be used as a predictor for nonunions in distal tibia fractures⁽¹⁹⁾.


Bone histomorphometry can provide information about bone turnover, mineralization, and remodeling, which are important processes for maintaining bone strength and integrity. By analyzing bone tissue samples, it is possible to observe the degree of mineralization, and the composition of bone tissue. This information can be used to identify changes in bone health and to monitor the effectiveness of treatments for bone disorders such as osteoporosis, thus it is a commonly used method of bone analysis⁽²⁾.

In our study, fracture healing was assessed by comparing the characteristics of the ROI/HU and histological analysis. It was observed that the ROI/HU findings were compatible with the histomorphometric analysis, in which the bones showed an inverse proportional relation between HU,

collagen content, and chondrocytes, while it showed a proportional relation with calcium and intermediate connective tissue. To our knowledge this is the first study to correlate the radiological analysis of HU with histomorphometric findings.

Conclusion

Our study demonstrated that the use of the ROI technique and measurement in HU on digital radiographs was corroborated by histological findings in a fractured bone, and thus safe and reliable method for monitoring bone healing.

Authors' contributions: Correlation between the region of interest in digital radiography, Hounsfield units, and histological maturation on Wistar rats submitted to tibial fracture: EOC P *(<https://orcid.org/0000-0002-9557-8328>) Conceived and planned the activities that led to the study, performed the experiment, collected the data, interpreted the results, reviewed the manuscript draft and approved the final version; LASP *(<https://orcid.org/0000-0002-2756-1794>) Performed the statistical analysis, interpreted the results of the study, performed the bibliographic review, created the first draft of the manuscript, formatted the article, participated in the review process and approved the final version; MAB *(<https://orcid.org/0000-0001-7988-1071>). Performed the bibliographic review, interpreted the results, analyzed the histological images, reviewed the manuscript draft and approved the final version. All authors read and approved the final manuscript.*ORCID (Open Researcher and Contributor ID) 

References

1. Grigoryan M, Lynch JA, Fierlinger AL, Guermazi A, Fan B, MacLean DB, et al. Quantitative and qualitative assessment of closed fracture healing using computed tomography and conventional radiography. *Academic Radiology*. 2003;10(11):1267-73.
2. Chavassieux P, Chapurlat R. Interest of Bone Histomorphometry in Bone Pathophysiology Investigation: Foundation, Present, and Future. *Front Endocrinol (Lausanne)*. 2022;13:907914.
3. Chityala R, Hoffmann KR, Bednarek DR, Rudin S. Region of Interest (ROI) Computed Tomography. *Proc SPIE Int Soc Opt Eng*. 2004;5368(2):534-41.
4. Zeb I, Li D, Nasir K, Katz R, Larjani VN, Budoff MJ. Computed tomography scans in the evaluation of fatty liver disease in a population based study: the multi-ethnic study of atherosclerosis. *Acad Radiol*. 2012;19(7):811-8.
5. Narayanan A, Cai A, Xi Y, Maalouf NM, Rubin C, Chhabra A. CT bone density analysis of low-impact proximal femur fractures using Hounsfield units. *Clin Imaging*. 2019;57:15-20.
6. de la Vega Muns G, Quencer R, Ezuddin NS, Saigal G. Utility of Hounsfield unit and hematocrit values in the diagnosis of acute venous sinus thrombosis in unenhanced brain CTs in the pediatric population. *Pediatr Radiol*. 2019;49(2):234-9.
7. Ouzaid I, Al-qahtani S, Dominique S, Hupertan V, Fernandez P, Hermieu J-F, et al. A 970 Hounsfield units (HU) threshold of kidney stone density on non-contrast computed tomography (NCCT) improves patients' selection for extracorporeal shockwave lithotripsy (ESWL): evidence from a prospective study. *BJU Int*. 2012;110(11 Pt B):E438-42.
8. Schreiber JJ, Anderson PA, Hsu WK. Use of computed tomography for assessing bone mineral density. *Neurosurgical Focus*. 2014;37(1):E4.
9. Chen G, Schmutz B, Epari D, Rathnayaka K, Ibrahim S, Schuetz MA, et al. A new approach for assigning bone material properties from CT images into finite element models. *J Biomech*. 2010;43(5):1011-5.
10. James DR, Webster N, White JD, Marchevsky AM, Cashmore RG, Havlicek M, et al. Comparison of bone healing, as assessed by computed tomography, following tibial tuberosity advancement in dogs with and without autogenous cancellous bone grafts. *N Z Vet J*. 2017;65(5):270-6.
11. Bayne K. Revised Guide for the Care and Use of Laboratory Animals available. American Physiological Society. *Physiol*. 1996;39(4):199,208-11.
12. Howard-Jones N. A CIOMS ethical code for animal experimentation. *WHO Chron*. 1985;39(2):51-6.
13. Schanaider A, Silva PC. Use of animals in experimental surgery. *Acta Cir Bras*. 2004;19(4):441-7.
14. Percie du Sert N, Hurst V, Ahluwalia A, Alam S, Avey MT, Baker M, et al. The ARRIVE guidelines 2.0: Updated guidelines for reporting animal research. *PLoS Biol*. 2020;18(7):e3000410.
15. Padula EOC, Andrade ML, Giordano V, Ramalho MV. Aspectos morfológicos do processo de consolidação de fratura em ratos diabéticos. *Rev Bras Ortop*. 2003;38(3).
16. An Y, Friedman RJ, Parent T, Draughn RA. Production of a standard closed fracture in the rat tibia. *J Orthop Trauma*. 1994;8(2):111-5.
17. Ekegren CL, Edwards ER, de Steiger R, Gabbe BJ. Incidence, Costs and Predictors of Non-Union, Delayed Union and Mal-Union Following Long Bone Fracture. *Int J Environ Res Public Health*. 2018;15(12).
18. Umiatin U, Hadisoebroto Dilogo I, Sari P, Kusuma Wijaya S. Histological Analysis of Bone Callus in Delayed Union Model Fracture Healing Stimulated with Pulsed Electromagnetic Fields (PEMF). *Scientifica (Cairo)*. 2021;2021:4791172.
19. Stowers JM, Black AT, Kavanagh AM, Mata KDL, Bohm A, Katchis SD, et al. Predicting Nonunions in Ankle Fractures Using Quantitative Tibial Hounsfield Samples From Preoperative Computed Tomography: A Multicenter Matched Case Control Study. *J Foot Ankle Surg*. 2022;61(3):562-6.