

Checkrein deformity treated through a forefoot approach: a case report

Deformidade em flexão do hálux tratada por uma abordagem no antepé: relato de caso

1. Faculdade de Medicina do ABC, Santo André, SP, Brazil.
2. Hospital do Servidor Público Municipal de São Paulo, São Paulo, SP, Brazil.

ABSTRACT

Checkrein deformity is characterized by flexible plantar flexion contracture of the interphalangeal joint and flexible extension contracture of the metatarsophalangeal joint of the hallux. It occurs due to entrapment of the flexor hallucis longus in the callus formation at the fracture site or within scar tissue on lower limb. Currently, there is still no consensus about the best surgical treatment for this deformity. The aim of this study is to report a case of a patient that was treated with a novel approach for the treatment of checkrein deformity of the hallux located in the forefoot, with satisfactory functional outcomes.

Level of Evidence V; Therapeutics Studies; Expert Opinion.

Keywords: Joint deformities, acquired/surgery; Foot deformities; Metatarsophalangeal joint; Tendon injuries.

RESUMO

A deformidade em flexão do hálux é caracterizada pela contractura em flexão da articulação interfalangeana e em extensão da articulação metatarsofalangeana do hálux. Ocorre devido ao encarceramento do flexor longo do hálux na formação do calo no local da fratura ou no tecido cicatricial do membro inferior. Ainda não há consenso sobre o melhor tratamento cirúrgico para essa deformidade. O objetivo deste estudo é relatar um caso de um paciente que foi tratado com uma nova abordagem para o tratamento da deformidade em flexão do hálux localizado no antepé, com resultados funcionais satisfatórios.

Nível de Evidência V; Estudos Terapêuticos; Opinião do especialista.

Palavras-chave: Deformidades articulares adquiridas/cirurgia; Deformidades nos pés; Articulação metatarsofalângica; Traumatismos dos tendões.

How to cite this article: Miranda BR, Barroco RS, Nishikawa DRC, Oliveira LZP, Ghani MBA. Checkrein deformity treated through a forefoot approach: a case report. *Sci J Foot Ankle*. 2019;13(4):259-63.

INTRODUCTION

Checkrein deformity is an uncommon condition that it is clinically characterized by dynamic plantar flexion contracture of the interphalangeal joint (IPJ) and dynamic ex-

tension contracture of the metatarsophalangeal joint (MPJ) of the hallux⁽¹⁾. Plantarflexion of the foot usually corrects the contractures and dorsiflexion worsens the deformity. Different fractures are responsible for this type of defor-

Study performed at the Faculdade de Medicina do ABC, Santo André, SP, Brazil.

Correspondence: Bruno Rodrigues de Miranda. Rua: Castro Alves, 60, 4º Andar, São Paulo, SP, Brazil. CEP: 01532-000
E-mail: bruno_rm@hotmail.com

Conflicts of interest: none. **Source of funding:** none.

Date received: November 14, 2019. **Date accepted:** December 17, 2019. **Online:** December 23, 2019.



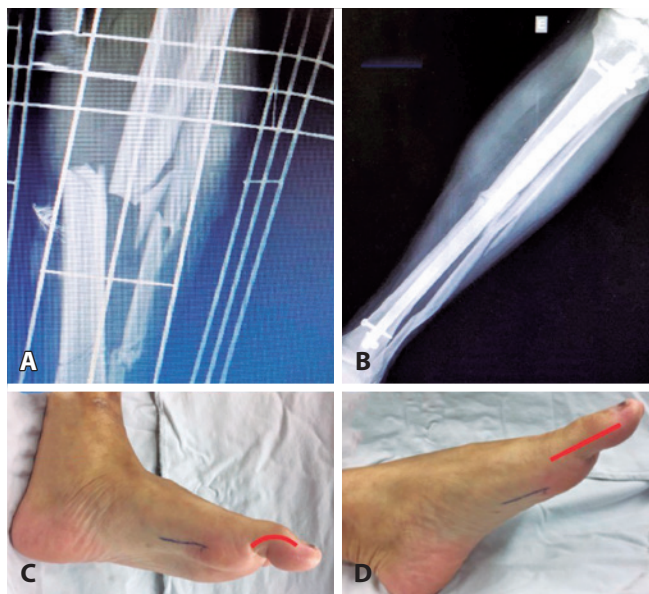
mity such as distal tibia, ankle, talus and calcaneal fractures⁽¹⁻⁷⁾. Checkrein deformity occurs due the entrapment or tethering of the flexor hallucis longus (FHL) in the callus formation at the fracture site or within scar tissue, proximal or distal to the flexor retinaculum⁽¹⁾. Although several surgical approaches have been described, there is no consensus which is the best option^(1,8). Most of the procedures are based on adhesion releases and FHL lengthening with approaches at the fracture site, retromaleolar site or midfoot^(1,9).

The purpose of this study is to report a case of a patient with checkrein deformity due to an open diaphyseal fracture of the tibia and fibula that was treated with the z-lengthening of the FHL through a novel approach located in the forefoot.

CASE REPORT

This study was approved by the Research Ethics Committee with registration in the Brazil Platform under CAAE number: 79521517.0.0000.0082.

We present a case of a 38-years-old male patient with checkrein deformity in the right hallux. Two years ago, he was involved in a car accident which resulted in an open diaphyseal fracture of the tibia and fibula Gustillo and Anderson type 3A (Figure 1A andB). He was treated with closed reduction and intramedullary nail fixation by another orthopaedic team in a different hospital. After that,



Figures 1. (A) Open diaphyseal tibia and fibula fractures treated with (B) intramedullary nail fixation. (C and D) Clinical aspects of the deformity at dorsiflexion and plantarflexion of the foot, and the forefoot approach site.

he has evolved with a flexible deformity of the hallux. He presented to the foot and ankle clinic of our hospital complaining about pain and discomfort on the hallux while wearing closed shoes since then. On physical examination, a dynamic plantar flexion contracture of the IPJ and dynamic extension contracture of the metatarsophalangeal joint MPJ of the hallux was observed (Figure 1C and D). Neurovascular condition had normal findings.

The procedure was performed under regional anesthesia with the patient positioned in a supine position. Prophylactic antibiotic was administered. The preference of the authors was not to use a thigh tourniquet. A longitudinal medial approach of 2-3cm parallel to the ground was performed between the dorsal and plantar skin of the hallux, running posteriorly from the proximal edge of the medial sesamoid bone (Figure 1C and D). The subcutaneous tissue was dissected, and the abductor hallucis tendon exposed. Care was taken to avoid damage of the sensitive plantar-medial nerve of the hallux. We pulled the abductor tendon up and visualize the FHL immediately proximal do the sesamoid sulcus (Figure 2). With the FHL

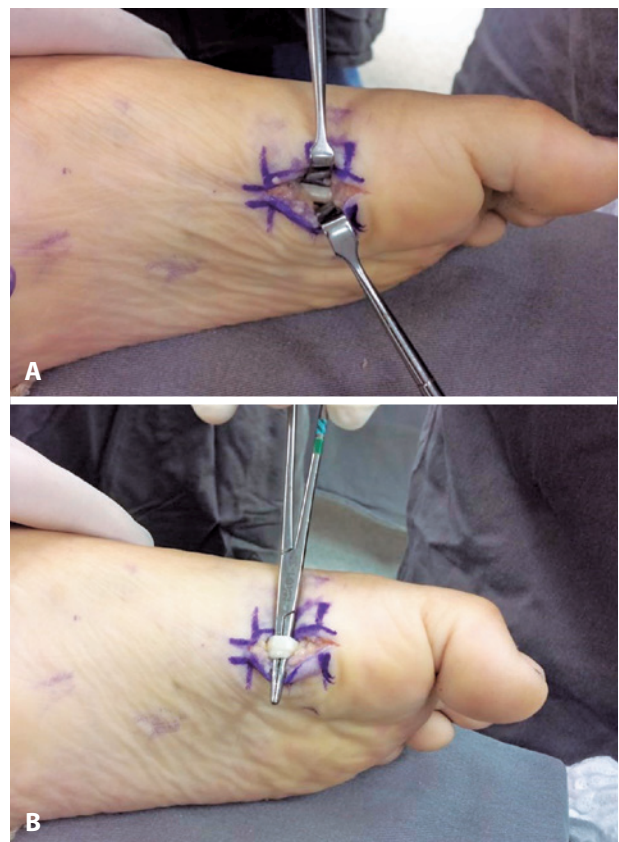

Figure 2. Forefoot medial approach with (A) dissection and (B) exposure of the FHL tendon.

at sight, we placed the ankle and hallux at maximum dorsiflexion for a Z-tenotomy with 2cm in length (Figure 3). To avoid distal stump from retracting we sutured it with a No.2 Vicryl. Then, we kept passively dorsiflexing both to restore physiological range of motion of the IPJ and MPJ. The distal and proximal stumps of the FHL were sutured with a No.2 Nylon using the modified Kessler technique (Figure 4). The incision was closed in layers, using a No.3 Monocryl for subcutaneous tissue and a No.4 Nylon for the skin. A sterile soft dressing was applied to the surgical wound, and a custom-made thermoplastic splint (CTS) was placed on the dorsal site of the hallux crossing both IPJ and MPJ to keep the toe straight (Figure 5). Postoperatively, patient remained non-weight bearing with the CTS

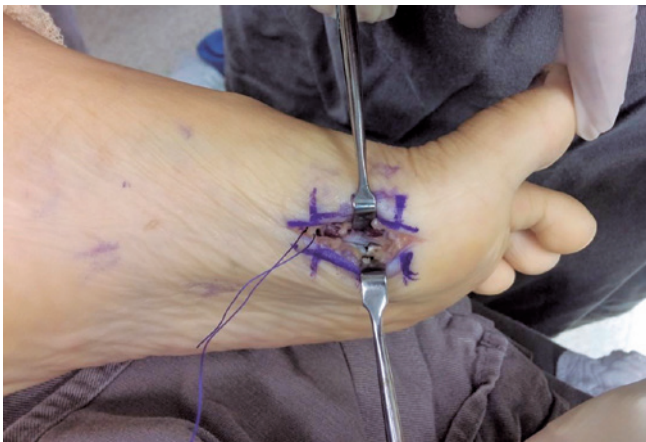

Figure 3. With the ankle and hallux at maximum dorsiflexion, a Z-tenotomy with 2cm in length is performed. The proximal stump of the FHL is sutured to prevent its retraction.

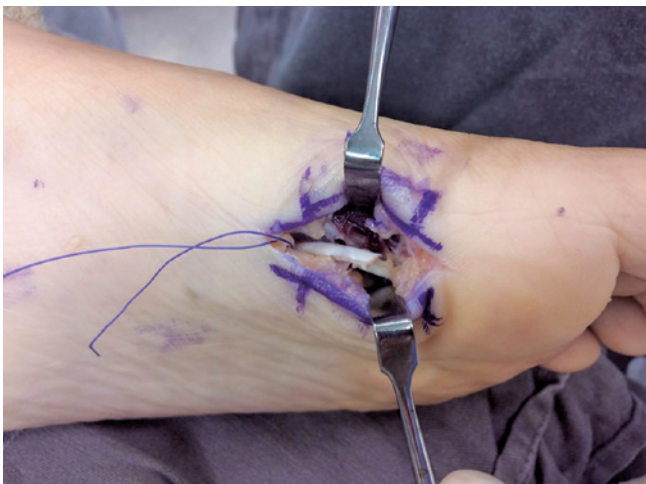

Figure 4. The distal and proximal stumps of the FHL are sutured with a No.2 Nylon using the modified Kessler technique.

for 6 weeks. After 2 weeks of surgery, no wound complications were observed, suture stitches were removed and active plantarflexion exercises were oriented but without taking the CTS out. The use of the CTS kept the toe straight and avoided extension movements of the hallux preventing excessive tension to the suture. The early mobilization granted by the CTS reduced the chance of scar adhesions and the fact that it gave condition for early FHL activation a reasonable functional outcome was observed. Patient was instructed to always maintain the CTS except for hygiene purposes. At 6 weeks, CTS was removed, and progressive weight bearing was allowed. At that time, physical therapy program started to progressively restore proprioception and strengthening. On the latest follow-up visit at 24 months of the surgery, we haven't noticed partial or total recurrence of the deformity, loss of range of motion and weakness of plantarflexion of the hallux (Figure 6). Patient was asymptomatic and fully active.

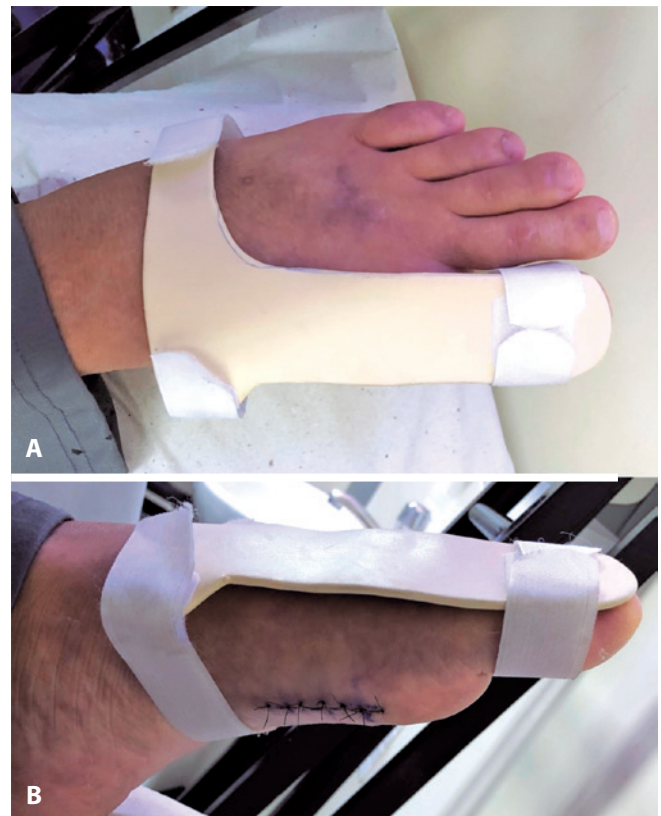

Figure 5. (A) dorsal and (B) lateral view of the custom-made thermoplastic splint. It is placed on the dorsal site of the hallux crossing both IPJ and MPJ to keep the toe straight and it also protects the suture, avoiding extension of the hallux.

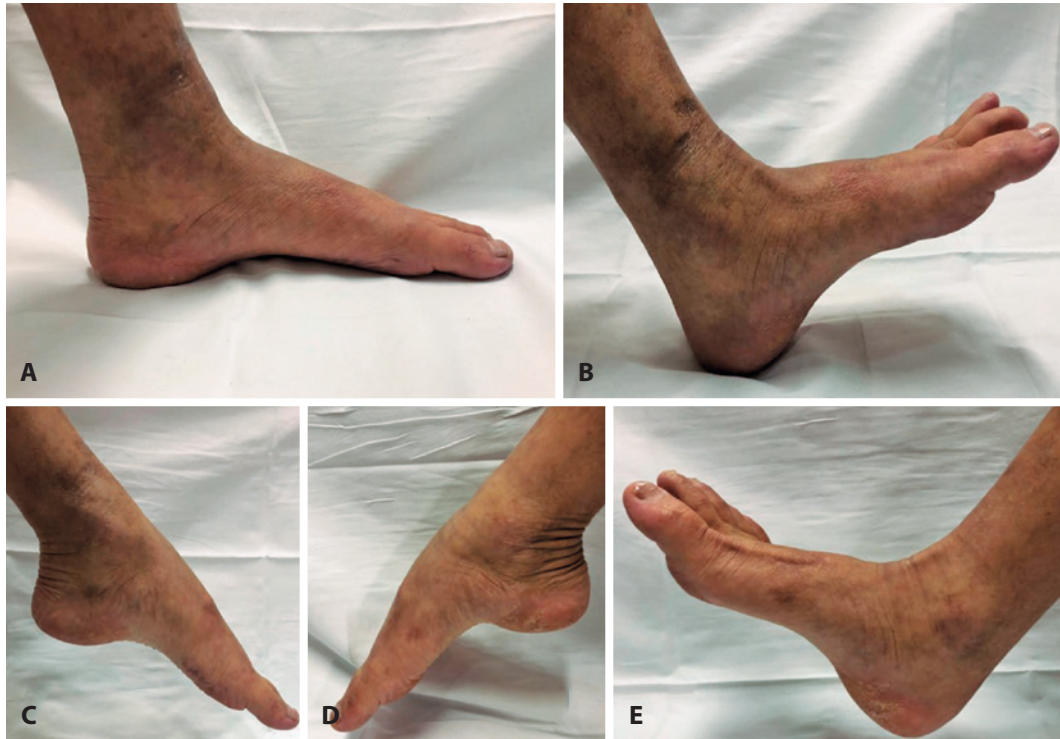

Figure 6. Clinical exam at 24 months of postoperative demonstrates a (A) straight position of the hallux while standing and no signs of recurrence in (B) dorsiflexion and (C) plantarflexion compared to the contralateral foot (D and E).

DISCUSSION

Checkrein deformity is a rare condition with different surgical interventions described in the literature. Release of the adhesions at the fracture site, Z-plasty lengthening of the FHL tendon at the fracture site associated to adhesions releases, Z-plasty lengthening of the FHL tendon at the midfoot with release of the adhesions were reported but with variable clinical results^(8,9). To date, there is still no consensus about the etiology and the surgical treatment of this deformity and most of the studies are based in small case series. In this report, we presented a case that was successfully treated through a new approach with a distal incision located in the forefoot. To our knowledge this is the first study to describe an approach located in the forefoot to manage checkrein deformity.

In 1974, Clawson was the first to describe the claw deformity of the hallux as consequence of FHL entrapment after fracture of distal third of the tibia⁽¹⁰⁾. Since then, studies have shown that deformity can arise from ankle, calcaneal and talar fractures as well⁽¹⁻⁷⁾. Most of the authors have suggested that lengthening of the FHL tendon at the midfoot, under the navicular tuberosity, is a better approach than at the posterior site of the ankle^(4,9). The reason is the

absence of scar tissue compared to the site above the ankle. Therefore, less chance of recurrence of adhesions. Besides, releases at the fracture site requires longer incisions with extensive soft tissue dissection around neurovascular structures⁽⁷⁾. Lee et al.⁽⁹⁾ (2008) reported the largest series of patients who underwent surgical repair. Of the 11 patients, 5 have been submitted to release of the adhesions with Z-lengthening at the musculotendinous junction above the ankle at the fracture site, and 6 have been submitted to Z-lengthening at the midfoot. Of the 5 patients with lengthening above the ankle, 2 developed partial recurrence and 1 total recurrence of the deformity. In the patients with midfoot procedure, none has developed recurrence. However, lengthening of the FHL in the midfoot at the knot of Henry presents some disadvantages. There is a risk of damaging the main attachments of the FHL to the flexor digitorum longus and flexor digitorum accessorius in the Knot of Henry leading to a functional loss in lesser toes motion. This approach is also prone to neurovascular injuries since there is a close relation of the knot of Henry to the plantar neurovascular branches. In our forefoot approach the lengthening was performed distally to the knot of Henry. Different from the midfoot approach,

deep and meticulous disconnection of FDL and FHL were not needed preventing damage to the neurovascular branches nearby and loss of function of the lesser toes. Also, the fact that dissection was more superficial the chance of wound complications was lower.

The highlight of our study is to present a case with an uncommon condition that usually have a reserved prognosis in relation to deformity correction and recurrence when managed with the treatments that have been described so far but was successfully treated with our novel approach.

Besides, it showed to be technically simple and safe regarding soft tissues integrity.

CONCLUSION

In conclusion, based in this case report we found that the forefoot approach is a safe and effective alternative to correct checkrein deformity with Z-lengthening of the FHL with less chance of soft tissue complications. With a more distal incision it is possible to prevent injuries to the knot of Henry and adjacent neurovascular structures.

Authors' contributions: Each author contributed individually and significantly to the development of this article: BRM *(<https://orcid.org/0000-0002-5306-2972>) conceived and planned the activities that led to the study, wrote the article, participated in the review process, approved the final version; RSB *(<https://orcid.org/0000-0002-2870-2261>) conceived and planned the activities that led to the study, wrote the article, participated in the review process, approved the final version; DRCN *(<https://orcid.org/0000-0003-0227-2440>) wrote the article, participated in the review process, approved the final version; LZPO *(<https://orcid.org/0000-0001-5849-5841>) participated in the review process, approved the final version; MBAG *(<https://orcid.org/0000-0003-0007-5574>) participated in the review process, approved the final version. *ORCID (Open Researcher and Contributor ID).

REFERENCES

1. Lee JH, Kim YJ, Baek JH, Kim DH. Z-plasty of the flexor hallucis longus tendon at tarsal tunnel for checkrein deformity. *J Orthop Surg (Hong Kong)*. 2016;24(3):354-7.
2. Kim SH, Lee KT, Smith RW, Park Y-U. Checkrein deformity secondary to entrapment of FHL after talus fracture: a case report. *Foot Ankle Int*. 2010;31(4):336-8.
3. Rosenberg GA, Sferra JJ. Checkrein deformity - An unusual complication associated with a closed Salter-Harris type II ankle fracture: A case report. *Foot Ankle Int*. 1999;20(9):591-4.
4. Veiga Sanhudo JA, Lompa PA. Checkrein deformity - Flexor hallucis tethering: Two case reports. *Foot Ankle Int*. 2002;23(9):799-800.
5. Carr JB. Complications of calcaneus fractures entrapment of the flexor hallucis longus: Report of two cases. *J Orthop Trauma*. 1990;4(2):166-8.
6. Leitschuh PH, Zimmerman JP, Uhorchak JM, Arciero RA, Bowser L. Hallux Flexion Deformity Secondary to Entrapment of the Flexor Hallucis Longus Tendon after Fibular Fracture. *Foot Ankle Int*. 1995;16(4):232-5.
7. Yuen CP, Lui TH. Adhesion of flexor hallucis longus at the site of a tibial-shaft fracture--a cause of a checkrein deformity. *Foot Ankle Surg*. 2015;21(1):e23-6.
8. Holcomb TM, Temple EW, Barp EA, Smith HL. Surgical correction of checkrein deformity after malunited distal tibia fracture: a case report. *J Foot Ankle Surg*. 2014;53(5):631-4.
9. Lee HS, Kim JS, Park S-S, Lee D-H, Park JM, Wapner KL. Treatment of checkrein deformity of the hallux. *J Bone Joint Surg Br*. 2008; 90(8):1055-8.
10. Clawson DK. Claw Toes Following Tibial Fracture. *Clin Orthop Relat Res*. 1974;(103):47-8.