

Short gastrocnemius: epidemiology and associated signs and symptoms

Gastrocnêmio curto: epidemiologia e associação de sinais e sintomas

Samuel Machado^{1,2}, Marcelo Rassweiler Hardt^{1,2}, André Bergamaschi Demore², Antônio Kim²,
Leandro Marcantonio Camargo^{1,2}, Carolina Claudino Barbosa^{1,2}

1. Hospital Municipal São José de Joinville, Joinville, SC, Brazil.

2. Instituto de Ortopedia e Traumatologia de Santa Catarina, Joinville, SC, Brazil.

ABSTRACT

Objective: To determine the prevalence of short gastrocnemius in orthopaedic patients treated in the emergency room and the foot and ankle outpatient clinic of a public hospital and to evaluate the relationship between prevalence and certain specific symptoms.

Methods: This was an observational cross-sectional study conducted using a questionnaire completed by patients treated in February 2018.

Results: Of the 160 patients studied, 21 (13.1%) had a diagnosis of shortening of the gastrocnemius. The condition was more prevalent in females than in males, with no differences in race, age, laterality or occupation. The most commonly associated symptoms were calf pain, back pain, equinism and metatarsalgia, which were all present in more than 2/3 of cases.

Conclusion: Shortening of the gastrocnemius is a fairly common pathology that deserves greater attention in orthopaedic practice. Additional studies are needed to better correlate epidemiological findings with this pathology.

Level of Evidence IV; Prognostic Studies; Case Series.

Keywords: Muscle, skeletal; Muscle contraction; Epidemiology.

RESUMO

Objetivo: Avaliar a prevalência de gastrocnêmio curto em pacientes ortopédicos atendidos no pronto socorro e ambulatório de pé e tornozelo de um hospital público, e a sua relação com alguns sintomas específicos.

Métodos: Estudo observacional do tipo transversal, realizado através da avaliação, mensuração e aplicação de questionário específico, em pacientes atendidos de 1 a 28 de fevereiro de 2018.

Resultados: Dos 160 pacientes coletados, 21 (13,1%) apresentaram o diagnóstico de encurtamento do gastrocnêmio. O sexo feminino foi o mais prevalente, sem predileção por raça, faixa etária, lateralidade ou profissão. Os sintomas mais comumente associados foram dor na panturrilha, dor lombar, equinismo e metatarsalgia, todos presentes em mais de 2/3 dos casos.

Conclusão: O encurtamento do gastrocnêmio é uma patologia não tão rara, que merece uma maior atenção nos consultórios ortopédicos. Mais estudos são necessários para uma melhor correlação dos achados epidemiológicos com a patologia estudada.

Nível de Evidência IV; Estudos Prognósticos; Série de Casos.

Descritores: Músculo gastrocnêmio; Contração muscular; Epidemiologia.

How to cite this article: Machado S, Hardt MR, Demore AB, Kim A, Camargo LM, Barbosa CC. Short gastrocnemius: epidemiology and associated signs and symptoms. *Sci J Foot Ankle*. 2018;12(2):106-11.

Work performed at the Hospital Municipal São José de Joinville, Joinville, SC, Brazil.

Correspondence: Samuel Machado. Rua Blumenau, 1316, América. CEP: 89.204-322 – Joinville, SC, Brazil. E-mail: cirurgiadope@iot.com.br

Conflicts of interest: none. **Source of funding:** none.

Date received: March 12, 2018. **Date Accepted:** May 8, 2018. **Online:** June 20, 2018.



INTRODUCTION

Despite studies of muscle contracture among patients with neurological disorders, little attention has been given to the cumulative pathological effects or shortened gastrocnemius, and the existence of a subtler equinus contracture of the gastrocnemius, which can be found in the “normal” population, has been largely ignored^(1,2). This is surprising given that isolated shortening of the gastrocnemius and its treatment with surgical recession were first described in the early 1900s by Silverskiöld, Vulpius and Stoffel⁽¹⁾.

Checking for gastrocnemius retraction should be an essential part of foot and ankle examinations for all orthopaedic practitioners as opposed to only surgeons. However, few routinely screen for this disorder^(3,4). The clinical test used to evaluate isolated gastrocnemius contracture was first described by Silverskiöld^(5,6).

Short gastrocnemius may occur due to human evolution. Walking with the knee extended, sitting for long periods of time and the frequent use of high heels may contribute to this disorder⁽³⁾.

Walking requires complex and coordinated interactions between the main body joints, particularly the lower extremities. Ankle movement disorders resulting from gastrocnemius muscle contracture during walking can affect not only the ankle-foot complex but also all lower extremity joints^(7,8).

While isolated gastrocnemius contracture is more prevalent in patients with forefoot and midfoot pain than in the general population⁽⁶⁾, we are unaware of any publication addressing its prevalence or long-term effects among normal, healthy individuals⁽¹⁾.

Musculotendinous contracture of the posterior region of the leg limits the ankle’s range of motion and causes an equinus foot posture where increased contact pressure is generated in the plantar region of the forefoot. These altered mechanics generate symptoms and pathologies such as plantar fasciitis, midfoot arthritis, posterior tibial tendon dysfunction, forefoot overload, Achilles tendinopathy, metatarsalgias, stress fractures, diabetic ulcers and Charcot arthropathy. Effective treatment of these conditions includes addressing the underlying gastrocnemius contracture and the foot and ankle pathology^(1-3,5,7-10).

Gastrocnemius resection and elongation has become an important auxiliary procedure in many reconstructive surgeries including “hallux valgus”, planovalgus foot and

total ankle arthroplasty. Moreover, isolated gastrocnemius resection is also performed when treating plantar fasciitis, Achilles tendinosis, metatarsalgia and diabetic forefoot ulceration⁽¹¹⁾. Currently, the most commonly used methods are the Strayer, Hoke, Barouk and Baumann techniques⁽¹⁰⁻¹³⁾. However, a number of potential risks, such as nerve damage, muscle weakness and excessive recession, are associated with these techniques^(2,10). Recent studies have further described these surgical options for gastrocnemius resection and evaluated their long-term effects^(2,13).

Given the lack of literature addressing the prevalence and risk factors for short gastrocnemius, our goal was to evaluate the epidemiological and clinical data of orthopaedic patients treated in the emergency room and foot and ankle outpatient clinic of a public hospital in a city in southern Brazil in order to determine the prevalence and risk factors for short gastrocnemius.

METHODS

This study was approved by the Ethics Committee with registration in the Brazil Platform under CAAE number: 82687317.1.0000.5362.

This was a cross-sectional study using a questionnaire completed by patients treated in the emergency room and foot and ankle outpatient clinic in February 2018 in a public hospital in southern Brazil. The study adhered to ethical guidelines for conducting human subjects research.

Variables of interest included gender, age, occupation, race, laterality, smoking status, comorbidities, symptoms and associated pathologies, angles obtained from the final position of the ankle based on length of the posterior leg muscles, the Silverskiöld test, the Taloché test and treatment performed for the patient’s condition.

The study included patients treated in the emergency room and in the foot and ankle outpatient clinic during the study period. Exclusion criteria included patients with incomplete data, those with previous surgery in the foot and ankle region, the presence of muscular disorders of other aetiologies or previous rupture of the sural triceps muscle complex.

The data collected during this study were stored in an Excel database, and statistical analyses were performed using SPSS (IBM Statistic 20.0). Descriptive statistics were calculated (frequency of variables and central tendency

and dispersion measurements). Correlations between variables were evaluated using Pearson's correlation coefficient, and comparisons were performed using the Mann-Whitney test.

RESULTS

Data were collected from 160 eligible patients during the study period. Of these, 21 had a confirmed diagnosis of shortening of the gastrocnemius, yielding prevalence of 13.1% in the study population. The diagnosis was confirmed by the presence of a positive Silverskiold test, with a maximum difference of 13° between ankle dorsiflexion angles, measured with knee extension and flexion as described by Barouk⁽⁵⁾.

Analysis of the epidemiological variables of the 21 affected patients revealed that 80.95% (17/21) were women (17/21), and the mean age was 45.07. All affected patients were of white race. The prevalence of short gastrocnemius was greater among individuals over age 40 (Table 1), with the following prevalence in each age group: 4.76% among those <20 years of age, 28.57% among those 20–40 years of age, 42.85% among those 40–60 years of age and 23.80% among those >60 years of age.

Regarding smoking and the presence of associated comorbidities, only 2 of the 21 patients were smokers (9.52%), while high blood pressure (hypertension) and obesity were the most commonly found comorbidities, with each present in 9 subjects (42.85%). There were also 5 patients with diabetes mellitus (DM) and 5 with no associated comorbidity (23.80%). Gout, dermatitis and venous insufficiency were each observed in 1 patient (Figure 1). Neither smoking nor associated comorbidities demonstra-

ted a statistically significant relationship with the presence of short gastrocnemius.

There was also no statistical relationship between occupation or laterality and the presence of short gastrocnemius. Eleven of the 21 patients had bilateral short gastrocnemius, while 5 were affected on the right and five were affected on the left (Table 1).

With regard to associated symptoms, 76.19% of patients had calf pain; 71.42% had equinus, metatarsalgia and lower back pain; 57.14% had cramps; 52.38% had plantar fasciitis and 42.85% had ankle instability. Calf pain, equinus, metatarsalgia and low back pain were statistically significantly associated with short gastrocnemius (Table 2).

The mean values for ankle dorsiflexion with the knee extended and flexed were 85.0° and 93.7°, respectively, among patients with a confirmed diagnosis of short gastrocnemius. The Taloché test and maintaining balance with only the heels on the ground identified 71.42% and 76.19% of cases, respectively (Table 3).

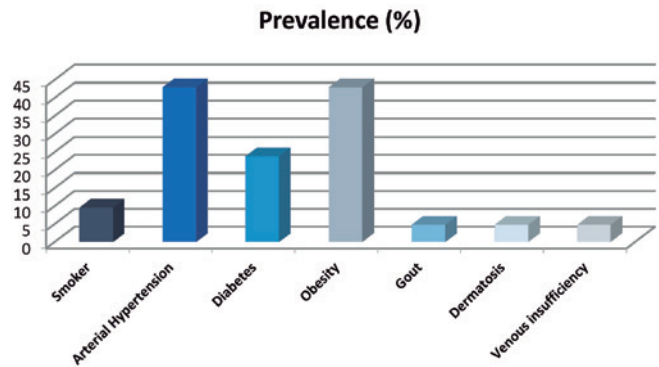


Figure 1. Lifestyle factors and comorbidities. **Source:** Prepared by the author based on the results of the study.

Table 1. Epidemiological data

		Frequency	%
Gender	Female	17	80.95
	Male	4	19.05
Race	White	21	100.0
Age	<20 years	1	4.76
	20-40 years	6	28.57
	40-60 years	9	42.85
	>60 years	5	23.80
Laterality	Right	5	23.80
	Left	5	23.80
	Bilateral	11	52.38

Source: Prepared by the author based on the results of the study.

Table 2. Associated symptomology

	Prevalence	%	P value
Calf pain	16	76.19	<0.001
Equinism	15	71.42	<0.001
Metatarsalgia	15	71.42	<0.001
Lower back pain	15	71.42	<0.001
Cramp	12	57.14	0.163
Plantar fasciitis	11	52.38	0.173
Ankle instability	9	42.85	0.622

Source: Prepared by the author based on the results of the study.

Table 3. Measurements and tests

	Measurements	
	Extension	Flexion
Mean	85.0°	93.7°
	Tests	
	Taloche	Heel
Positive	71.42%	76.19%

Source: Prepared by the author based on the results of the study.

Of the 21 affected patients, none received treatment for shortening of the sural triceps musculature, but 17 (80.95%) underwent treatment for related symptoms. The main treatments were drugs, including analgesics (ANG), and nonsteroidal anti-inflammatory drugs (NSAIDs), physical therapy (FST) and the use of insoles.

DISCUSSION

Shortening of the gastrocnemius muscle, whether congenital or acquired, is the most common cause of lack of movement arc in the ankle, predominantly dorsiflexion^(1,14). Few authors, however, have discussed the role of the posterior superficial compartment of the leg in this area or addressed the presence or role of an isolated gastrocnemius contracture^(1,15-20). The epidemiology of short gastrocnemius has not been published in the national literature.

Screening for gastrocnemius muscle retraction should be an essential part of the clinician's or surgeon's physical examination of the foot and ankle. There is a high prevalence of short gastrocnemius in the healthy population, but it is significantly higher in populations with a foot or ankle impairment. The Silverskiold test is essential for diagnosis⁽²¹⁾. This impairment was often called Achilles tendon contracture, which is a misnomer, as the greatest elongation is not of the tendon but of the muscle belly, which corresponds to approximately 95–97% of that function⁽¹⁾.

Of the 160 patients in this study, the prevalence of shortening of the gastrocnemius was 13.1%, with more women than men being affected. To our knowledge, this finding has not been previously reported. Prevalence reported by previous authors has not been in a general population. For example, Cychoz et al. found that 176/209 (96.5%) of patients with complaints inherent to the anatomical foot region had restricted ankle dorsiflexion, which required compensation during walking⁽²⁾. They also noted that ankle

equinus contracture was found in over 10% of all patients with a diagnosis of diabetes⁽²⁾. The latter finding was not reported to be statistically significant, which corroborates our findings in relation to comorbidities associated with short gastrocnemius.

Regarding the prevalence of complaints such as calf pain, lower back pain, metatarsalgia, plantar fasciitis, ankle instability and cramp, the first three have been previously described as the most prevalent complaints without any further analysis^(3,5,22-24). Such reports are consistent with what we observed in our population; more than 70% of patients reported these complaints, along with equinism. However, we believe that our sample of 21 patients with a confirmed diagnosis of shortening of the gastrocnemius is a small sample with which to establish a reliable relationship between pathology and symptomology.

It is worth noting that although contracture in equinus is well recognised as impaired dorsiflexion of the tibiotalar joint, there remains no reliable study that establishes its prevalence, natural history, treatment or even clinical diagnostic criteria in humans⁽²⁵⁾.

Some journals have discussed the association between shortening of the gastrocnemius and hallux valgus. Barouk presented a series of 107 patients with short gastrocnemius in 182 lower limbs. Of these, it was observed that 128 had associated hallux valgus (77%). Most hallux valgus deformities were of the congenital type (71% congenital, 29% acquired)⁽⁴⁾. Many foot deformities, such as hallux valgus, plantar ulceration, stress fracture, subluxation and metatarsalgia, seem to have a multifactorial origin in people without neurological pathologies⁽¹⁴⁾. To date, no grounded concept has been established to explain the association of hallux valgus with short gastrocnemius. In view of this, we suggest a need for more research on the effect of gastrocnemius contraction on the development of the deformity with first ray valgus.

We also found no association between short gastrocnemius and either age or laterality. There is an absence of such information in the literature, and as for the associated symptoms described above, a larger group of affected individuals is required to more definitively establish these relationships.

Based on these findings and the numerous disorders and symptoms associated with short gastrocnemius, we believe it would be helpful for clinical diagnosis if all orthopaedic specialists performed more frequent and

thorough examinations for this disorder. We therefore draw attention to the need for future larger studies to verify whether correlation exists between these variables. This could lead to earlier diagnoses and appropriate administration of treatment, which would facilitate clinical improvement and consequently improve patients' quality of life.

CONCLUSIONS

We conclude that a prevalence of gastrocnemius muscle shortening of 13.1% is quite substantial, and we must stress the importance of a thorough clinical examination, both by orthopaedic foot and ankle specialists and general orthopaedic practitioners, in the search for earlier and more accurate diagnosis and better treatment.

Authors' Contributions: Each author contributed individually and significantly to the development of this article: SM *(<https://orcid.org/0000-0002-1536-0266>) wrote the article, interpreted the results, conceived and planned the activities that led to the study, participated in the review process and approved the final version; MRH *(<https://orcid.org/0000-0001-6740-5617>) wrote the article, interpreted the results, conceived and planned the activities that led to the study, participated in the review process and approved the final version; ABD *(<https://orcid.org/0000-0002-6946-0027>) conceived and planned the activities that led to the study, participated in the review process and approved the final version; AK *(<https://orcid.org/0000-0002-6662-2721>) conceived and planned the activities that led to the study, participated in the review process and approved the final version; LMC *(<https://orcid.org/0000-0001-8317-904x>) conceived and planned the activities that led to the study, participated in the review process and approved the final version; CCB *(<https://orcid.org/0000-0003-2024-6860>) conceived and planned the activities that led to the study, participated in the review process and approved the final version. *ORCID (Open Researcher and Contributor ID).

REFERENCES

- DiGiovanni CW, Kuo R, Tejwani N, Price R, Hansen ST Jr, Cziernecki J, Sangeorzan BJ. Isolated gastrocnemius tightness. *J Bone Joint Surg Am.* 2002;84(6):962-70.
- Cychoz CC, Phisitkul P, Belatti DA, Glazebrook MA, DiGiovanni CW. Gastrocnemius recession for foot and ankle conditions in adults: Evidence-based recommendations. *Foot Ankle Surg.* 2015;21(2):77-85.
- Bowers AL, Castro MD. The mechanics behind the image: foot and ankle pathology associated with gastrocnemius contracture. *Semin Musculoskelet Radiol.* 2007;11(1):83-90.
- Barouk LS. The effect of gastrocnemius tightness on the pathogenesis of juvenile hallux valgus: a preliminary study. *Foot Ankle Clin.* 2014;19(4):807-22.
- Barouk P, Barouk LS. Clinical diagnosis of gastrocnemius tightness. *Foot Ankle Clin.* 2014;19(4):659-67.
- Cazeau C, Stiglitz Y. Effects of gastrocnemius tightness on forefoot during gait. *Foot Ankle Clin.* 2014;19(4):649-57.
- Selby-Silverstein L, Farrett WD Jr, Maurer BT, Hillstrom HJ. Gait analysis and bivalved serial casting of an athlete with shortened gastrocnemius muscles: a single case design. *J Orthop Sports Phys Ther.* 1997;25(4):282-8.
- You JY, Lee HM, Luo HJ, Leu CC, Cheng PG, Wu SK. Gastrocnemius tightness on joint angle and work of lower extremity during gait. *Clin Biomech (Bristol, Avon).* 2009;24(9):744-50.
- Baumbach SF, Braunstein M, Regauer M, Böcker W, Polzer H. Diagnosis of Musculus Gastrocnemius Tightness - Key Factors for the Clinical Examination. *J Vis Exp.* 2016;7(113).
- Rong K, Ge WT, Li XC, Xu XY. Mid-term Results of Intramuscular Lengthening of Gastrocnemius and/or Soleus to Correct Equinus Deformity in Flatfoot. *Foot Ankle Int.* 2015;36(10):1223-8.
- Rong K, Li XC, Ge WT, Xu Y, Xu XY. Comparison of the efficacy of three isolated gastrocnemius recession procedures in a cadaveric model of gastrocnemius tightness. *Int Orthop.* 2016;40(2):417-23.
- Toomey EP, Seibert NR. The use of ultrasound to isolate the gastrocnemius-soleus junction prior to gastrocnemius recession. *Foot Ankle Clin.* 2014;19(4):739-43.
- Hamilton PD, Brown M, Ferguson N, Adebibe M, Maggs J, Solan M. Surgical anatomy of the proximal release of the gastrocnemius: a cadaveric study. *Foot Ankle Int.* 2009;30(12):1202-6.
- Downey MS. Ankle equinus. In: Banks AS, Downey MS, Martin DE, et al, editors. *McGlamry's comprehensive textbook of foot and ankle surgery.* 2ed. Philadelphia: Lippincott Williams & Wilkins; 2001. v.1 p. 715-60.
- DiGiovanni CW, Langer P. The role of isolated gastrocnemius and combined Achilles contractures in the flatfoot. *Foot Ankle Clin.* 2007;12(2):363-79.
- Root ML, Orien WP, Weed JH. Normal and abnormal function of the foot: clinical biomechanics. Los Angeles: Clinical Biomechanics Corp., 1977. v.2. p 174.
- Harris RI, Beath T. Hypermobil flat-foot with short tendo Achillis. *J Bone Joint Surg Am.* 1948;30(1): 116-38.
- Toolan BC, Sangeorzan BJ, Hansen ST Jr. Complex reconstruction for the treatment of dorsolateral peritalar subluxation of the foot. Early results after distraction arthrodesis of the calcaneocuboid joint in conjunction with stabilization of, and transfer of the flexor digitorum longus tendon to, the midfoot to treat acquired pes planovalgus in adults. *J Bone Joint Surg Am.* 1999;81(1):1545-60.
- Fraser RK, Menelaus MB, Williams PF, Cole WG. The Miller procedure for mobile flat feet. *J Bone Joint Surg Br.* 1995;77(3):396-9.
- Hibbs RA. Muscle bound feet. *New York Med J.* 1914;100:797.
- Barouk P. Introduction to gastrocnemius tightness. *Foot Ankle Clin.* 2014;19(4):xv.
- Baumbach SF, Braunstein M, Seeliger F, Borgmann L, Böcker W, Polzer H. Ankle dorsiflexion: what is normal? Development of a decision pathway for diagnosing impaired ankle dorsiflexion and M. gastrocnemius tightness. *Arch Orthop Trauma Surg.* 2016;136(9):1203-11.

23. Pascual Huerta J. The effect of the gastrocnemius on the plantar fascia. *Foot Ankle Clin.* 2014;19(4):701-18.
24. Barouk P. Recurrent metatarsalgia. *Foot Ankle Clin.* 2014;19(3):407-24.
25. Kawakami Y, Kanehisa H, Fukunaga T. The relationship between passive ankle plantar flexion joint torque and gastrocnemius muscle and achilles tendon stiffness: implications for flexibility. *J Orthop Sports Phys Ther.* 2008;38(5):269-76.