

# Symptomatic os intermetatarsium in a young athlete: case report

## Os intermetatarsium sintomático em uma jovem atleta: relato de caso

Letícia Zaccaria Prates de Oliveira<sup>1</sup>, Rui dos Santos Barroco<sup>1</sup>, Bruno Rodrigues de Miranda<sup>1</sup>, Bianca Cristina Romão da Cunha<sup>1</sup>

1. Faculdade de Medicina do ABC, Santo André, SP, Brazil.

### ABSTRACT

The os intermetatarsium is located between the medial cuneiform and the base of the first and second metatarsals. Literature reviews have found few symptomatic cases of this condition since the 19th century. We report the case of a young female athlete, 20 years old, with sudden pain in the back of the midfoot after a jump. The os intermetatarsium is the rarest accessory bone in the foot and is typically asymptomatic. The presence of this bone should be considered when patients, especially young athletes, present with pain in the dorsum of the foot and compressive symptoms of the deep fibular nerve.

**Level of Evidence V; Therapeutic Studies; Expert Opinion.**

**Descriptors:** Acute pain; Diseases of the foot; Athletic injuries.

### RESUMO

O os intermetatarsium é observado entre o cuneiforme medial e a base do primeiro e segundo metatarsos. Revisões de literatura encontraram escassos casos sintomáticos desta condição desde o século XIX. Relatamos o caso de uma jovem atleta, 20 anos, com dor súbita no dorso do mediopé após salto. O os intermetatarsium é o mais raro dos ossos acessórios do pé, tipicamente assintomático, que deve ser lembrado em quadros dolorosos no dorso do pé e sintomas compressivos do nervo fibular profundo especialmente em atletas jovens.

**Nível de Evidência V; Estudos Terapêuticos; Opinião de Especialista.**

**Descritores:** Dor aguda; Doenças do pé; Traumatismos em atletas.

**How to cite this article:** Oliveira LZP, Barroco RS, Miranda BR, Cunha BCR. Symptomatic os intermetatarsium in a young athlete: case report. Sci J Foot Ankle. 2018;12(3):247-9.

### INTRODUCTION

The presence of accessory ossicles or sesamoid bones is an anatomical variation present in a variable portion of different populations<sup>(1)</sup>. Among the parts of the body, the foot and the ankle are the main sites for sesamoid bones, which are located at different anatomical points and have various clinical meanings<sup>(1,2)</sup>. While the presence of an

accessory navicular bone and os peroneum are relatively frequent findings that have been well studied, other sesamoids, such as the intermetatarsium, are rare and have seldom been reported in published case series<sup>(2)</sup>.

The os intermetatarsium is located between the medial cuneiform and the base of the first and second metatarsals<sup>(1,2)</sup>. It was first described by Gruber<sup>(3)</sup> in 1856, and

Work performed at the Hospital Estadual Mário Covas, Santo André, SP, Brazil.

**Correspondence:** Rui dos Santos Barroco. Rua Afonso Brás, 817 – Vila Nova Conceição. CEP: 04511-011 – São Paulo, SP, Brazil

E-mail: [ruibaroco@uol.com.br](mailto:ruibaroco@uol.com.br)

**Conflicts of interest:** none. **Source of funding:** none.

**Date received:** March 14, 2018. **Date accepted:** August 16, 2018. **Online:** September 30, 2018



few reports in the literature have examined this finding. This accessory ossicle may be fused to or articulated with both the first and second metatarsals and is indicated as a secondary cause of hallux valgus by a mass effect that causes a varus deformity at the base of the first metatarsus<sup>(4,5)</sup>.

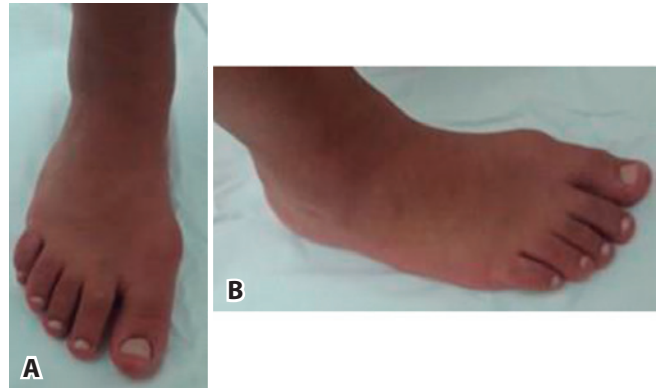Burman and Lapidus<sup>(6)</sup> reviewed 1000 patients and reported an intermetatarsium incidence rate of 3.3%, with only 4 symptomatic cases. A literature review published in 2015 by Rachha et al.<sup>(1)</sup> found only 16 cases of symptomatic intermetatarsium since its description by Gruber<sup>(3)</sup> in the 19th century.

In this study, we report the case of a young female athlete, 20 years old, with pain in the back of the foot after sport activity associated with the presence of os intermetatarsium.

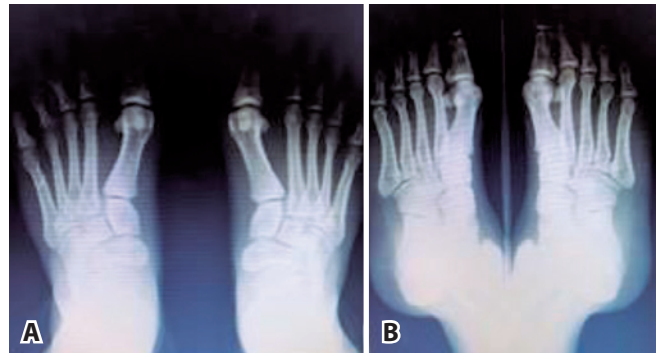
### CASE REPORT

This study was approved by the Research Ethics Committee with registration in the Brazil Platform under CAAE number: 77647417.5.0000.0082.

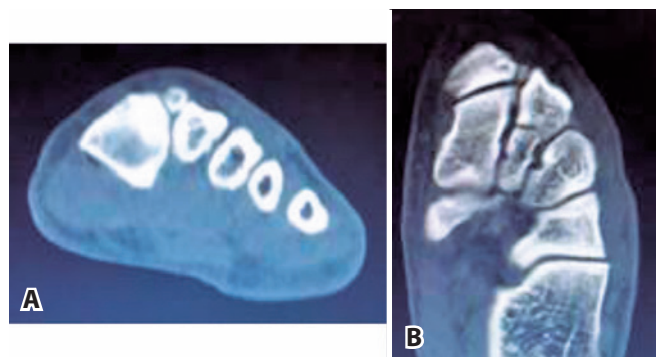
We report the case of a 20-year-old female patient, who was an amateur handball athlete, with a 6-week history of sudden pain associated with edema in the back of the right midfoot after a jump followed by a fall to the ground during a handball match. The pain and edema were exacerbated after training. Upon physical examination, the patient had hallux valgus, no pain or medial callosity in the first metatarsal-phalangeal joint, pain between the first and second rays of the right foot at the level of the Lisfranc joint, which did not extend to the path of the extensor hallucis longus tendon, mild edema, no signs of joint instability, no neurovascular deficit, a positive Tinel's sign on local percussion, unchanged gait, a normal medial longitudinal arch and no ligamentous laxity (Figure 1). Radiographs showed no fracture or opening in the Lisfranc joint. A formation with limited bone density was present between the base of the first and second metatarsals, which was also observed on the radiograph of the contralateral foot, which was asymptomatic (Figure 2). A complementary evaluation by computed tomography (CT) was performed, which confirmed the presence of an ossicle between the first and second metatarsals in their dorsal aspect that was compatible with the pain point indicated by the patient (Figure 3). After the diagnosis of a symptomatic os intermetatarsium, initial conservative treatment was selected, consisting of immobilization without load for 2 weeks, analgesics, anti-inflammatory



**Figure 1.** Clinical aspect of the right foot. Front view (A) and oblique view (B) demonstrating valgus of the hallux and edema between the first and second rays at the level of the Lisfranc joint. **Source:** author's personal archive.



**Figure 2.** X-rays of the foot showing a small accessory bone formation between the base of the first and second metatarsals. **Source:** author's personal archive.



**Figure 3.** Computed tomography image of axial and coronal sections showing the accessory ossicle. **Source:** author's personal archive.

physiotherapy and refraining from physical activities. The patient returned to sports activities without complaint after 2 months.

## DISCUSSION

The os intermetatarsium is recognized as the rarest accessory ossicle of the foot, with variable incidence in the worldwide reports<sup>(1,2)</sup>. One report found an incidence of approximately 3.3%<sup>(6)</sup>. However, anatomical studies report a higher incidence than radiographic studies, likely due to the location of this formation and the difficulty of visualization by radiographs<sup>(1)</sup>. This formation may be unilateral but is generally found bilaterally between the first and second metatarsals and more rarely between the fourth and fifth metatarsals<sup>(4)</sup>.

A sesamoid between the first and second metatarsals is typically asymptomatic, and only a limited number of patients have described symptomatic cases<sup>(2)</sup>. The clinical features of pain in the back of the foot and/or paresthesia in the territory of the deep fibular nerve, when present, are usually triggered by local trauma or physical activities<sup>(7)</sup>. Symptoms of pain or compression of the bundle can be more easily triggered in patients with ankle instability or arched feet but can also be triggered in situations of plantar flexion of the foot with the first ray extended and by the use of tight shoes that cause local compressive effects<sup>(8)</sup>.

The authors who reported this pathology opted for conservative treatment as the initial management of symptomatic cases, including changing shoes, temporary withdrawal from physical activity and local corticosteroid injection<sup>(1)</sup>. Surgical treatment is indicated in the absence of response to conservative treatment, and several authors<sup>(1,2,7,8)</sup> have reported good results with regression of

symptoms after excision of the accessory bone. However, it is emphasized that understanding the anatomy is important to avoid damage to the deep fibular nerve and the dorsalis pedis artery<sup>(1)</sup>.

In the reported case, and in the cases described in the literature that involved athletes, an association was present between the onset of symptoms and physical activity<sup>(1,2,6,9)</sup>. Appearance of symptoms in young patients is a common factor in most reports in the literature, although cases of patients older than the current patient have also been reported<sup>(10)</sup>. The bilaterality of the os intermetatarsium in our patient was also consistent with that described in case series worldwide, although we did not identify other relatives of the current patient with the same condition or symptomatology. We opted for conservative treatment as an initial measure and guided the patient to change footwear and temporarily avoid physical activity, which has been shown to be an effective approach to control pain.

## CONCLUSION

The os intermetatarsium is the rarest accessory bone in the foot and is typically asymptomatic. It has been found to cause secondary hallux valgus. However, it is an important differential diagnosis to be considered when patients, especially in young athletes, present with pain in the back of the foot and compressive symptoms of the deep fibular nerve.

**Authors' contributions:** Each author contributed individually and significantly to the development of this article: LZPO \*(<http://orcid.org/0000-0001-5849-5841>) conceived and planned the activities that led to the study, interpreted the study results, wrote the article, participated in the review process, approved the final version; RSB \*(<http://orcid.org/0000-0002-2870-2261>) interpreted the study results, participated in the review process, approved the final version; RBM \*(<http://orcid.org/0000-0002-5306-2972>) conceived and planned the activities that led to the study, wrote the article, and participated in the review process; BCRC \*(<https://orcid.org/0000-0001-7075-472X>) Interpreted the study results, and participated in the review process. ORCID (Open Researcher and Contributor ID).

## REFERENCES

1. Chavali VH. Os intermetatarsium - A case report. *J Clin Orthop Trauma*. 2012;3(1): 54-57.
2. Rachha R, Gorva A. Os intermetatarsium revisited: a case report of rare variant and review of literature: case report. *J Foot Ankle Surg (Asia Pacific)*. 2015;2(1):47-50.
3. Gruber W. Über die beidenarten des überzahligen zwischen knöchelcheens am ruckendes metatarsumundüberdendurch ankyloseeinesdieser knöchelchenentstandeneneund eine knöchelchenentstandenene und eine exostone am os cunei form I und osmetatarsale II vortauchenden Fortsatz. *Arch Pathol Anat Physiol Klin Med*. 1877;71:440-52.
4. Henderson RS. Os intermetatarsium and a possible relationship to hallux valgus. *J Bone Joint Surg Br*. 1963;45-B:117-21.
5. Coughlin MJ, Jones CP. Hallux valgus: demographics, etiology, and radiographic assessment. *Foot Ankle Int*. 2007;28(7):759-77.
6. Burman MS, Lapidus PW. The functional disturbances caused by the inconstant bones sesaimods of the foot. *Arch Surg*. 1931;22:936-975.
7. Reichmister JP. The painful os intermetatarsium: a brief review and case reports. *Clin Orthop Related Res* 1980;153:201203.
8. Nakasa T, Fukuhara K, Adachi N, Ochi M. Painful Os intermetatarsium in athletes: report of four cases and review of the literature. *Arch Orthop Trauma Surg* 2007;127(4):261264.
9. Ruffing T, Muhm M, Winkler H. The painful os intermetatarsium. *Orthopade*. 2011;40(1):93-4.
10. Knackfuss I.G., Giordano V., Nogueira M., Giordano M. Compression of the medial branch of the deep peroneal nerve, relieved by excision of an os intermetatarsium. A case report. *Acta Orthop Belg*. 2003; 69:568-570.