

# Surgical treatment of moderate and severe hallux valgus: 30 cases undergoing surgery using the percutaneous Chevron technique

## Tratamento cirúrgico hálux valgo moderado grave: 30 casos operados pela técnica Chevron percutânea

Rafael Ferreira da Silva<sup>1</sup>, André Donato Baptista<sup>1</sup>

1. Associação Beneficente Nossa Senhora do Pari, São Paulo, SP, Brazil.

### ABSTRACT

**Objective:** To evaluate the radiographic parameter correction and clinical improvement of moderate and severe hallux valgus deformities treated by percutaneous Chevron osteotomy.

**Methods:** Twenty-six patients (30 feet) underwent surgery. The following were measured preoperatively and postoperatively: hallux metatarsophalangeal (MTP) angle, intermetatarsal angle between the 1st and 2nd metatarsals (IMA), distal metatarsal joint angle (DMJA) and pre- and postoperative AOFAS scores with a minimum of 6 months of follow-up.

**Results:** The mean patient age was 52.3 years. Preoperatively, the mean AOFAS score was 45.6, which rose to 90.3 after the procedure, showing a statistically significant improvement. The preoperative mean MTP, IMA and DMJA angles were 29.7°, 14.2° and 14.2°, respectively, and the postoperative values were 12.8°, 8.2° and 11.1°, respectively. The improvements in MTP and IMA angles were also statistically significant. There were no losses in angular parameters or worsening of AOFAS scores during follow-up.

**Conclusion:** The percutaneous Chevron surgical technique proved to be safe and effective for the correction of moderate and severe hallux valgus cases and achieved significant improvements in clinical and radiographic parameters and low rates of postoperative complications.

**Level of Evidence III; Retrospective Comparative Study.**

**Keywords:** Hallux valgus/surgery; Hallux valgus/radiography; Osteotomy/methods, Minimally invasive surgical procedures.

### RESUMO

**Objetivo:** Avaliar a correção dos parâmetros radiográficos e a melhora clínica da deformidade em hálux valgo moderada e grave, tratadas pela osteotomia de Chevron percutânea.

**Métodos:** Foram operados 26 pacientes (30 pés). Foram mensurados no pré-operatório e pós-operatório: ângulo metatarsofalângico do hálux (MTF), ângulo intermetatarsal entre o 1° e 2° metatarsos (AIM), ângulo da articulação metatarsal distal (AAMD) e os escores AOFAS pré e pós-operatórios com seguimento mínimo de 6 meses.

**Resultados:** A idade média dos pacientes foi de 52,3 anos. No pré-operatório, a média do escore AOFAS foi de 45,6, passando a 90,3 após o procedimento, com melhora estatisticamente significativa. As médias pré-operatórias dos ângulos MTF, AIM e AAMD foram respectivamente de 29,7°, 14,2° e 14,2° e as pós-operatórias foram 12,8°, 8,2° e 11,1°. A melhora nos ângulos MTF e AIM também apresentaram relevância estatística. Não houve qualquer perda nos parâmetros angulares ou piora nos escores AOFAS durante o seguimento.

**Conclusão:** A técnica cirúrgica de Chevron percutâneo se mostrou segura e eficaz para a correção dos casos de hálux valgo moderado e grave, com melhora significativa dos parâmetros clínicos e radiográficos e baixo índice de complicações pós-operatórias.

**Nível de Evidência III; Estudo Retrospectivo Comparativo.**

**Descritores:** Hálux valgus/cirurgia; Hálux valgus/radiografia; Osteotomia/métodos; Procedimentos cirúrgicos minimamente invasivos.

Work performed at the Associação Beneficente Nossa Senhora do Pari, São Paulo, SP, Brazil.

**Correspondence:** Rafael Ferreira da Silva. Rua Hannemann nº 234, Canindé. CEP: 03031-040 – São Paulo, SP, Brazil.

E-mail: [medicina\\_rafael@yahoo.com.br](mailto:medicina_rafael@yahoo.com.br)

**Conflicts of interest:** none. **Source of funding:** none.

**Date Received:** February 07, 2018. **Date Accepted:** March 06, 2018. **Online:** March 30, 2018.



**How to cite this article:** Silva RF, Baptista AD. Surgical treatment of moderate and severe hallux valgus: 30 cases undergoing surgery using the percutaneous Chevron technique *Sci J Foot Ankle*. 2018;12(1):61-7.

## INTRODUCTION

Hallux valgus is the most prevalent orthopedic deformity in the forefoot. It is estimated that 23% of adults between 23 and 65 years of age are carriers of the deformity; in the over 65 age range, the prevalence rises to 35%<sup>(1)</sup>. The disease is multifactorial, with heredity being the main associated factor, as approximately 68% of patients have a family history of hallux valgus. Pain and discomfort when wearing closed shoes are present in many cases, resulting in limitations to everyday activities and affecting quality of life<sup>(1-6)</sup>.

Surgical treatment is indicated in cases where pain and disability persist after conservative treatment<sup>(4)</sup>. Currently, over 150 surgical techniques are described for hallux valgus correction, and there is no consensus regarding the best treatment<sup>(7-11)</sup>. The deformity's severity is one of the main factors that determines the choice of surgical technique<sup>(12-14)</sup>.

The Chevron-type distal metatarsal osteotomy, first described in 1962, is a widely accepted technique and is used in the treatment of mild to moderate deformities. It offers satisfactory results in adults of all ages and promotes pain relief, restoration of function and durable correction of the deformity<sup>(10)</sup>. However, publications regarding its effectiveness in the treatment of cases with severe deformities are still scarce in the literature.

Although there are reports that distal Chevron osteotomy combined with realignment of the soft tissue of the metatarsophalangeal joint allows the procedure to be used in severe cases<sup>(15-17)</sup>, there are concerns regarding the loss of stability and increased risk of vascular necrosis of the metatarsal head when its translation exceeds 30% of its contact area<sup>(13,16-17)</sup>. With the advent of minimally invasive techniques for the correction of hallux valgus, Vernois pioneered the percutaneous Chevron osteotomy<sup>(18)</sup>. As it causes less harm to soft tissue and vascularization of the metatarsal head, this technique allows lateral translations of up to 100% of the osteotomy contact area, only maintaining contact of the medial cortical region of the head with the lateral cortical region of the metadiaphyseal region. Moreover, fixation with cortical screws provides sufficient stability to the corrections, in theory allowing this method to be used in cases of severe deformity as well<sup>(9,15,18)</sup>.

In this regard, the objective of this study was to evaluate the radiographic parameter corrections, clinical improvements and potential complications in the first 30 cases of moderate and severe hallux valgus undergoing surgery in our institution using the percutaneous Chevron technique.

## METHODS

The study was approved by the Research Ethics Committee and was registered in the Brazil Platform under the CAAE number 70904817.0.0000.5455.

Patients undergoing surgery using the modified percutaneous Chevron technique were selected between October 2016 and June 2017. Exclusion factors for the studied population included peripheral sensory neuropathy, radiographic osteoarthritis with pain and limited movement in the metatarsophalangeal joint of the hallux and severe vascular disorders. The AOFAS (*American Orthopedic Foot and Ankle Society*) score<sup>(16)</sup> for hallux valgus evaluation was applied pre-operatively, after a minimum follow-up period of 6 months and after 1 year of follow-up in some cases. In the AP radiographs with load on the foot, the following radiographic parameters were measured: hallux metatarsophalangeal angle (MTP), distal metatarsal joint angle (DMJA) and intermetatarsal angle (IMA) between the first and second metatarsals. The appropriate instrumentation for minimally invasive foot surgery was used in the surgical procedure: the exostectomies were performed with 12 x 3.1-millimeter (mm) Wedge-type cutters, and the Chevron osteotomies were performed with 20 x 2mm Shannon-type cutters. When necessary, Akin osteotomies were performed with 12 x 2mm Shannon-type cutters. Fixing of the osteotomies was performed with cannulated 3.5-mm threaded screws or with 4.5-mm headless screws with double compression.

### Surgical technique

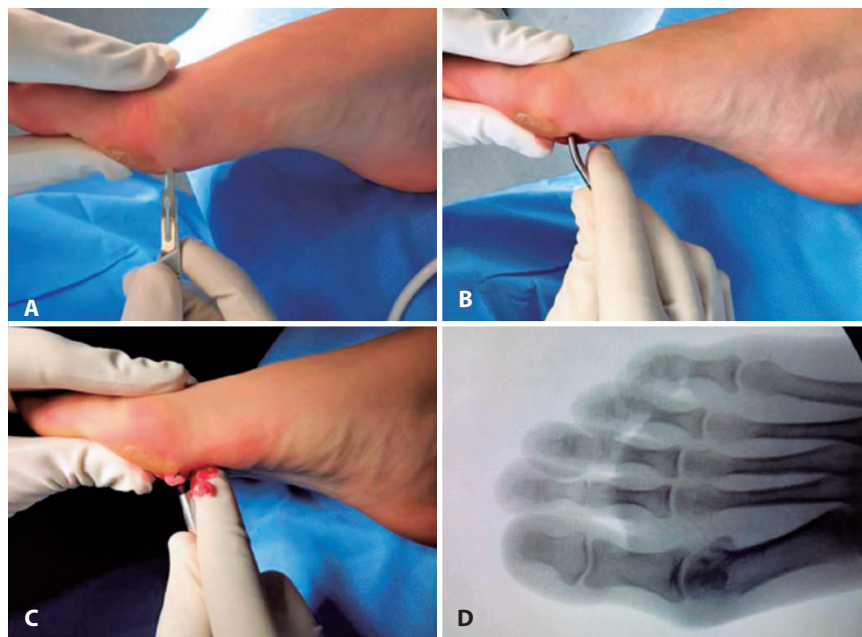
The procedures were performed under spinal anesthesia. Patients were placed in the supine position, without the use of a tourniquet. The first step in the procedure was to perform a medial exostectomy of the first metatarsal head by means of a punctiform incision located just above and proximal to the medial sesamoid bone (Figure 1).

Next, the cannulated screw guide thread was introduced under radioscopic control towards the position planned for the metatarsal head after its translation.

The third step was to perform a new punctiform incision on the medial side of the forefoot, on the metatarsal neck region, in a central position in relation to its thickness on the sagittal plane (Figure 2). The Chevron osteotomy was performed via this incision with the aid of small levers introduced into the medullary canal of the metatarsal bone. Its head was translated laterally to the upper limit for correction of the intermetatarsal angle (Figure 3).

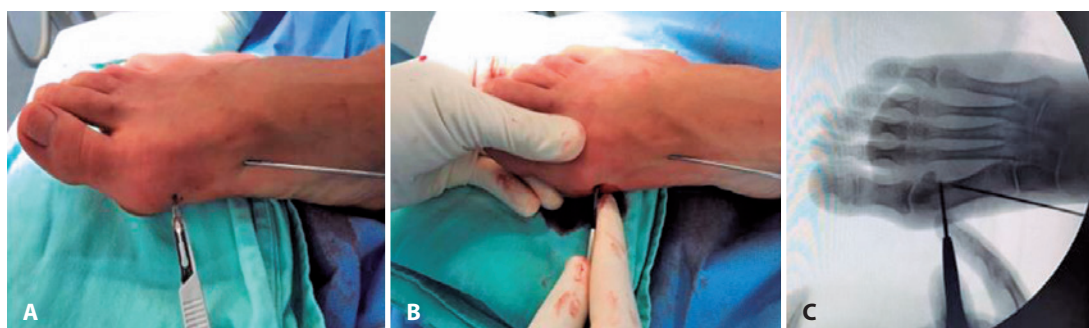
Percutaneous fixing of the osteotomy was then performed with an 01-cannulated screw, attempting to pass it through the medial and lateral corticals of the proximal fragment to maintain the stability of the correction (Figure 4). At this point, the correction obtained was clinically evaluated and, if necessary, Akin-type percutaneous phalangeal osteotomies were performed, without fixing (Figure 4).

In a different manner to that described in the original technique, in the last step of surgical correction, it was decided to perform percutaneous tenotomy of the hallux adductor and lateral capsulotomy of the metatarsophal-



**Figure 1.** Surgical technique: A. Determination of the exostectomy portal. B. Detachment of the joint capsule. C. Percutaneous cutting with a Wedge cutter. D. Radioscopic control of the exostectomy.

**Source:** Author's personal archive.



**Figure 2.** Surgical technique: A. Determination of Chevron osteotomy. B. Positioning of the surgical gesture of the Chevron osteotomy. C. Radioscopic view of the position of the Shannon cutter and the cannulated screw guide thread.

**Source:** Author's personal archive.

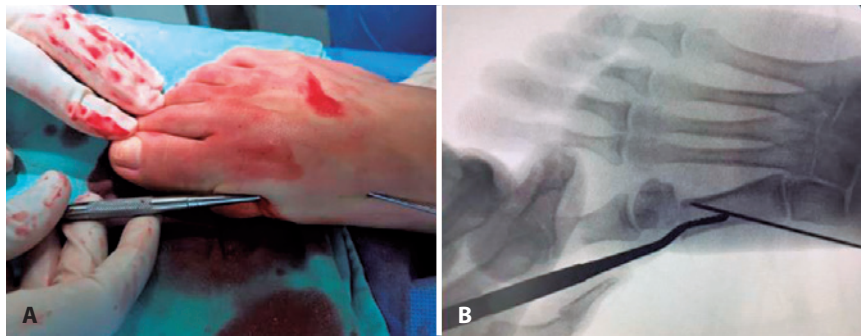
lungeal area in cases of severe deformity with greater retraction of the lateral soft tissue and where difficulty was encountered in the passive reduction of the hallux valgus deformity.

The punctiform incisions were closed with mononylon 4.0, and conventional dressing was applied with additional taping on the hallux where the Akin osteotomy was performed. In the postoperative period, the patients were allowed to walk with immediate full load protected by hard-soled orthopedic sandals; this protection was maintained for six weeks. The taping of the hallux, when performed, was discontinued three weeks after surgery. After the initial six

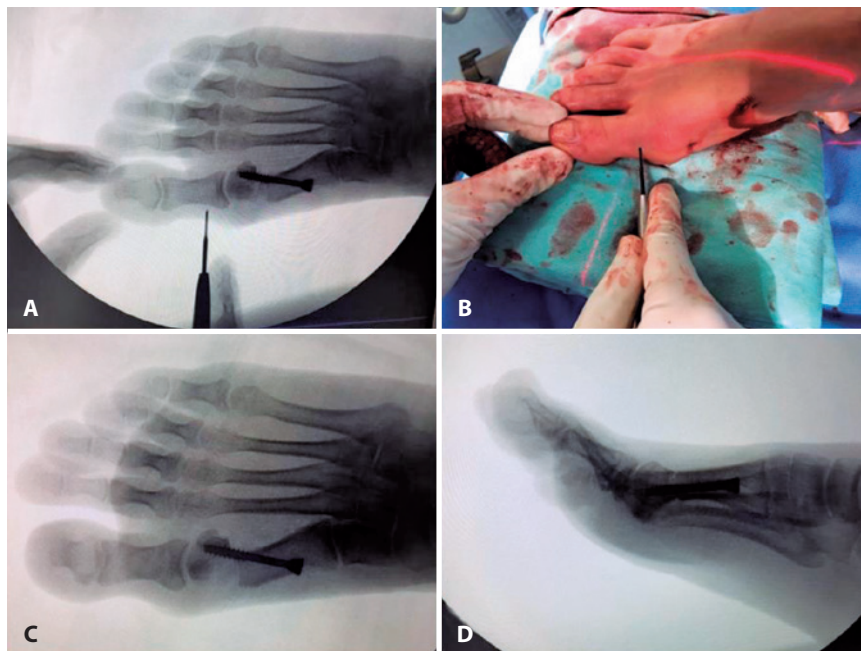
weeks, patients were released from any special protection and were instructed to return to the use of conventional footwear.

## RESULTS

Twenty-six patients (30 feet) underwent surgery using the percutaneous Chevron technique. The patients' mean age was 52.3 years ( $\pm 10.5$ ) (ranging from 26 to 69 years old), and 92% were women. All patients completed the AOFAS questionnaire preoperatively and six months after surgery; 13 of them (45%) also completed the questionnaire 12 months after surgery (Table 1).



**Figure 3.** Surgical Technique. A. Lateral translation with lever. B. Positioning and control of the translation.  
**Source:** Author's personal archive.



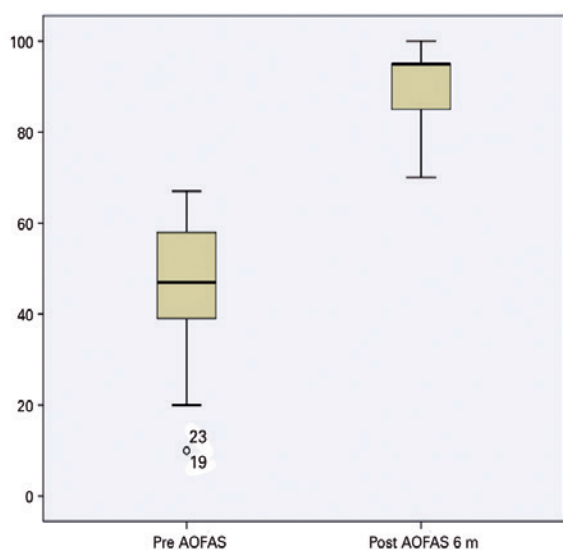
**Figure 4.** Surgical Technique. A. Determination of the Akin osteotomy site and view of the cannulated screw setting. B. Position of the surgical gesture for the Akin osteotomy. C. (AP) and D. (Profile). Final radioscopic view.  
**Source:** Author's personal archive.



**Table 1.** AOFAS score results

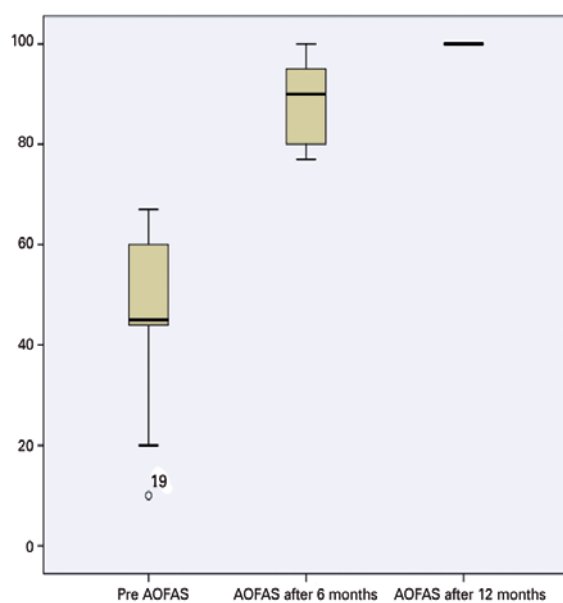
		Mean (SD)	p value
AOFAS (N=30)	Preoperative	45.6 (±15.3)	0.002*
	After 6 months	90.3 (±8.6)	
AOFAS (N=13)	Preoperative	45.5 (±18.4)	0.004*
	After 6 months	88.6 (±8.1)	0.010
	After 12 months	99.9 (±0.006)	

AOFAS: American Orthopaedic Foot and Ankle Society; N: Number of patients (feet); SD: Standard deviation. \* p < 0.05 (95% confidence interval); statistically significant difference.



**Figure 5.** AOFAS score results (30 feet).

**Source:** Prepared by the author based on the research results.



**Figure 6.** AOFAS score results (13 feet).

**Source:** Prepared by the author based on the research results.

The mean AOFAS scores were 45.6 (±15.3) preoperatively and 90.3 (±8.6) six months after surgery, which showed statistically significant improvements in the evaluated criteria (pain, functional aspects and alignment) (p=0.002) (Figure 5).

When considering patients who answered the questionnaire after 12 months, the mean score was 45.5 (±18.4) preoperatively, 88.6 (±8.1) after six months and 99.0 (±0.006) after 12 months. These data showed a statistically significant difference between the preoperative period and six months after surgery (p=0.004) (Figure 6).

Despite the fact that there were even higher AOFAS scores in all cases evaluated after 12 months of follow-up when compared to the scores measured six months after surgery, the sample size prevented statistical significance from being established.

Regarding radiographic analysis, the hallux metatarsophalangeal angle, the distal metatarsal joint angle and the intermetatarsal angle between the first and second metatarsals were measured on all patients (30 feet) preoperatively and after a minimum follow-up of six months. Only 12 cases completed 12 months of follow-up (Table 2).

In the sample as a whole, there were statistically significant differences in the metatarsophalangeal and intermetatarsal angles between the preoperative period and after six months of follow-up (p=0.0003 and 0.0004, respectively). In the group of 12 patients who completed 12 months of follow-up, there were no statistically significant changes in the angular parameters, although a tendency toward improvement was observed in the mean intermetatarsal angle values.

The following complications were observed: one case of asymptomatic proximal migration of the fixing screw and one case of synthetic material removal due to pain on palpation on the screw head. There were no cases of infection, pseudarthrosis or osteonecrosis, and there were no surgical wound complications.

## DISCUSSION

The surgical treatment of hallux valgus deformities is sometimes challenging. Serious deformities pose even greater challenges. The obstacles to be overcome to achieve satisfactory correction include marked metatarsus varus, articular subluxation, excessive pronation of the hallux and intense retraction of the lateral capsuloligamentous structures<sup>(6,12,14,18-20)</sup>. The literature shows that for most cases of severe hallux valgus deformities, the most commonly used surgical treatments are proximal or diaphyseal metatarsal

**Table 2.** Radiographic parameter measurement results (M/SD, in degrees)

Radiographic angles (n=30)	Pre-operative	After 6 months	After 12 months	p value	
Metatarsal-phalangeal	29.7 (±11)	12.8 (±5.8)	NA	0.0003*	
Distal metatarsal	14.2 (±5.7)	11.1 (±8.0)	NA	0.073	
Intermetatarsal	14.2 (±3.8)	8.2 (±2.4)	NA	0.0004*	
Radiographic angles (N=12)	Preoperative	After 6 months	After 12 months	p value	
				Pré-6	6-12
Metatarsal-phalangeal	31.2 (±9.7)	12.3 (±5.3)	12.4 (±4.9)	0.006*	1.00
Distal metatarsal	12.8 (±5.3)	8.7 (±4.8)	8.4 (±5.1)	0.08	0.08
Intermetatarsal	13.4 (±3.4)	8.2 (±2.5)	6.4 (±1.7)	0.015	0.20

N: Number of patients (feet); M: Mean; SD: Standard deviation; NA: Not evaluated. \* p < 0.05 (95% confidence interval); statistically significant difference.

osteotomies, Lapidus arthrodesis and metatarsophalangeal hallux arthrodesis<sup>(6)</sup>. In most studies, distal metatarsal osteotomies are reserved for mild to moderate cases, as they are theoretically less able to correct varus of the first metatarsal<sup>(6,13)</sup>. However, in 2008, Murawski reported good results and a low complication rate in a series of 37 cases undergoing surgery using modified distal Chevron osteotomy with lateral translations of the capital fragment of up to 90%<sup>(5,21)</sup>. Other recent studies have demonstrated satisfactory results with the use of distal Chevron osteotomy associated with lateral capsuloligamentous release to correct severe cases<sup>(5,14)</sup>. Against this backdrop, and with the advent of minimally invasive techniques, Vernois published a study of completely percutaneous Chevron osteotomy for severe cases of hallux valgus and reported satisfactory results with a low complication rate<sup>(18)</sup>.

Thus, the present study aimed to evaluate the efficacy and possible complications in the first 30 cases undergoing surgery by the authors using the percutaneous Chevron technique. The results obtained for the 30 feet operated upon using this technique showed statistically significant improvements in hallux metatarsophalangeal and intermetatarsal angles and in the clinical and functional parameters evaluated by the AOFAS score for hallux valgus<sup>(22)</sup>. The number of complications was low, and none compromised the correction obtained during the postoperative follow-up period. When evaluating the 12 cases who completed a one-year follow-up period, a tendency toward even greater improvement in AOFAS scores can be observed, with no loss of the obtained angular parameters, although the sample was too small to demonstrate statistical significance. In relation to the distal metatarsal joint angle, there was a question about the possibility of its correction using this technique, as there is no medial wedge removal as performed in biplanar Chevron osteotomy<sup>(23)</sup>. Although

there were no statistically significant changes, correction is feasible when using the percutaneous Chevron technique without the need of biplanar osteotomies, as seen in the correction using the open technique<sup>(23)</sup>. This type of correction is possible because with the percutaneous technique<sup>(3,15,18)</sup>, the capital fragment is completely movable on the axial plane after osteotomy, allowing its proper positioning, under radioscopic control, to correct this angle.

The greatest difficulties encountered when using the technique in the initial learning phase were optimal positioning of the metatarsal head after performing its lateral translation and correct introduction of the fixing screws. In cases where it is difficult to position the metatarsal head, a 2.5-mm smooth Kirschner thread can be used, introduced into the head from the distal to proximal, which acts as a “joystick” and assists in positioning. The introduction of a guide thread prior to osteotomy is suggested to facilitate the correct positioning of the cannulated screws. The thread is drawn toward the position to be occupied by the metatarsal head after its translation. Its introduction should be guided by radioscopy, respecting the middle diaphyseal path (in profile radiograph), and should cross the medial and lateral corticals to provide the desired stability and to minimize the risk of correction loss and breakage or migration of the synthetic material.

The present study may be criticized due to the small number of cases studied, the absence of a control group, the lack of objective angular criteria for performing the Akin osteotomy, the short follow-up period and the non-stratification of the results into feet that were simultaneously submitted, or not, to surgical correction of other associated deformities, such as claw toes, metatarsalgia and bunionettes.

Factors that limit reproducibility of the technique include specific training and the need for a motor and suitable instruments for performing minimally invasive foot surgery<sup>(15)</sup>.

The current literature is scarce regarding publications on the subject<sup>(8)</sup>; until now, with the exception of Vernois' study<sup>(18)</sup>, there has been no publication on the use of the technique for the correction of severe hallux valgus cases, emphasizing the value of this study, in its pioneering evaluation of the use of percutaneous Chevron osteotomy for the correction of moderate and severe cases in our environment. These findings should encourage studies with larger sample sizes and longer follow-up periods to validate the results.

## CONCLUSION

All patients included in this study demonstrated satisfactory clinical and radiographic improvements after surgical correction of deformities in moderate and severe hallux valgus. The percutaneous Chevron technique proved effective for correcting moderate to severe hallux valgus, with a low incidence of postoperative complications. Further studies with larger sample sizes and longer follow-up periods should be conducted to confirm the results.

**Authors' contribution:** Each author contributed individually and significantly to the development of this article: RFS (<https://orcid.org/0000-0003-4973-1253>)\* conceived and planned the activities that led to the study and wrote the article, participated in the review process and interpreted study results; ADB (<https://orcid.org/0000-0002-5991-1701>)\* conceived and planned the activities that led to the study and wrote the article, participated in the review process and approved the final version. \*ORCID (Open Researcher and Contributor ID).

## REFERENCES

- van Groningen B, van der Steen MC, Reijman M, Bos J, Hendriks JG. Outcomes in chevron osteotomy for Hallux Valgus in a large cohort. *Foot (Edinb)*. 2016;29:18-24.
- Nix S, Smith M, Vicenzino B. Prevalence of hallux valgus in the general population: a systematic review and meta-analysis. *J Foot Ankle Res*. 2010;3:21.
- Maffulli N, Longo UG, Marinozzi A, Denaro V. Hallux valgus: effectiveness and safety of minimally invasive surgery. A systematic review. *Br Med Bull*. 2011;97:149-67.
- Lee KM, Ahn S, Chung CY, Sung KH, Park MS. Reliability and relationship of radiographic measurements in hallux valgus. *Clin Orthop Relat Res*. 2012;470(9):2613-21.
- Palmanovich E, Myerson MS. Correction of moderate and severe hallux valgus deformity with a distal metatarsal osteotomy using an intramedullary plate. *Foot Ankle Clin*. 2014 Jun;19(2):191-201.
- Cassinelli SJ, Herman R, Harris TG. Distal Metatarsal Osteotomy for Moderate to Severe Hallux Valgus. *Foot Ankle Int*. 2016;37(10):1137-45.
- Silva João LV, Anzuatégui Pedro R. Técnica minimamente invasiva para tratamento cirúrgico do hálux valgo: avaliação clínica e radiográfica preliminar. *Rev ABTPé*. 2009; 3(1): 29-35.
- Cohen JC, Richardson G, Fernandes Rodrigo MP. Tratamento cirúrgico do hálux valgo moderado à grave por meio da osteotomia distal tipo chevron associado à liberação distal de partes moles. *Rev ABTPé*. 2010; 4(2): 97-106.
- Smith SE, Landorf KB, Butterworth PA, Menz HB. Scarf versus chevron osteotomy for the correction of 1-2 intermetatarsal angle in hallux valgus: a systematic review and meta-analysis. *J Foot Ankle Surg*. 2012;51(4):437-44.
- Brogan K, Voller T, Gee C, Borbely T, Palmer S. Third-generation minimally invasive correction of hallux valgus: technique and early outcomes. *Int Orthop*. 2014;38(10):2115-21.
- Jowett CRJ, Bedi HS. Preliminary Results and Learning Curve of the Minimally Invasive Chevron Akin Operation for Hallux Valgus. *J Foot Ankle Surg*. 2017;56(3):445-52.
- Roukis TS. Percutaneous and minimum incision metatarsal osteotomies: a systematic review. *J Foot Ankle Surg*. 2009;48(3):380-7.
- Stienstra JJ, Lee JA, Nakadate DT. Large displacement distal chevron osteotomy for the correction of hallux valgus deformity. *J Foot Ankle Surg*. 2002;41(4):213-20.
- Kim HN, Park YJ, Kim GL, Park YW. Distal chevron osteotomy with lateral soft tissue release for moderate to severe hallux valgus decided using intraoperative varus stress radiographs. *J Foot Ankle Surg*. 2015;2(3):303-10.
- Redfern D, Perera AM. Minimally invasive osteotomies. *Foot Ankle Clin*. 2014;19(2):181-9.
- Radwan YA, Mansour AM. Percutaneous distal metatarsal osteotomy versus distal chevron osteotomy for correction of mild-to-moderate hallux valgus deformity. *Arch Orthop Trauma Surg*. 2012;132(11):1539-46.
- Robinson AH, Limbers JP. Modern concepts in the treatment of hallux valgus. *J Bone Joint Surg Br*. 2005;87(8):1038-45.
- Vernois J, Redfern DJ. Percutaneous Surgery for Severe Hallux Valgus. *Foot Ankle Clin*. 2016;21(3):479-93.
- D'Arcangelo PR, Landorf KB, Munteanu SE, Zammit GV, Menz HB. Radiographic correlates of hallux valgus severity in older people. *J Foot Ankle Res*. 2010;3:20.
- Schneider W, Aigner N, Pinggera O, Knahr K. Chevron osteotomy in hallux valgus. Ten-year results of 112 cases. *J Bone Joint Surg Br*. 2004;86(7):1016-20.
- Murawski DE, Beskin JL. Increased Displacement Maximizes the Utility of the Distal Chevron Osteotomy for Hallux Valgus Deformity. *Foot Ankle Int*. 2008;29(2):155-63.
- Lara LCR, Montesi Neto DJC, Guerra RR, Marques RFS, Bicudo LR. Comportamento da dor no pós-operatório do hálux valgo utilizando técnicas convencionais, minimamente invasivas e percutâneas. *Rev ABTPé*. 2011;5(2):81-6.
- Nery C, Barraco R, Réssio C. Biplanar Chevron Osteotomy. *Foot Ankle Int*. 2002;23(9):792-798.